

# Evolutieve goed afgelijnde massa's

Mireille Van Goethem  
Lieve Hufkens

dr. I. Verslegers - A. Van Hoyweghen  
Prof. dr. P. Parizel (head of department)



# GOED AFGELIJNDE MASSA



# MASSA

## DEFINITIE :

Een samenhangende hoeveelheid weefsel van onbepaalde vorm.

Een opeenhoping van weefsel



# WANNEER SPREKEN WE OVER MASSA?

- MASSA

- Volume
- 3d
- Convexe rand
- Uniforme dichtheid

- BORSTWEEFSEL

- Vlak
- Concave rand
- Niet uniforme dichtheid



# MASSA

- Goed afgelijnd :
  - Scherpe randen >75%
  - Halo mogelijk
  - Rond of ovaal
- Niet goed afgelijnd :
  - Niet voldoen aan de bovenstaande criteria

- Spiculair



# MASSA

- Type massa
  - Goed afgelijnd
  - Niet goed afgelijnd
  - Spiculair
- P.P.V. voor maligniteit
  - < 2%
  - 35 - 50 %
  - 90 %

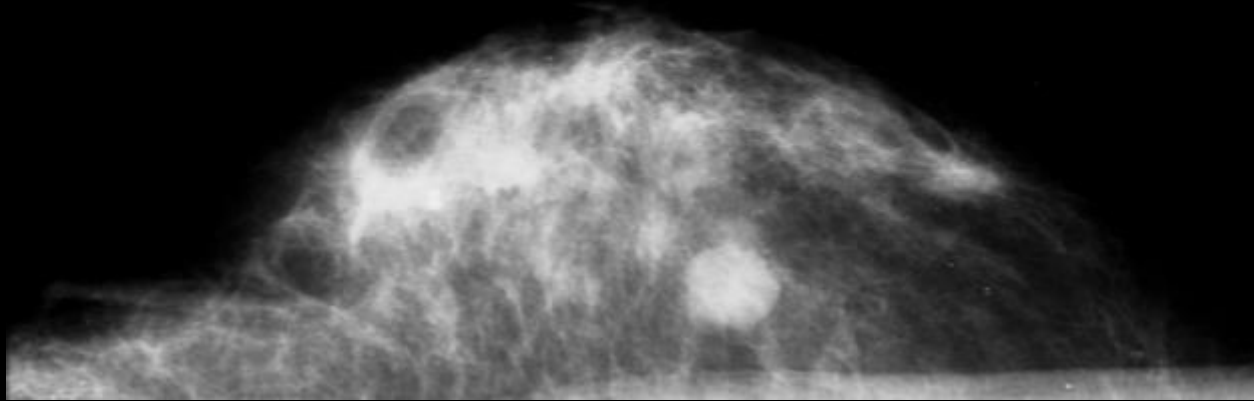
Multipele massa's minder waarschijnlijk  
maligne



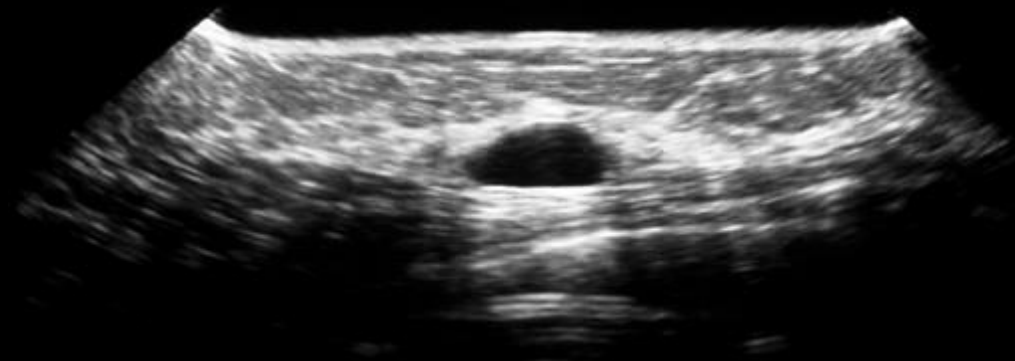# Goed afgelijnde massa's

- PPV maligne < 2%
  - Cyste
  - Lymfeklier
  - Fibroadenoma
  - Sebumcyste
  - Haematoma
  - Papilloma
  - Hamartoma

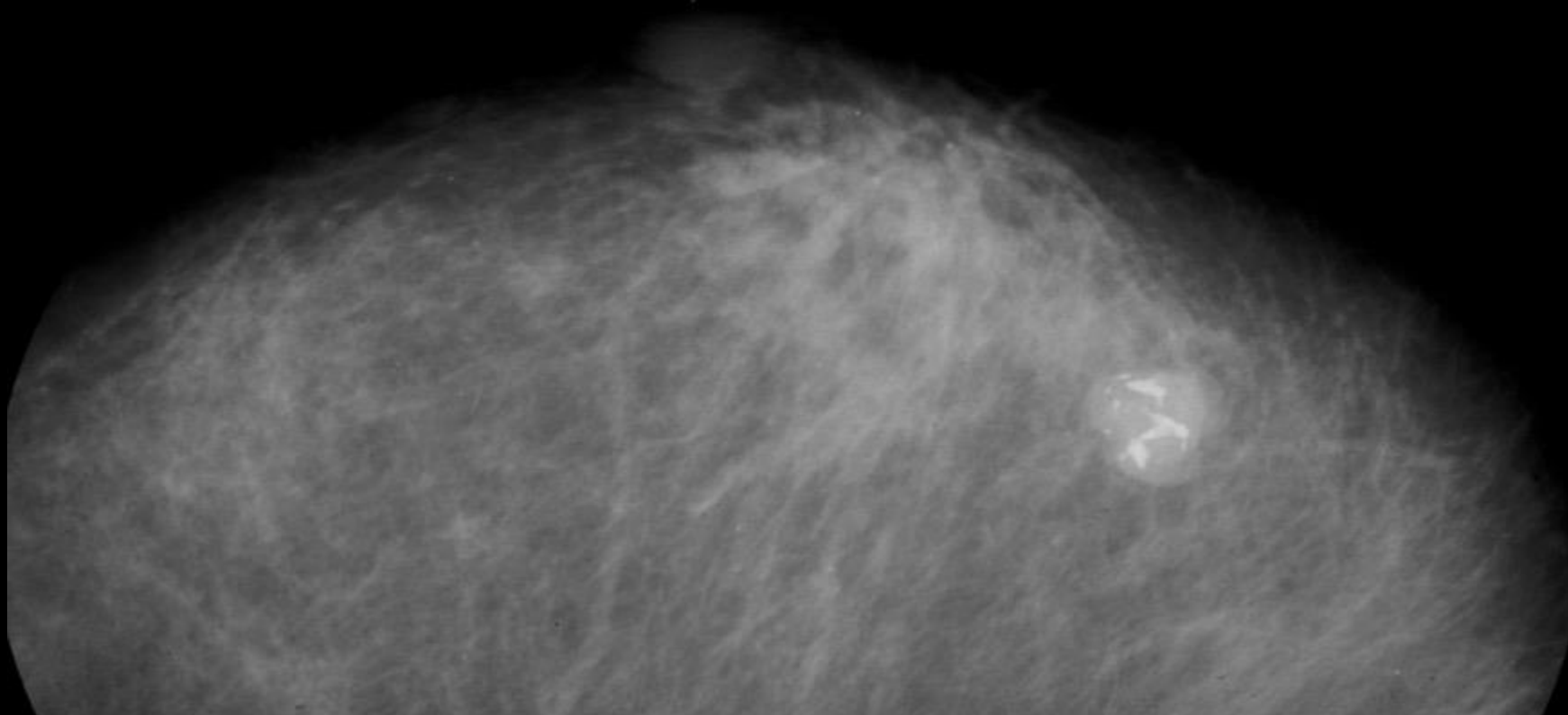




cyste







fibroadenoom

# BENIGNE MASSA'S

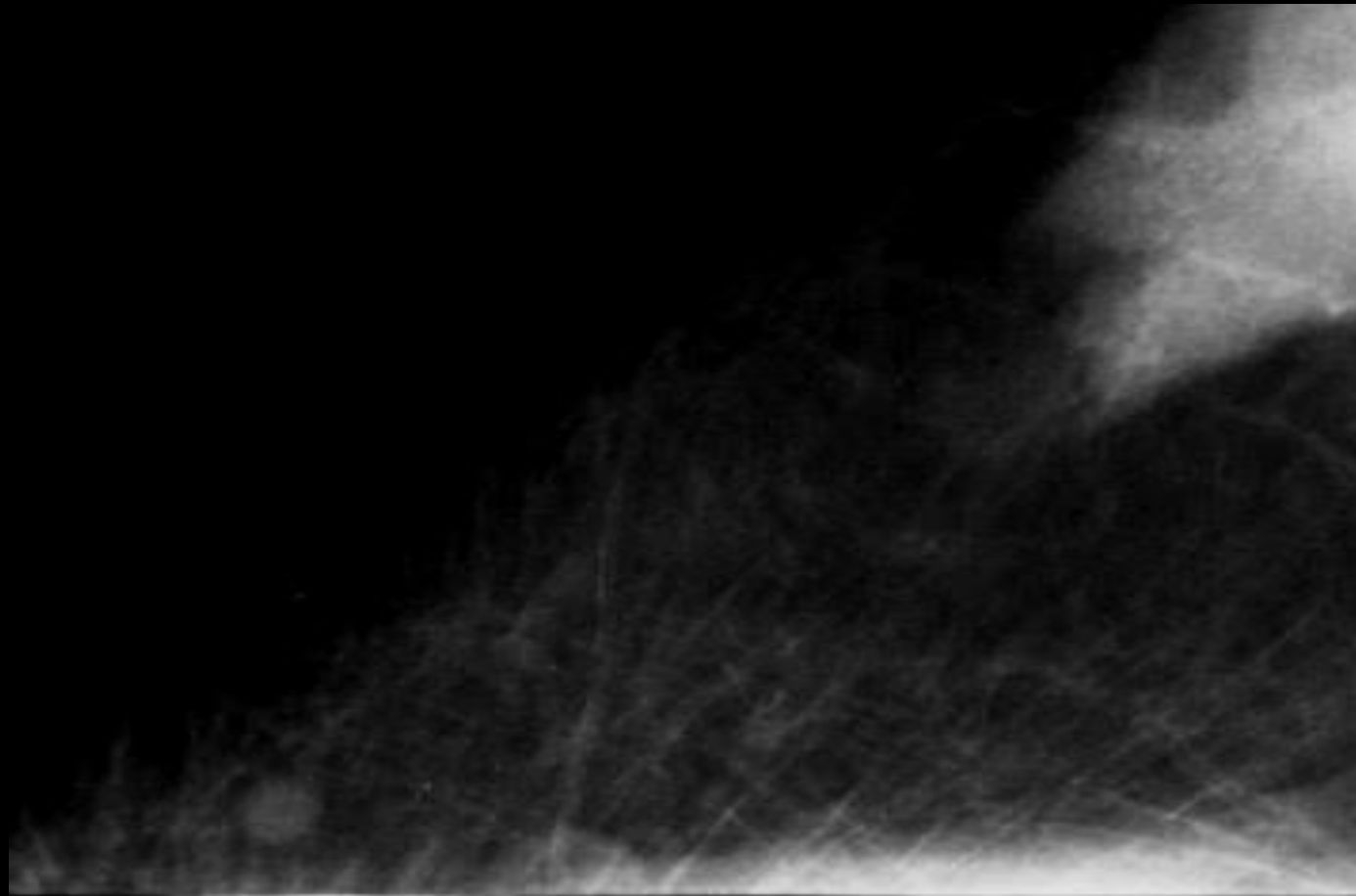
- Criteria van benigniteit
  - Bevat vet
  - Huidletsel
  - Fibroadenoma met 'pop-corn' verkalkingen
  - Intramammaire lymfeklier



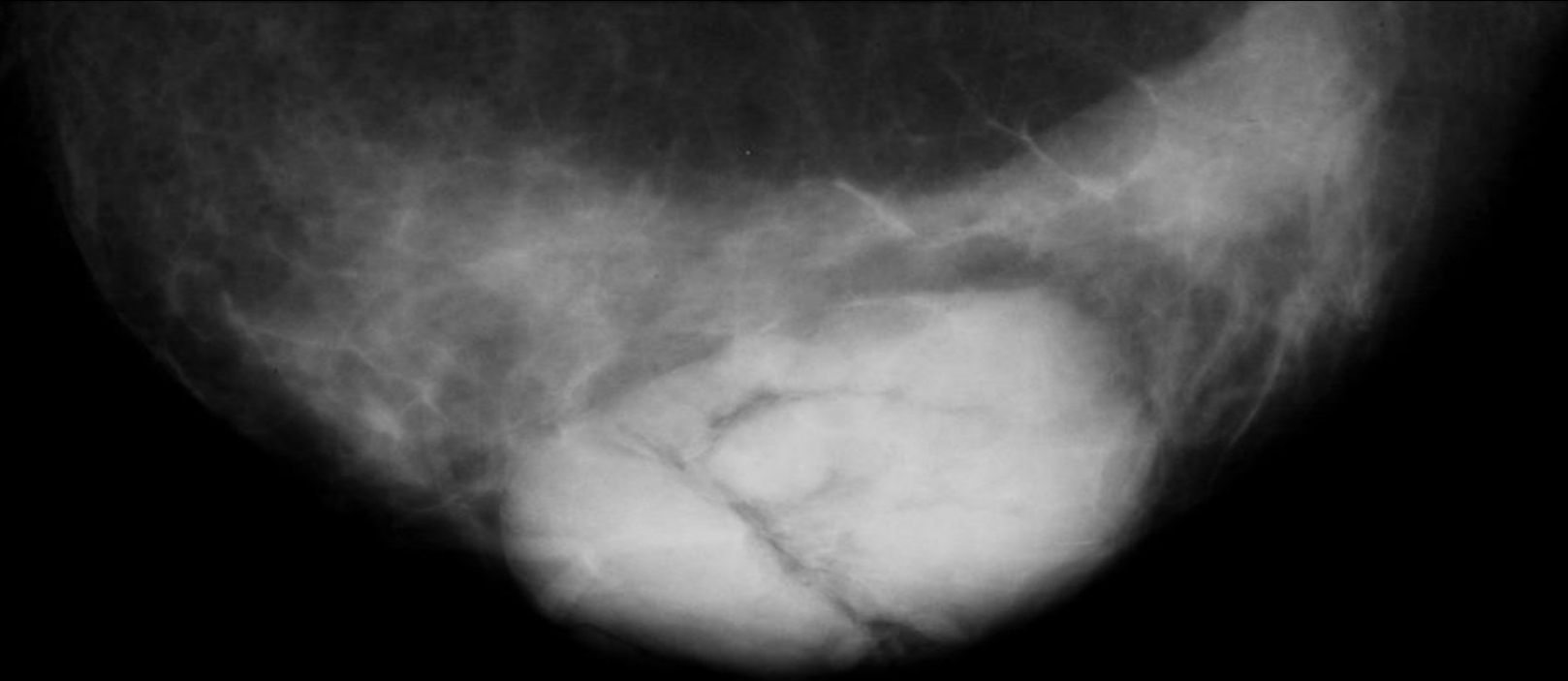
# VETHOUDENDE MASSA'S

- lipoma
- hamartoma
- lymfeklier
- vetnecrose
- galactocoele
- oliecyste
- vetlobule





lymfekliertje



hamartoom

# GOED AFGELIJNDE MASSA - MALIGNE

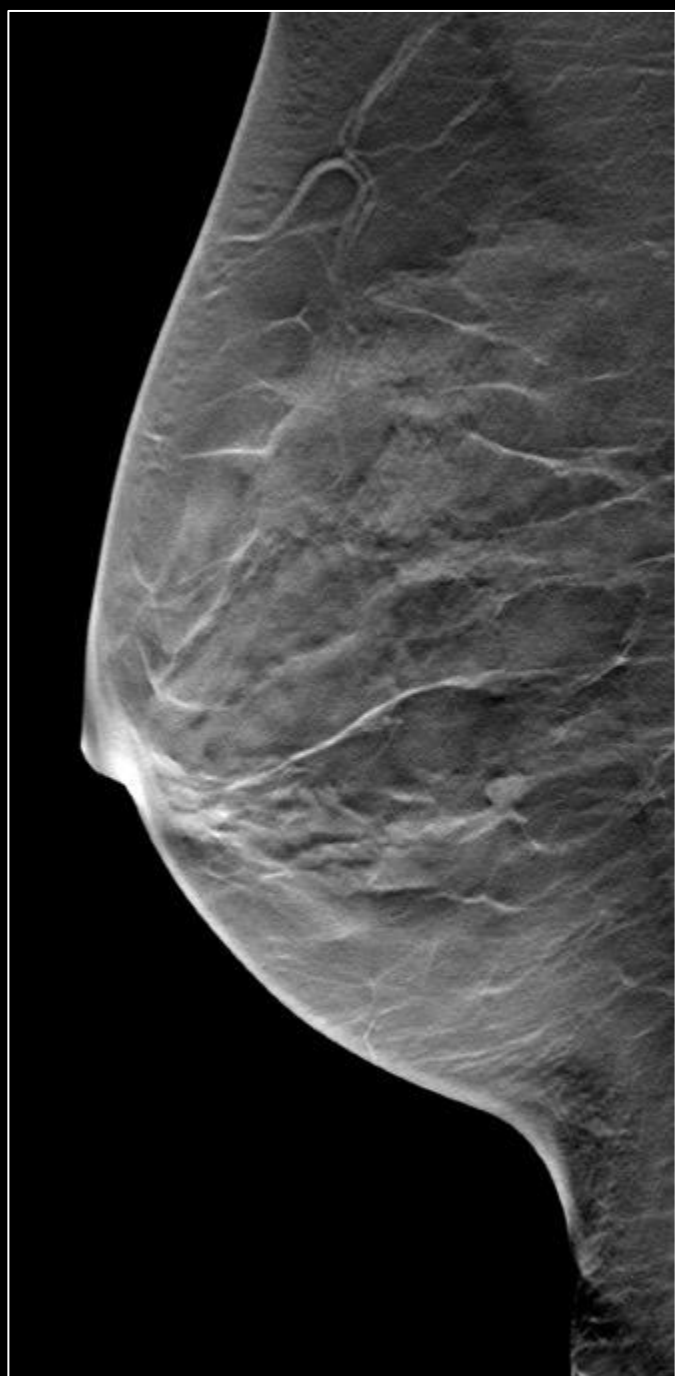
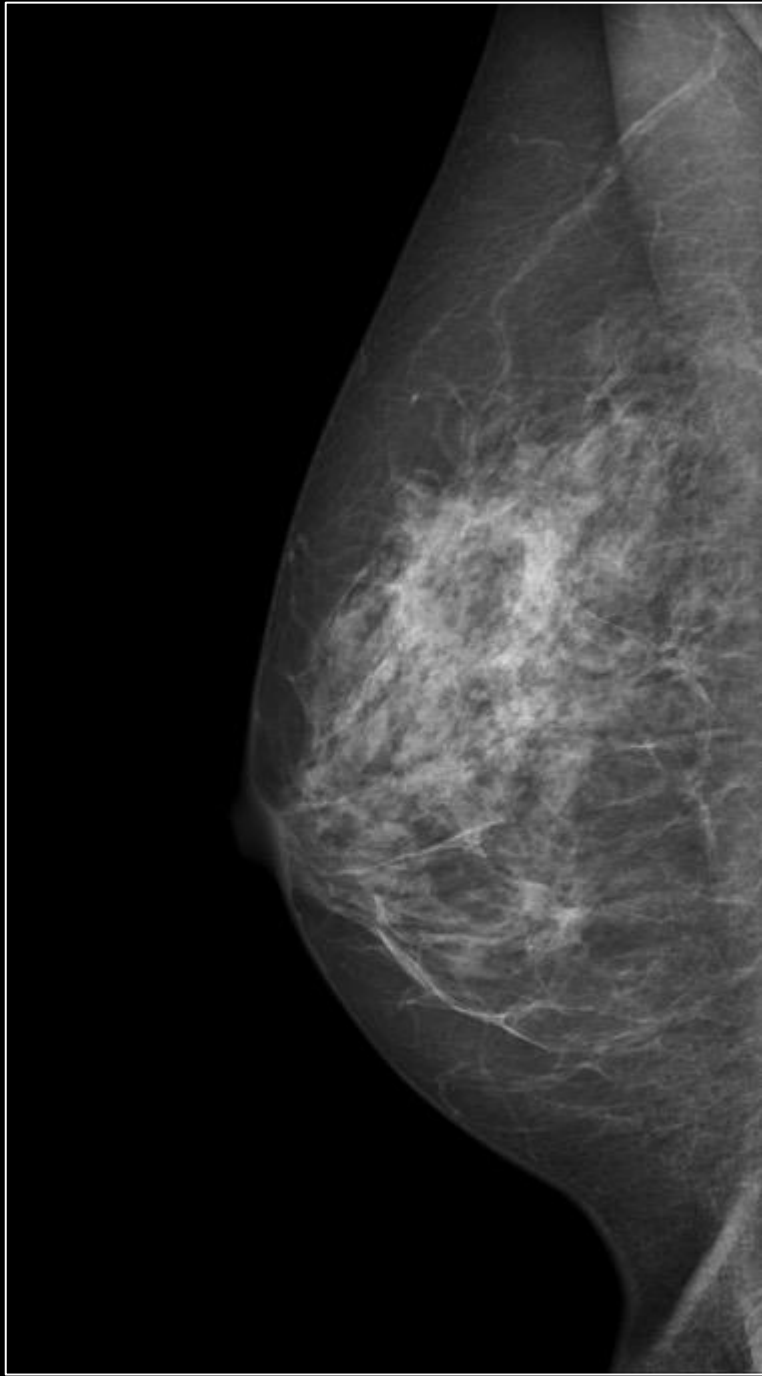
- Mucineus carcinoma
- Medullair carcinoma
- Papillair D.C.I.S.
- Invasief ductaal carcinoom (high grade)
- Metastases (dikwijls multiepel)
- Metastatische lymfeklier



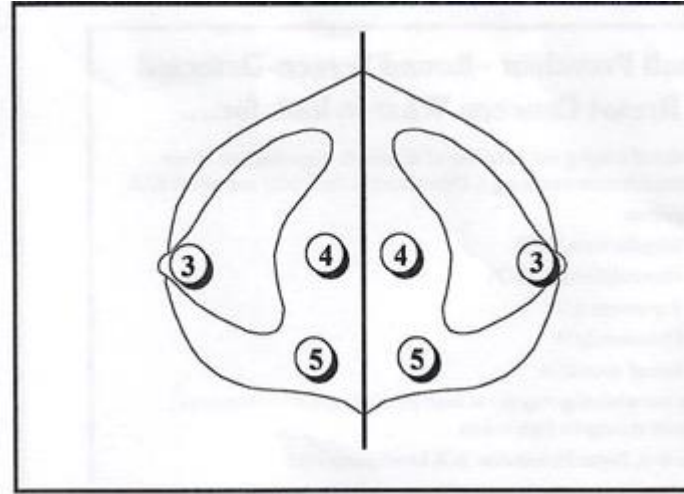
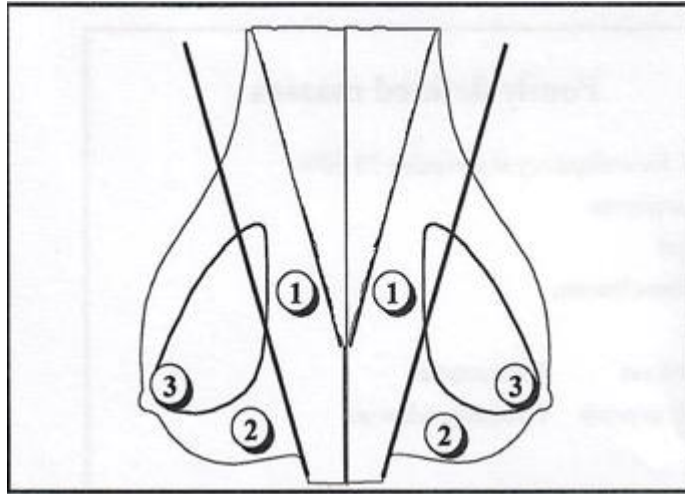
# RECALL

- Als:
  - Niet zeker (75%) goed aflijnbaar
  - Nieuwe massa
  - Goed afgelijnd maar volumetoename
  - Gelokaliseerd buiten het glandulaire weefsel









# RECALL ?

Slechts 4 % van de screen-detected kankers zijn scherp afgelijnde massa's.

- 68 % waren dense massa's
- 11 % halo-teken
- 29 % slechts op 1 opname (meestal niet CC)
- 75 % waren nieuw en 25 % toonden volumetoename



# KLEINE RONDE TUMOREN

Waarop letten?

- Onregelmatige aflijning
- Microverkalkingen
- Asymmetrie
- Distorsie

Meerderheid van de kleine ronde tumoren zijn niet goed afgelijnd !

Sian et al, R.C.R.Breast Group 2011



# ONSCHERP AFGELIJNDE MASSA

PPV voor maligne bij screening 35-50%

- Carcinoma
- Cyste
- Fibroadenoma
  
- Abces
- Vetnecrose
- Haematoom
- Sclerosing adenosis



## Recall behalve

- Indien gekend en onveranderd in vorige rondes
- Indien benigne biopsie

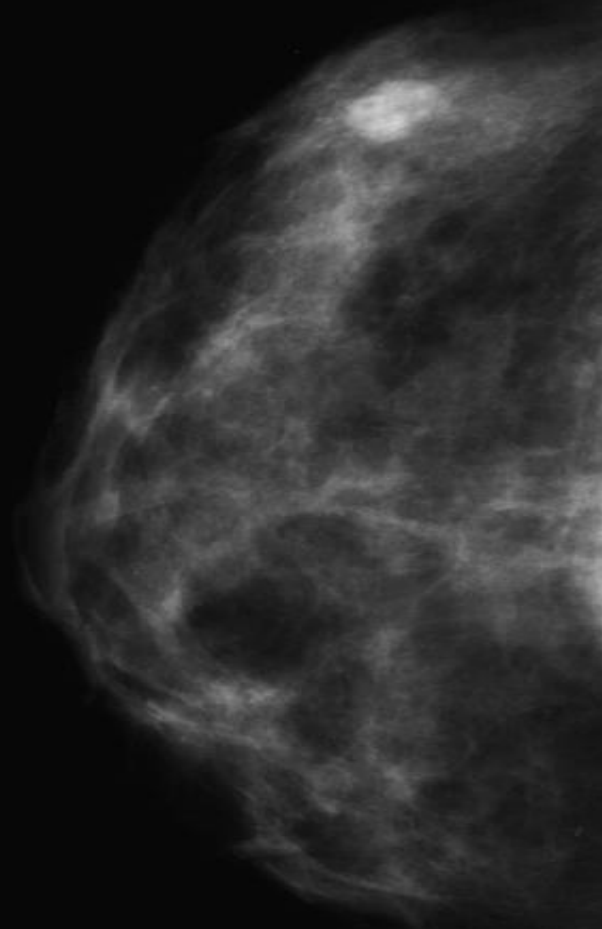
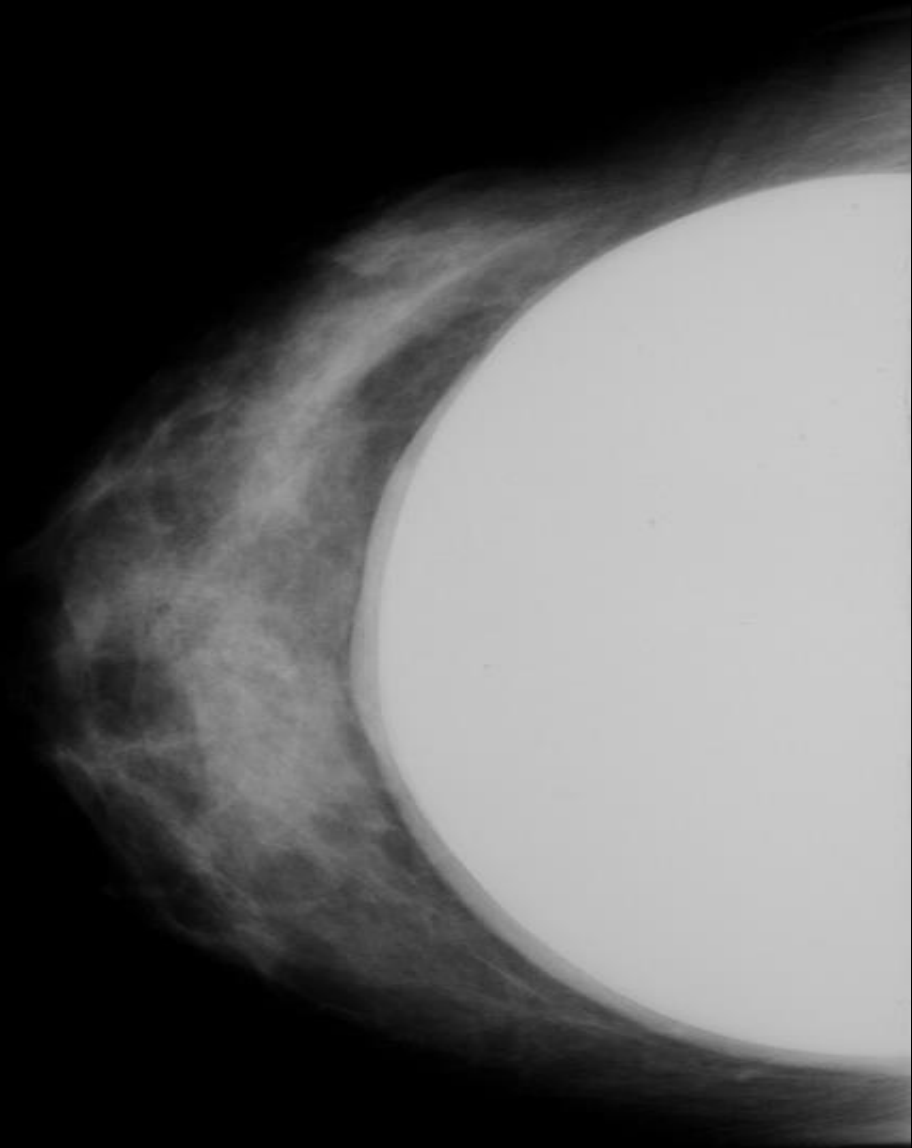


# GEMISTE KANKER

- 78 % door dens weefsel
- 19 % verkeerde interpretatie
- 3 % door slechte positionering

Anubha Wadhwa et al., Current problems in Diagnostic Radiology 45(2016)402-419





# MISINTERPRETATIE

- Asymmetrie
- Microverkalkingen
- Enkel zichtbaar op 1 opname
- Lage densiteit
- **Traag groeiende massa's**



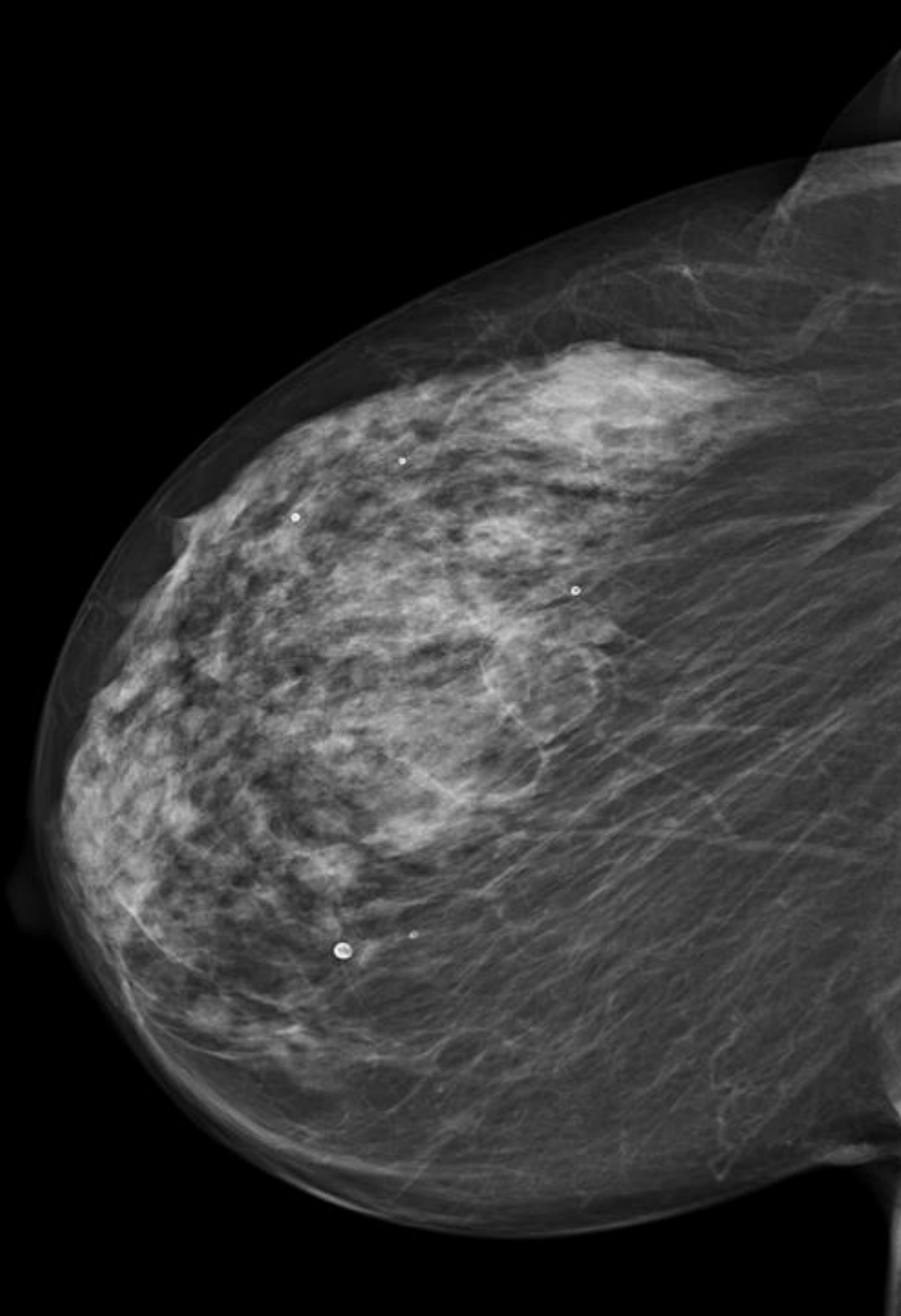
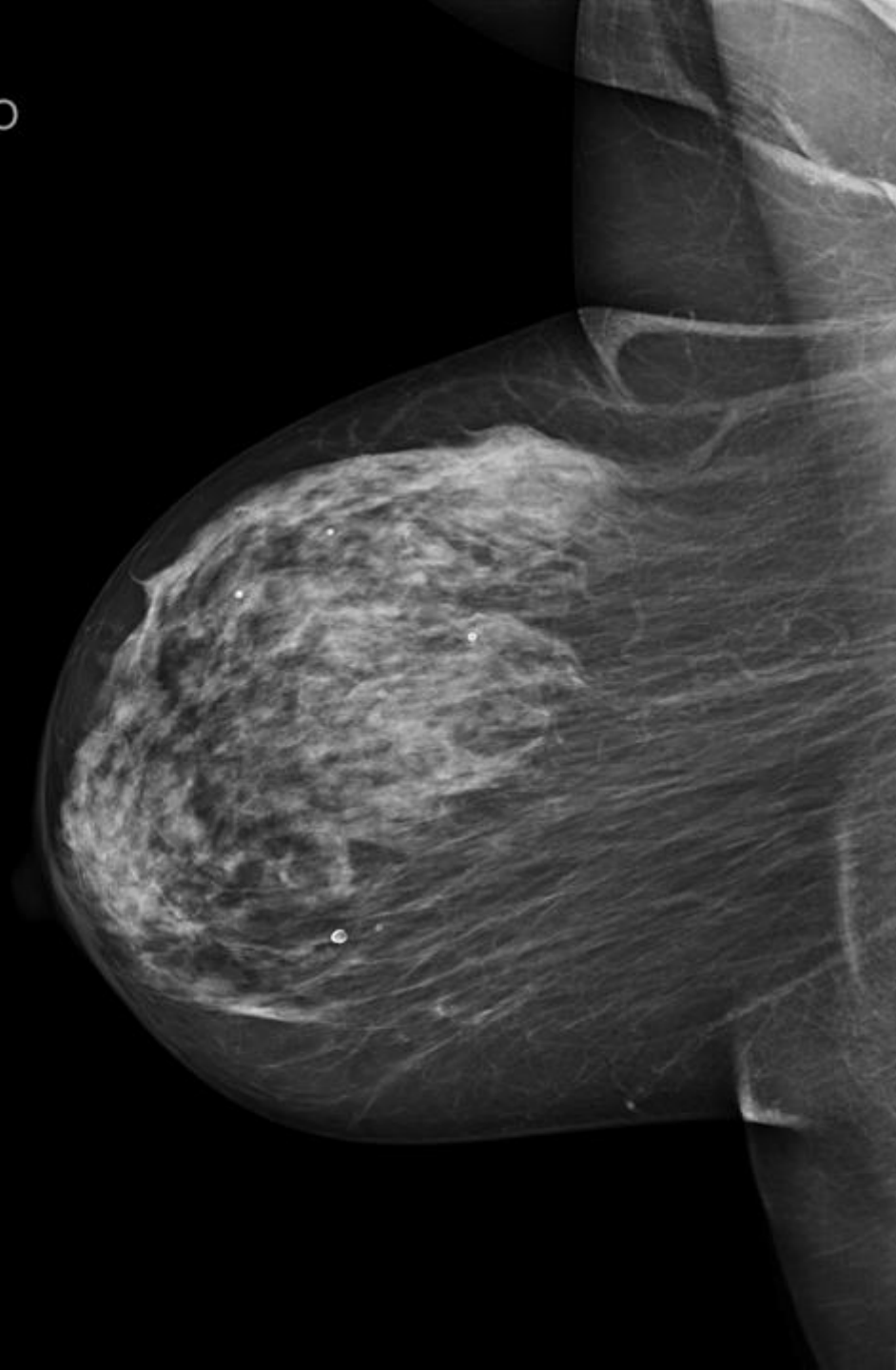


# INTERVALKANKER

- Vals negatieve en minimal sign
- Misinterpretatie voorkomen
  - Training
  - Voldoende screeningsvolume
  - Continue audit/feedback



MLO



# RECALL ?

Votes please !

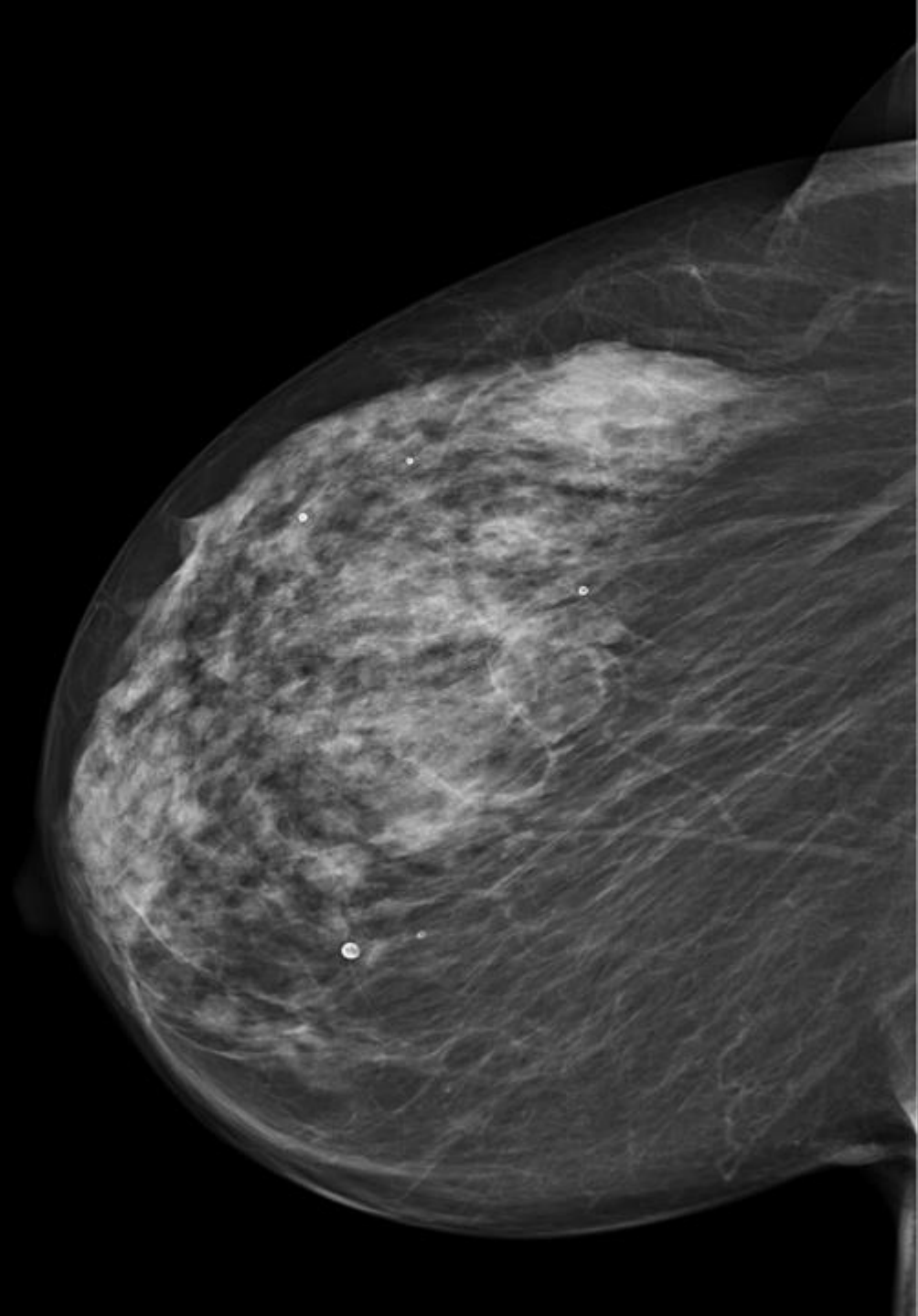
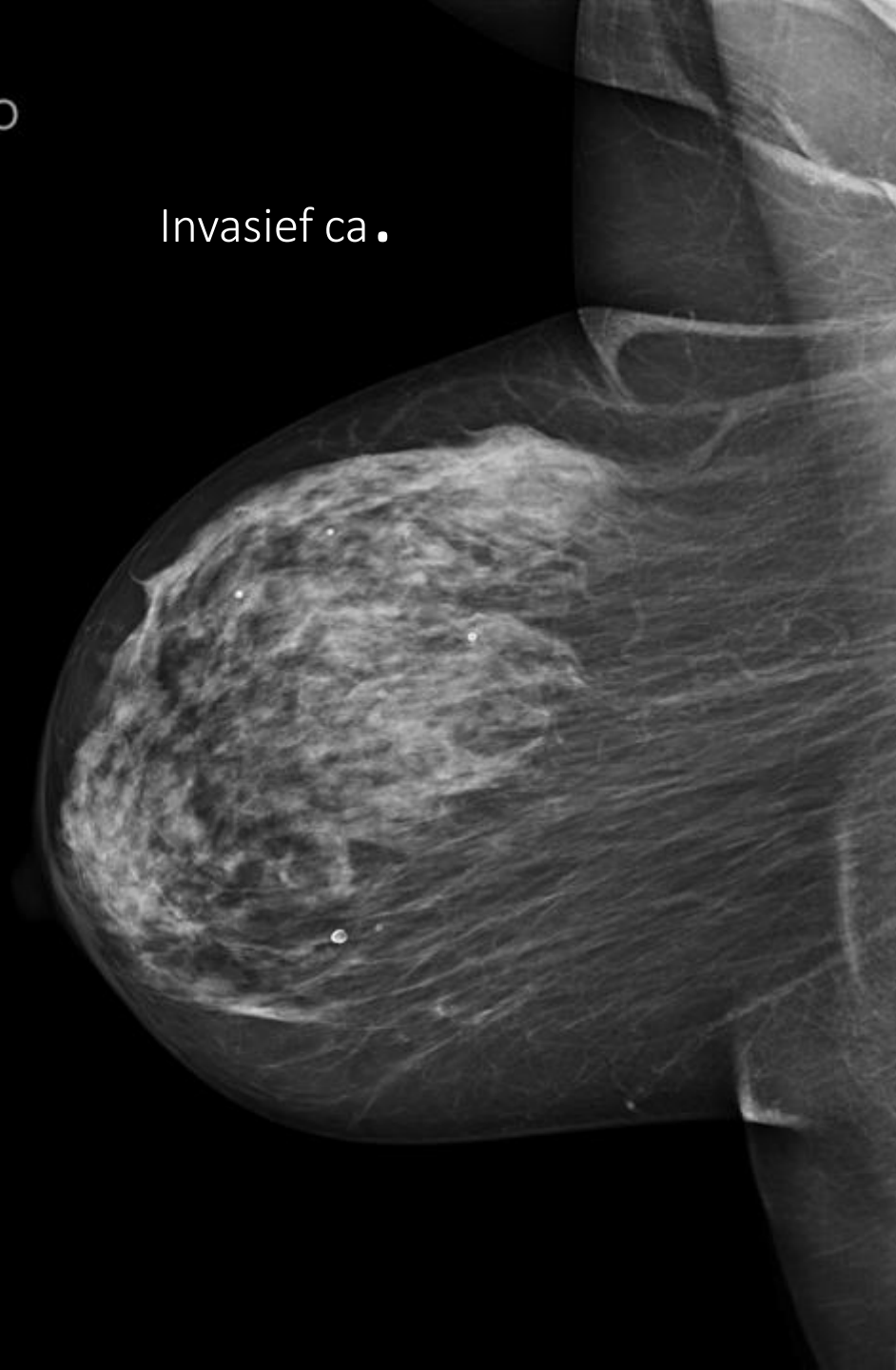


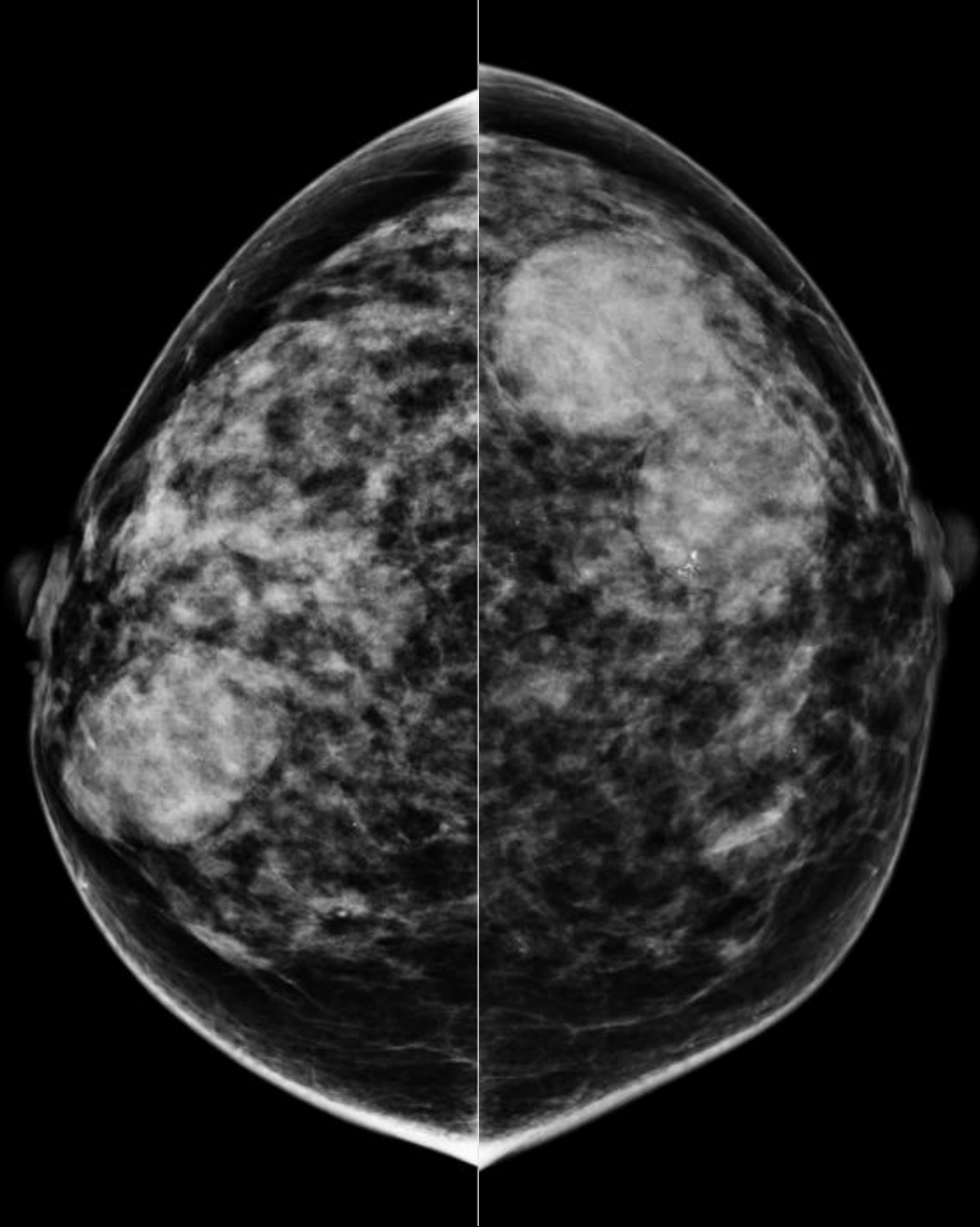
 Universiteit  
Antwerpen

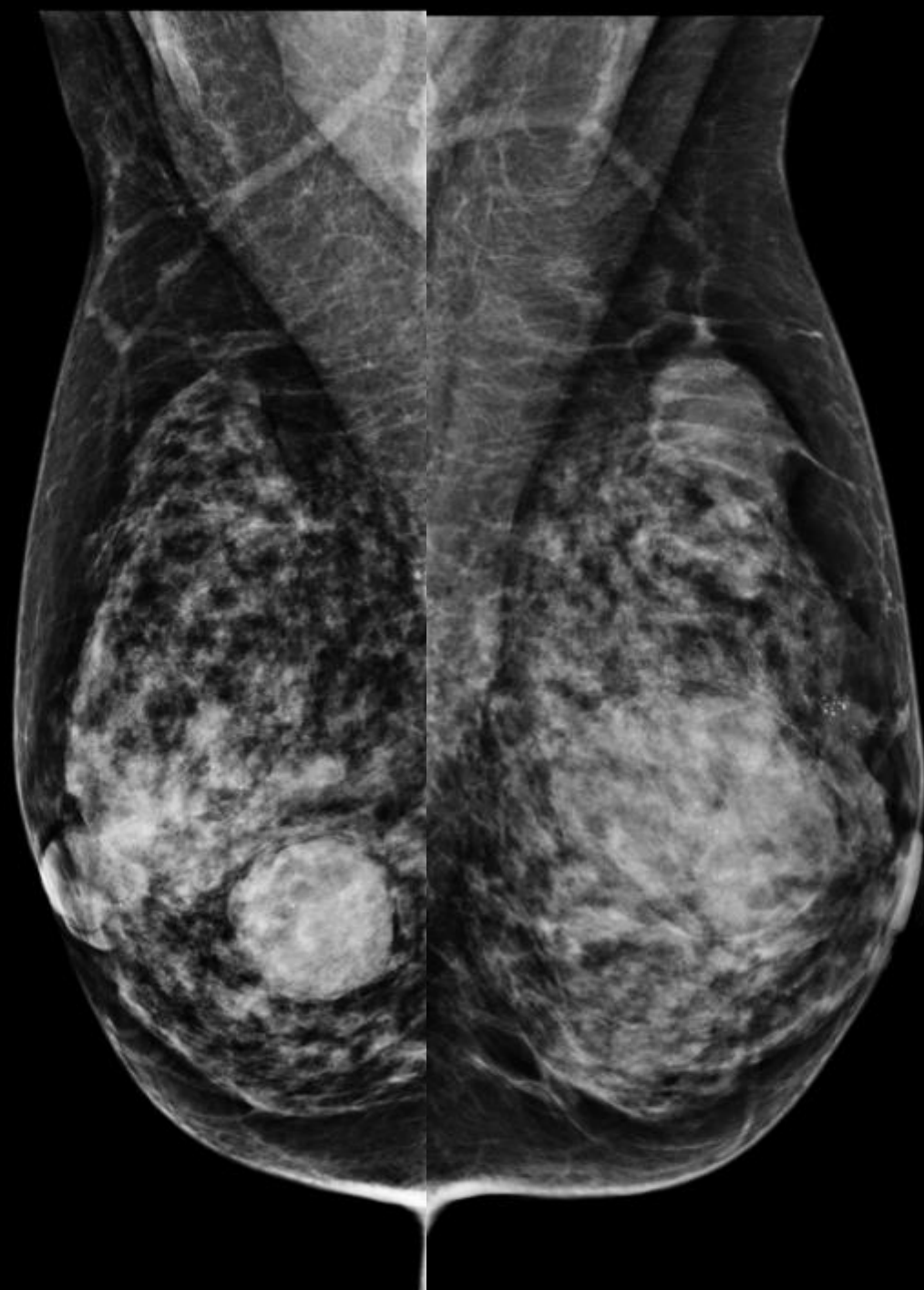


MLO

Invasief ca.









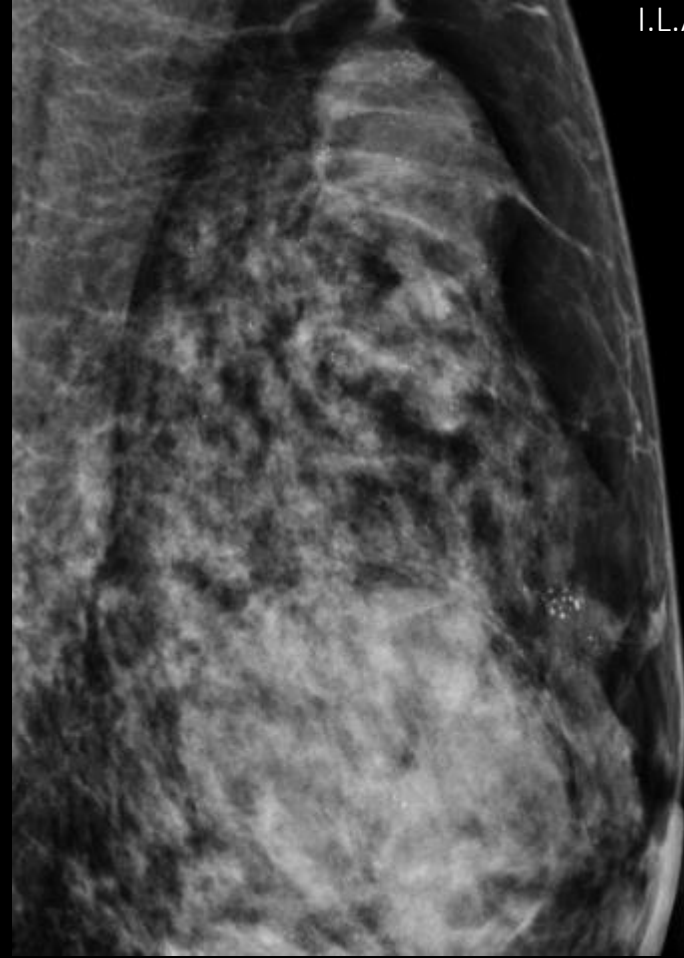
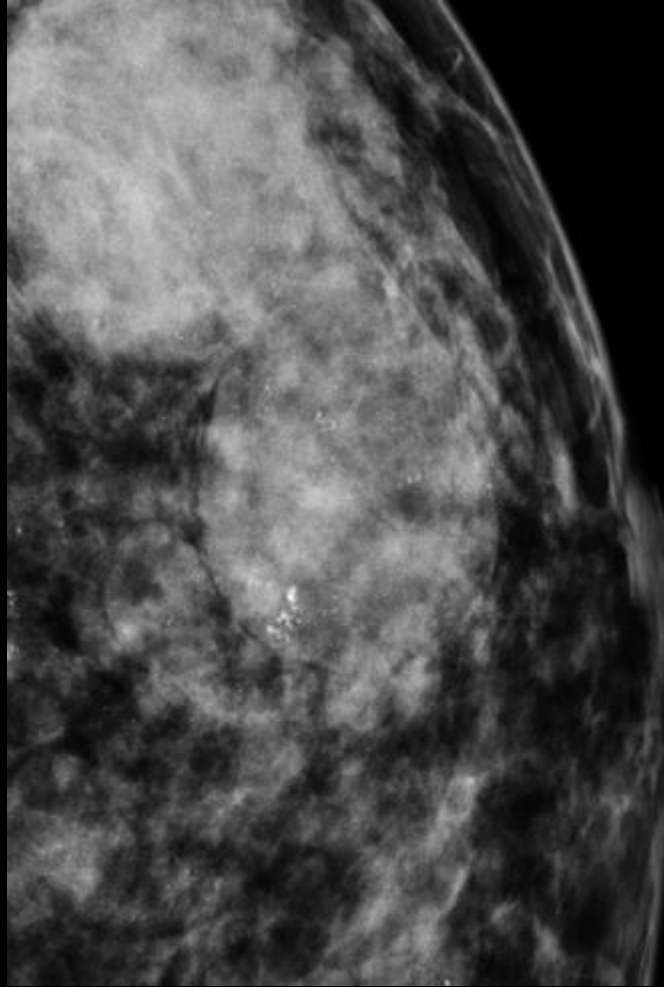
# RECALL ?

Votes please !



 Universiteit  
Antwerpen



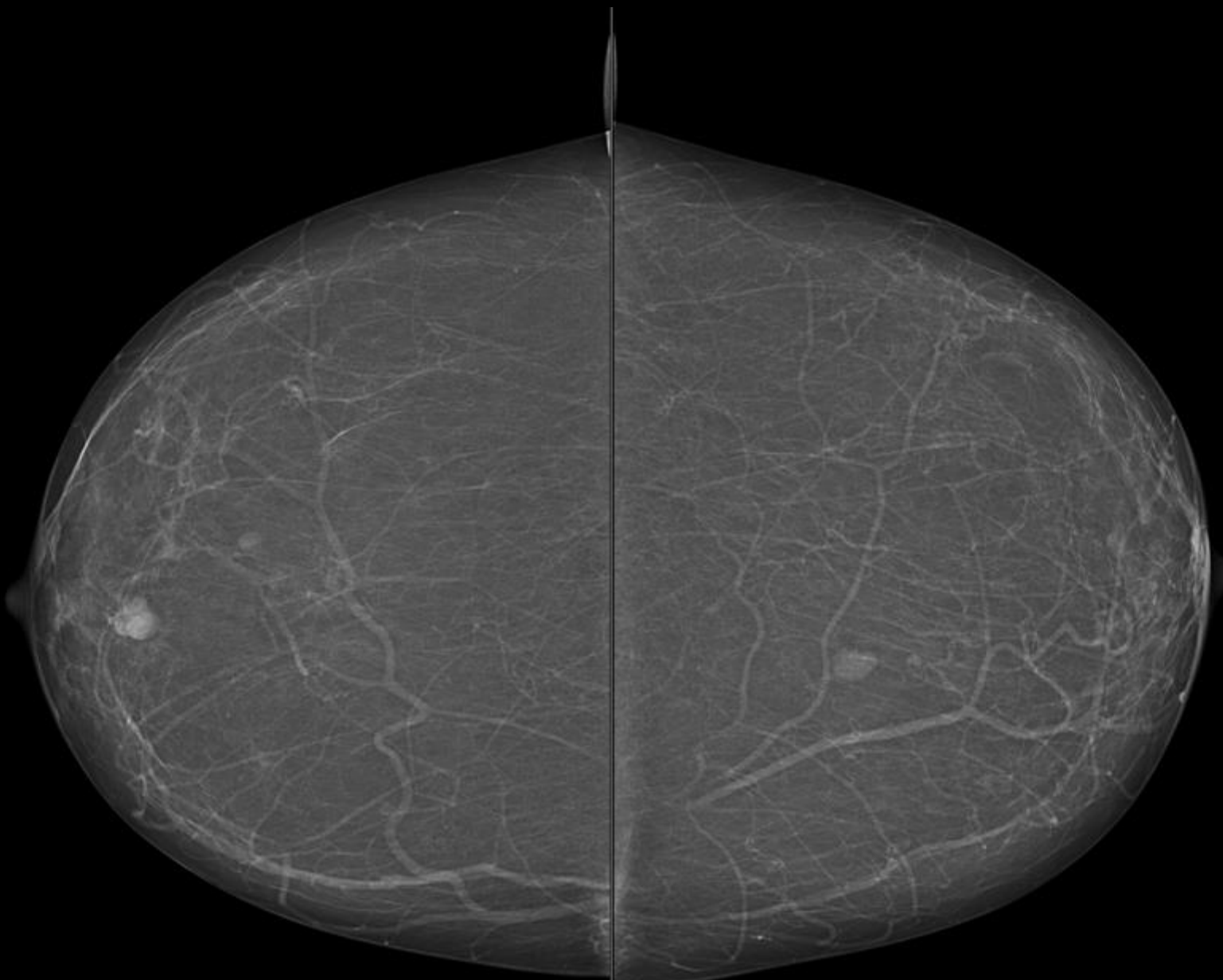


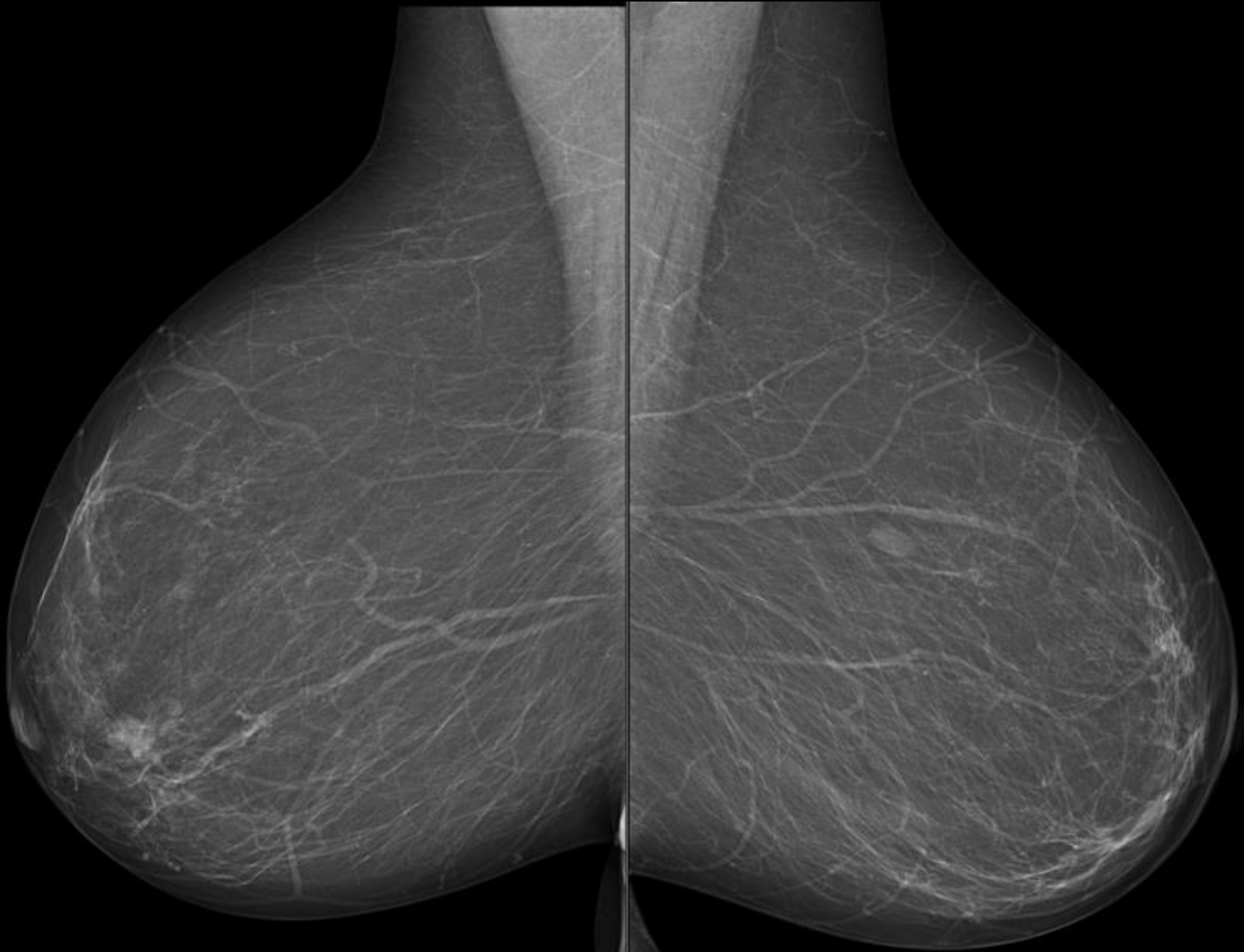
I.L.A.+L.C.I.S



R  
CC

L  
CC





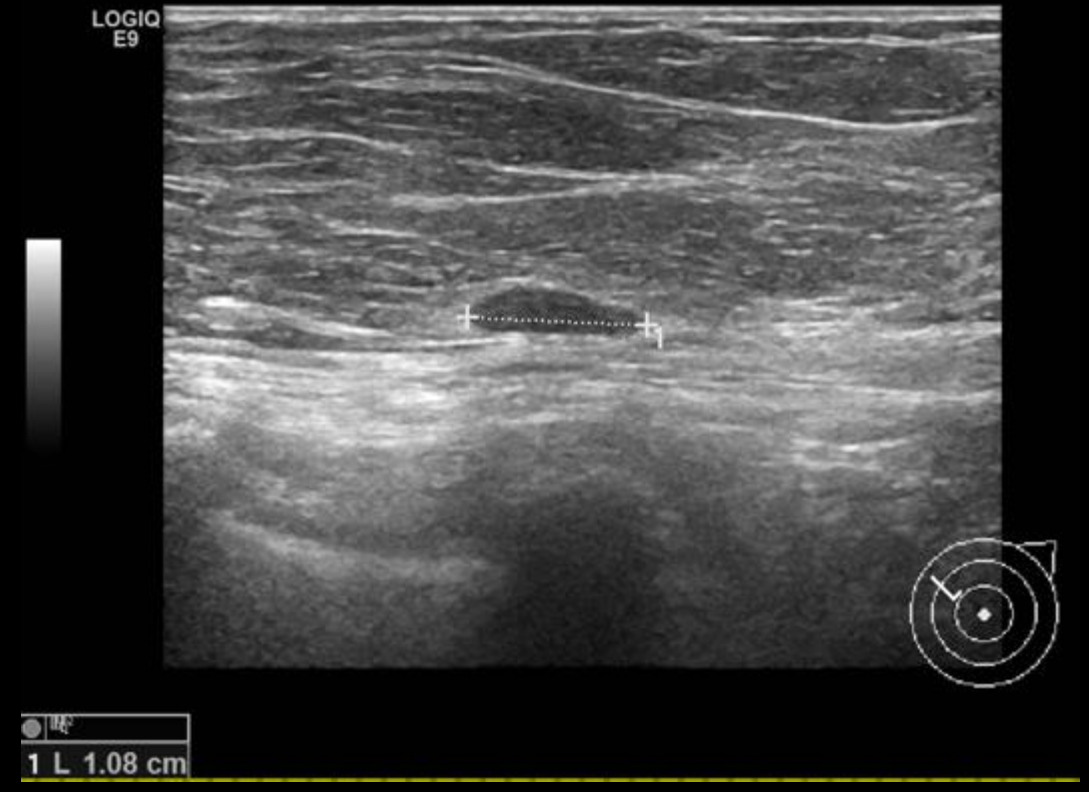
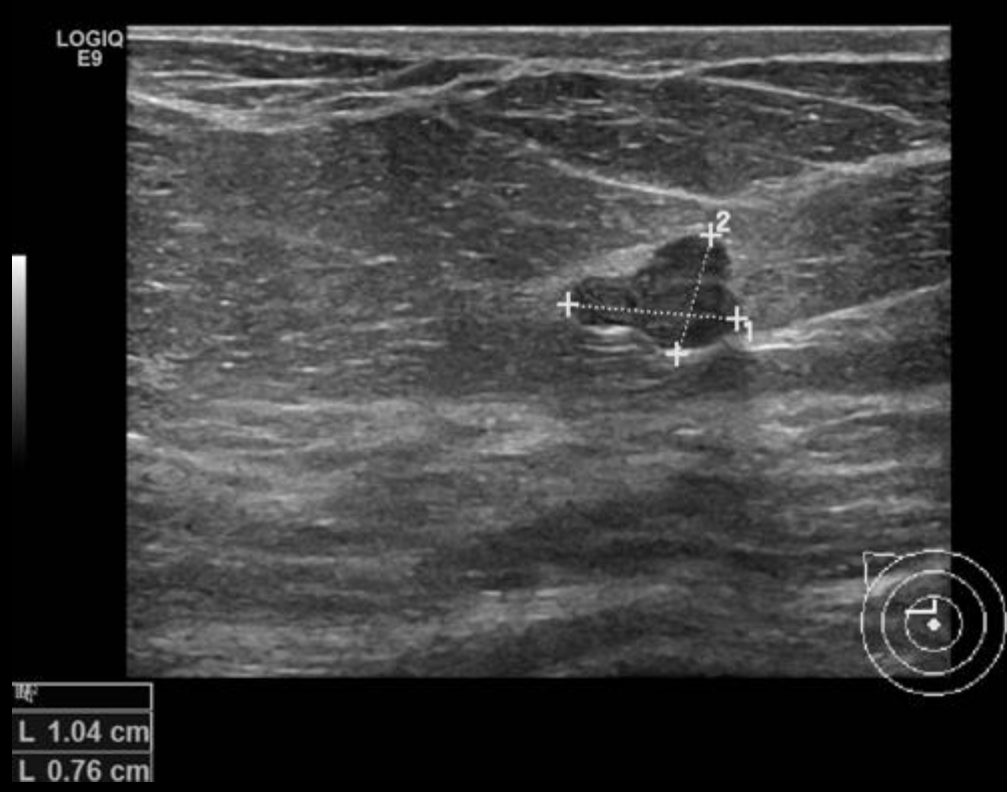# RECALL ?

Votes please !

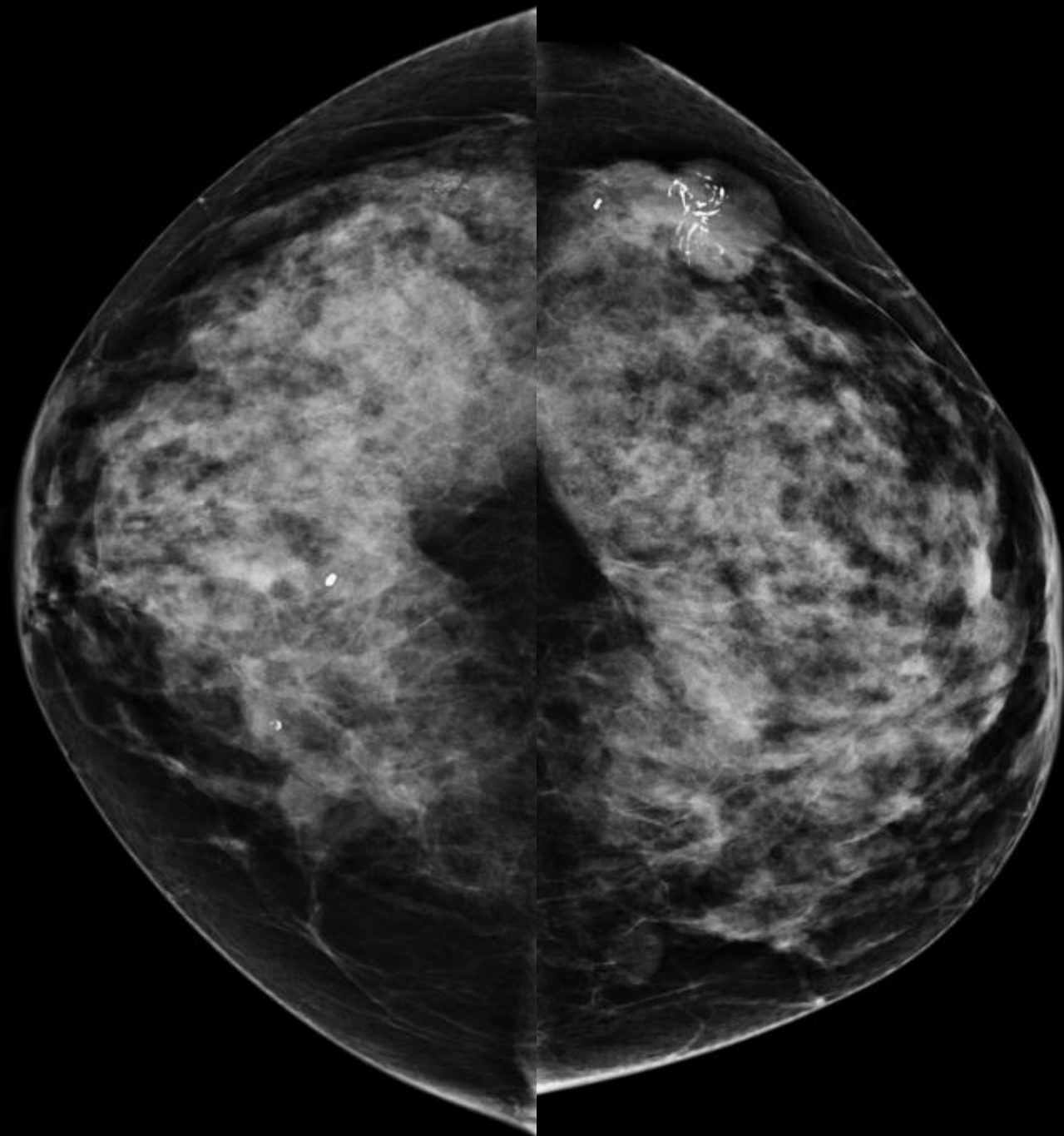


 Universiteit  
Antwerpen

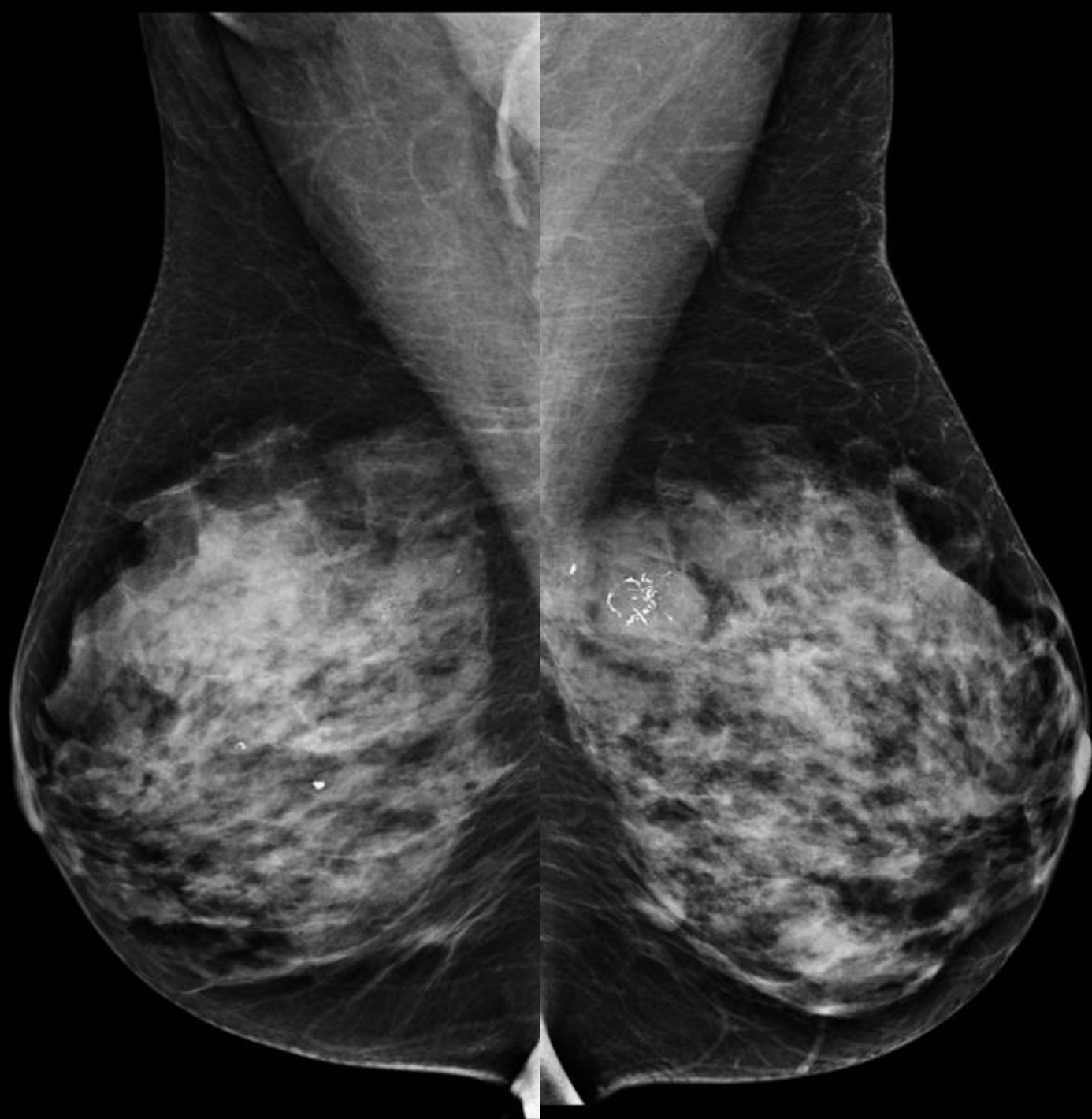




FA met calcificaties







# RECALL ?

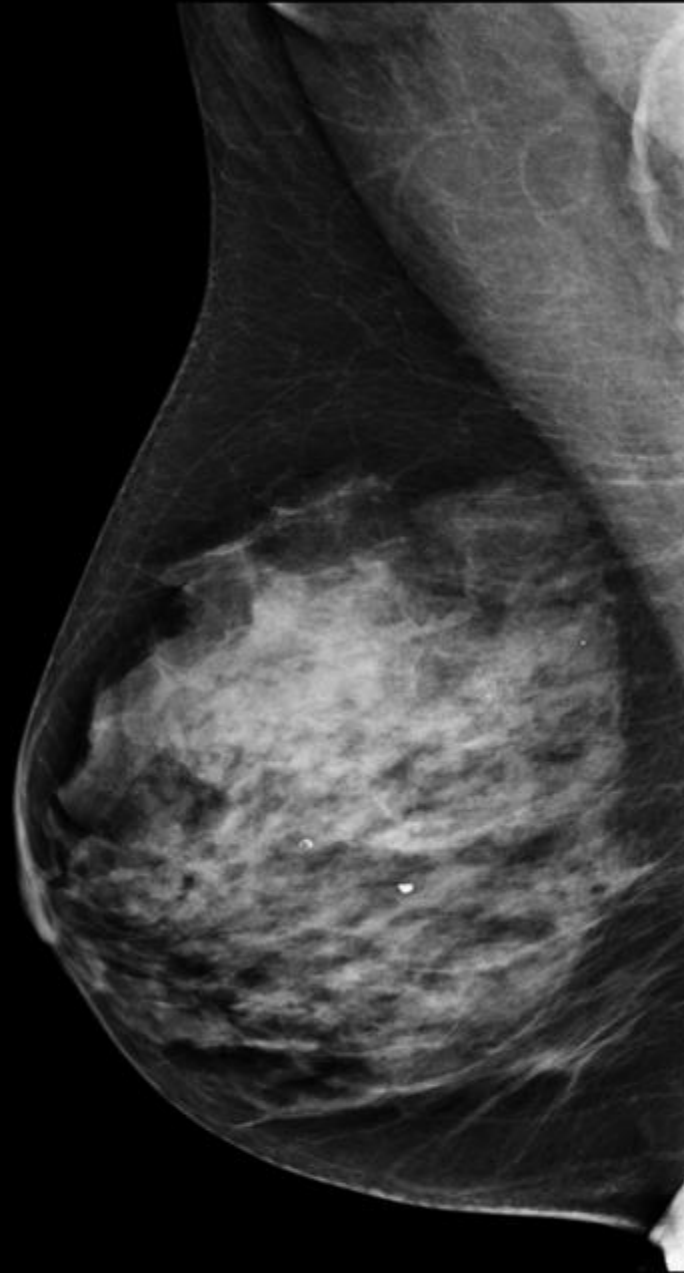
Votes please !



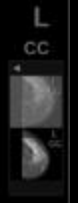
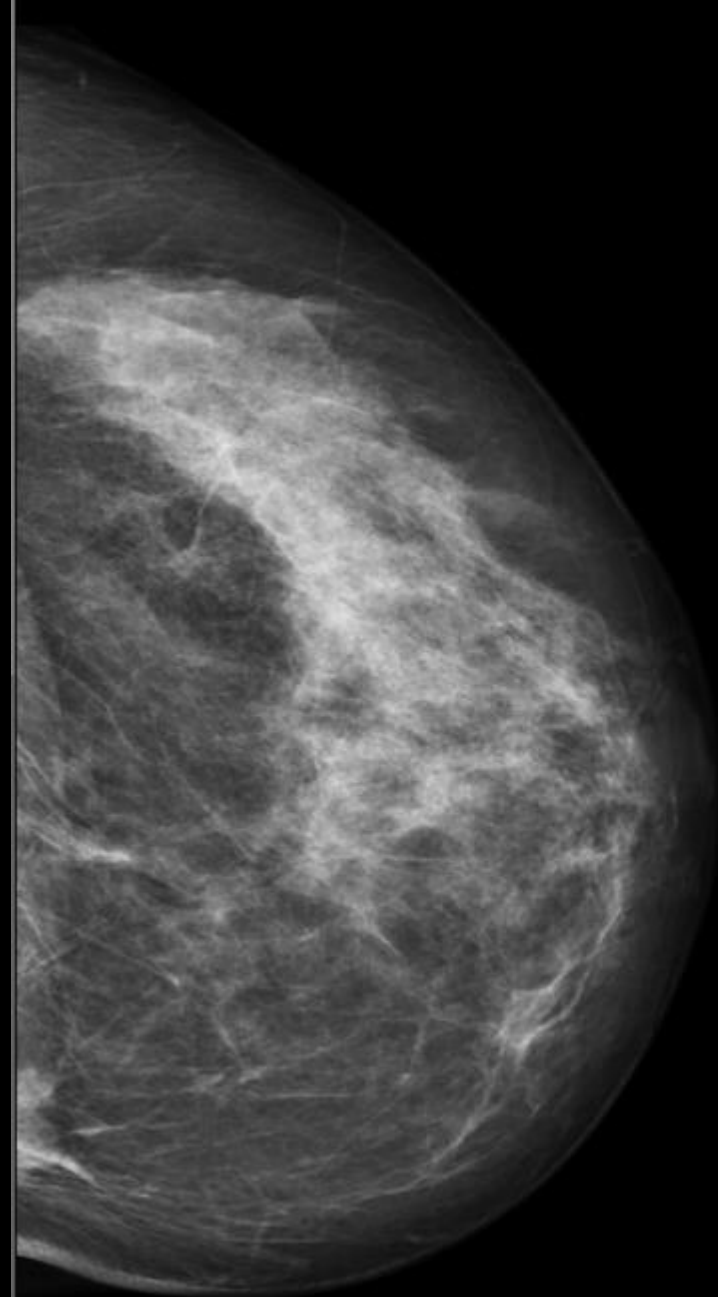
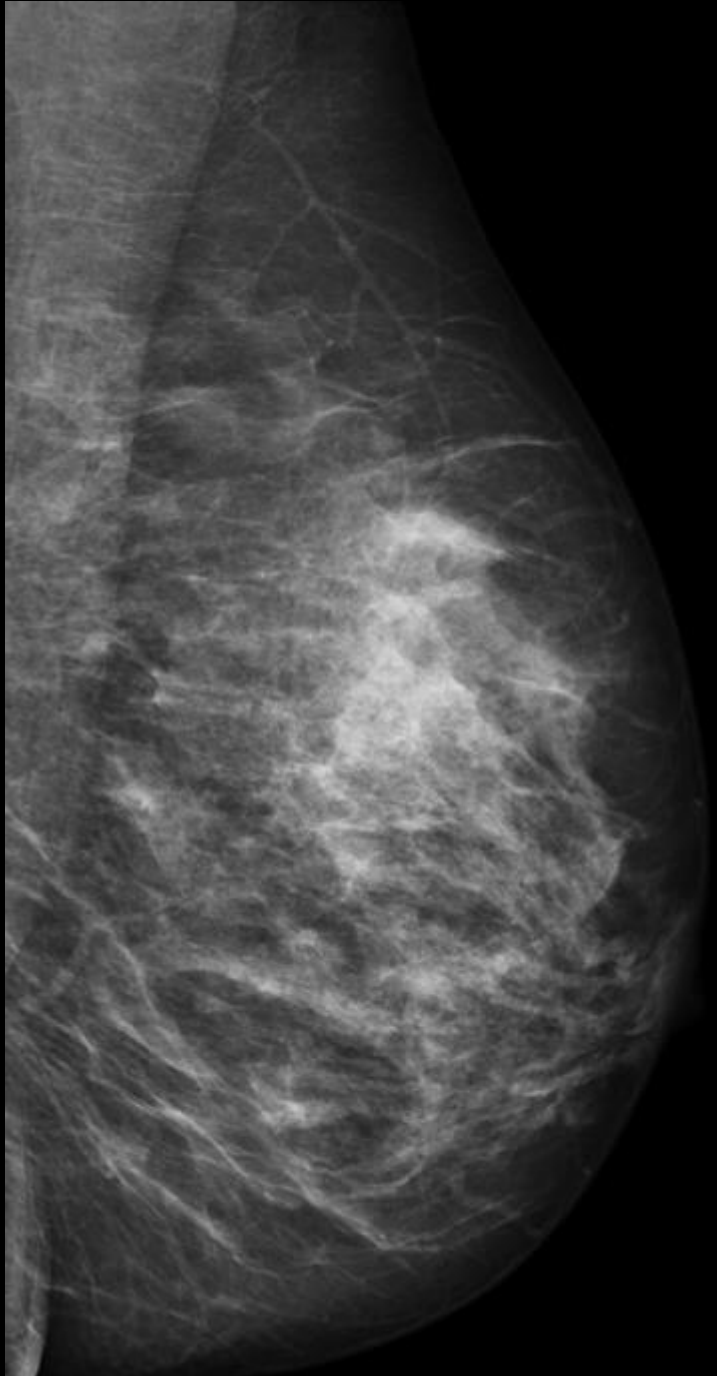
 Universiteit  
Antwerpen



D.C.I.S.







1cm

16/10/2012

1.0.0001  
[1.81 cm]  
unipolar

# RECALL ?

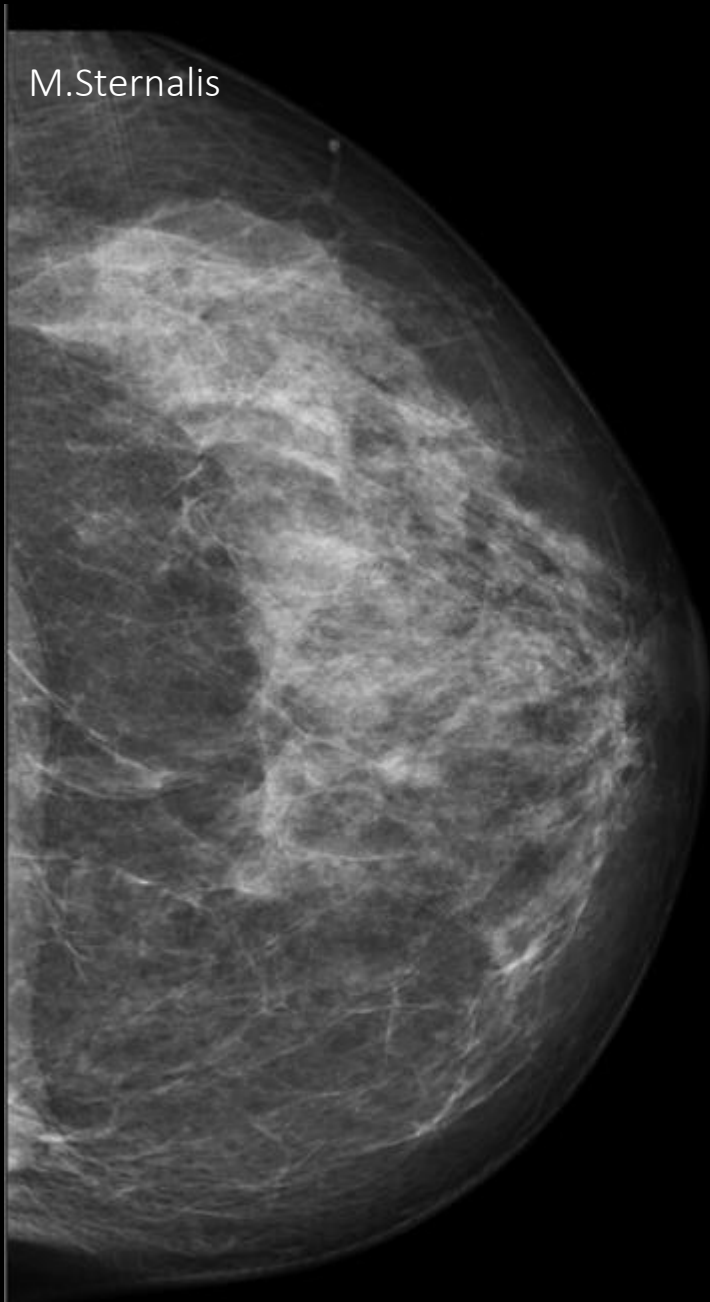
Votes please !



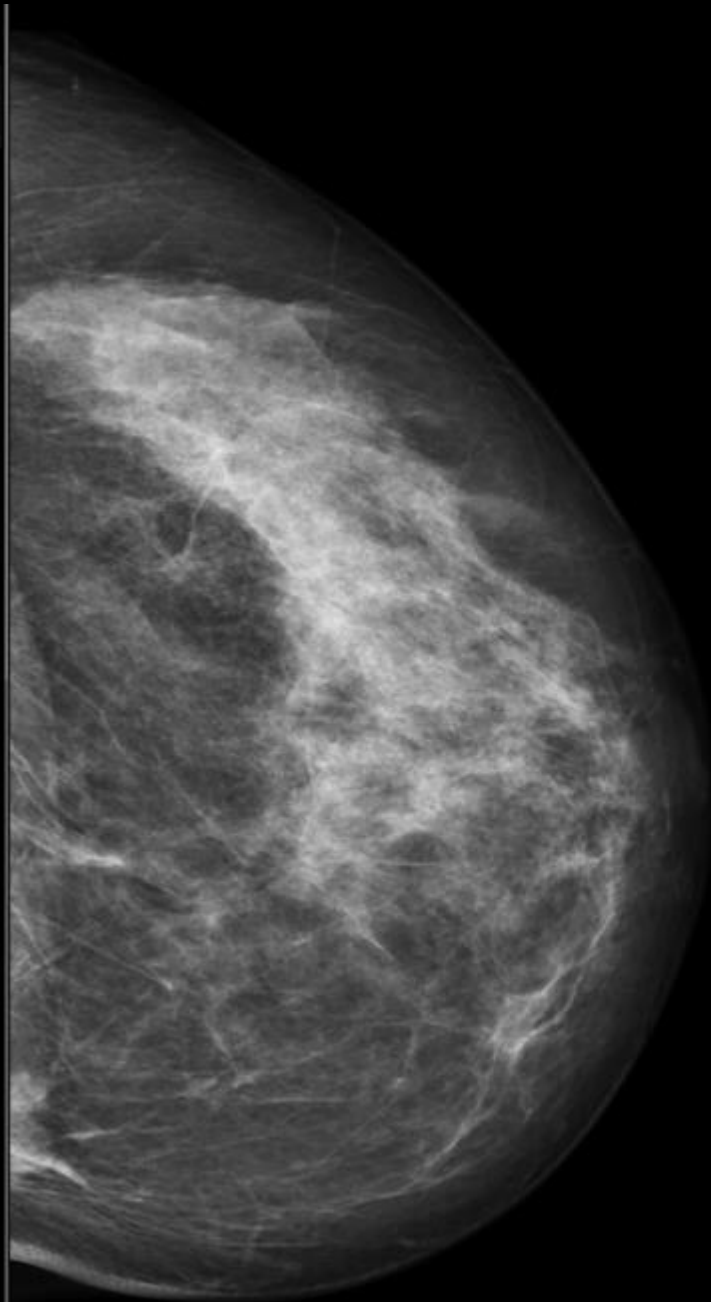
 Universiteit  
Antwerpen



M.Sternalis



31/10/2016

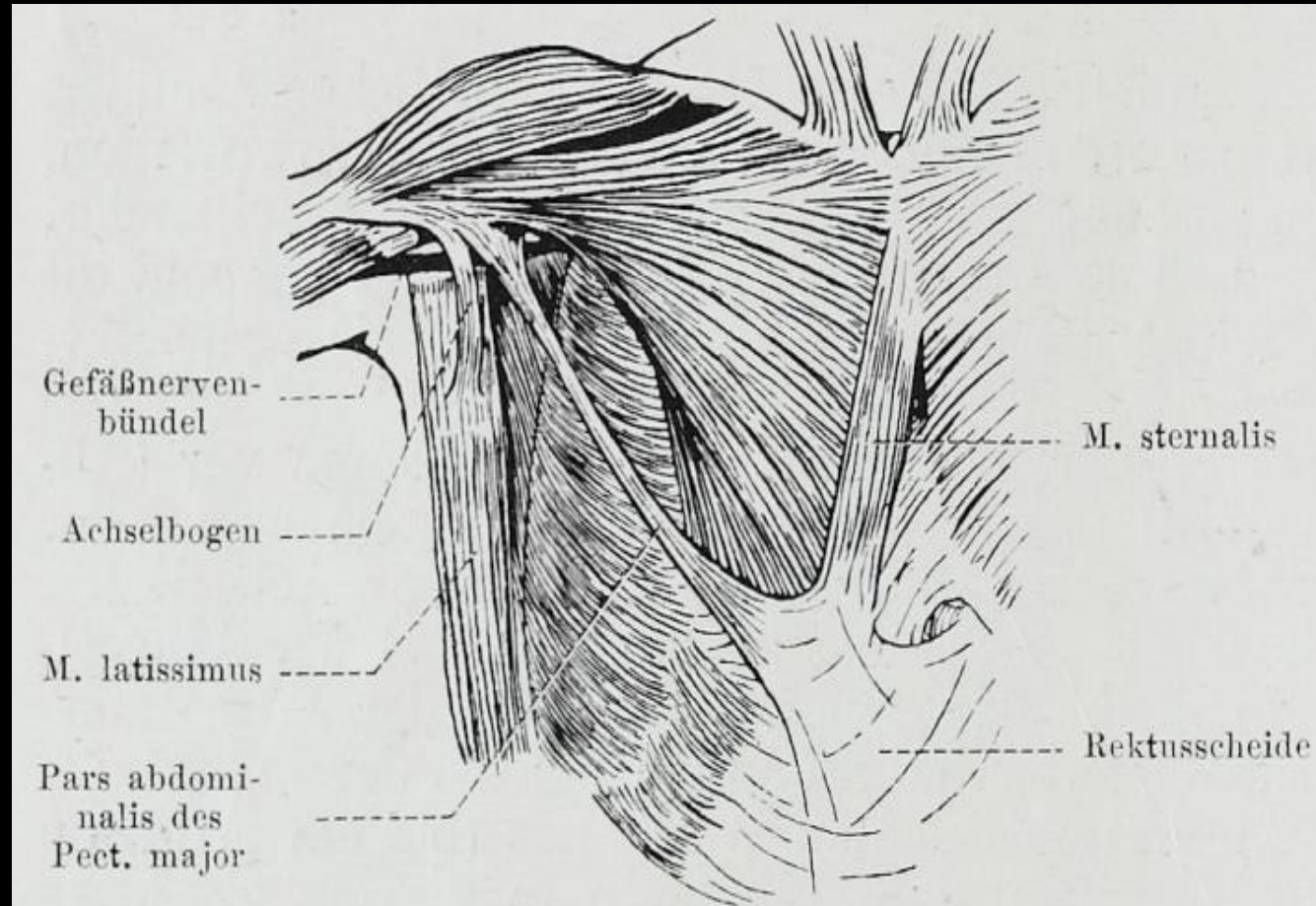


16/10/2012



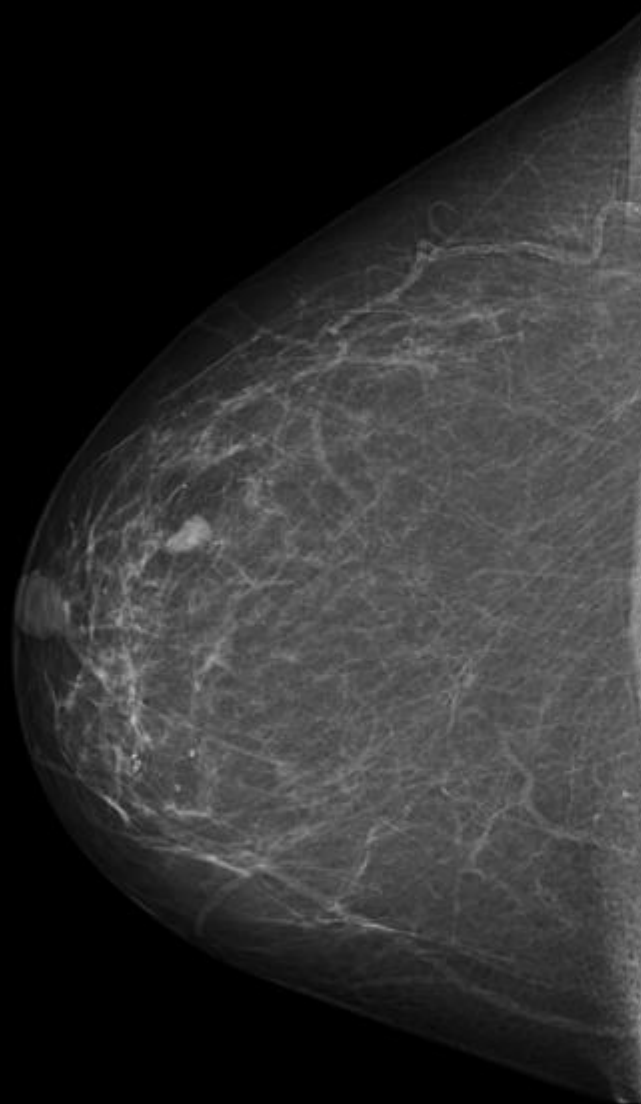
16/10/2012

# Musculus Sternalis



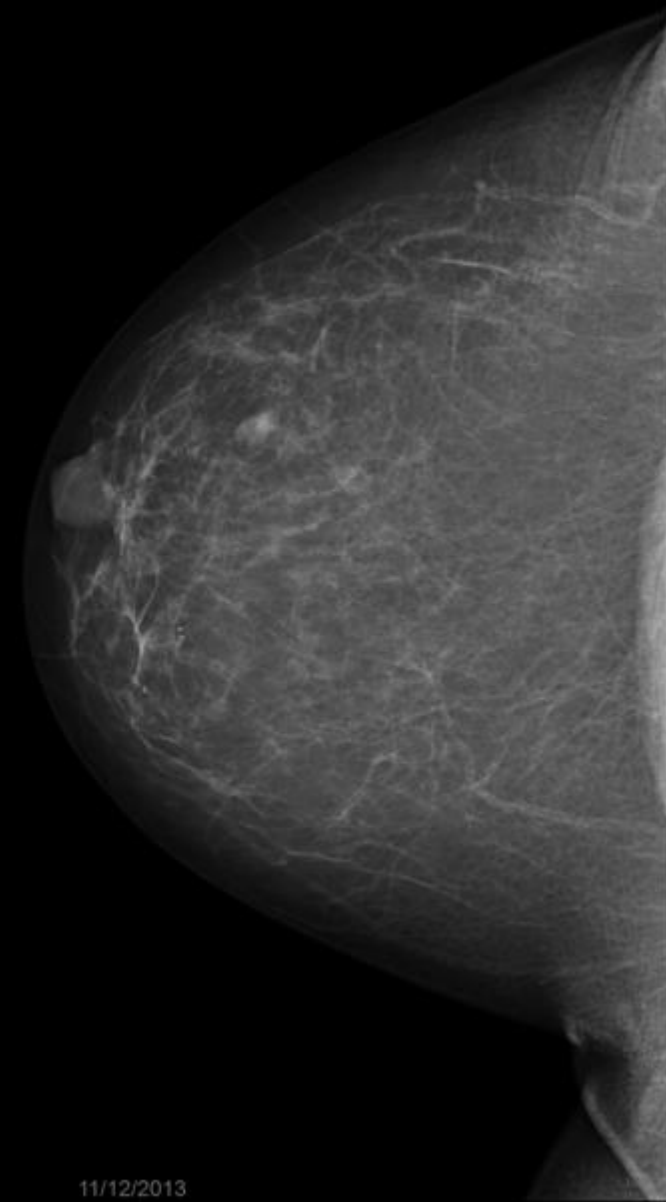
R

CC

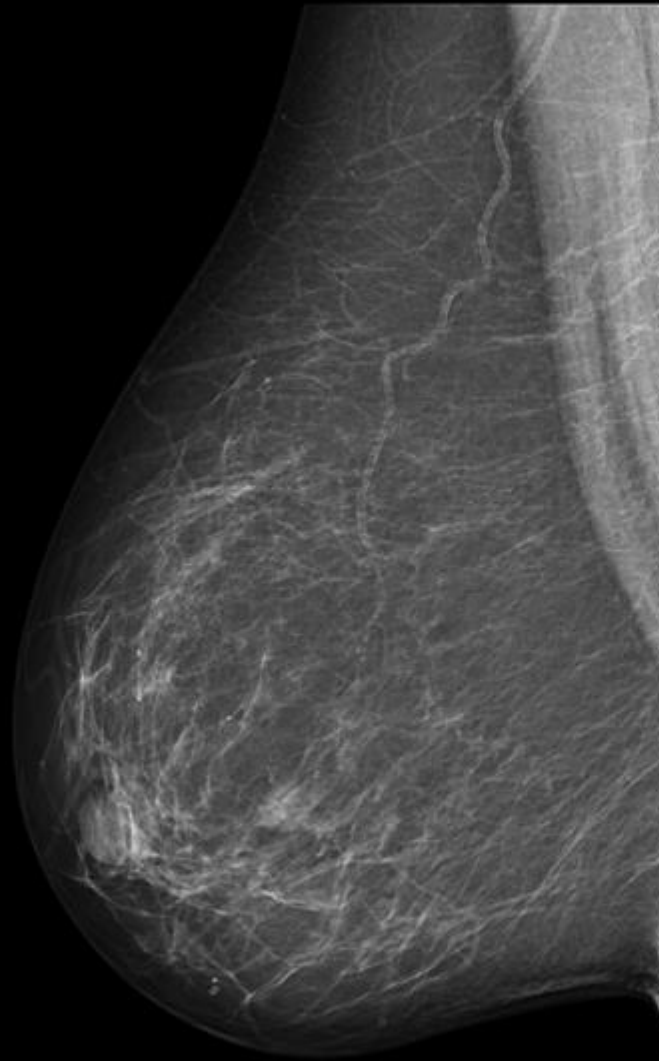


R

CC



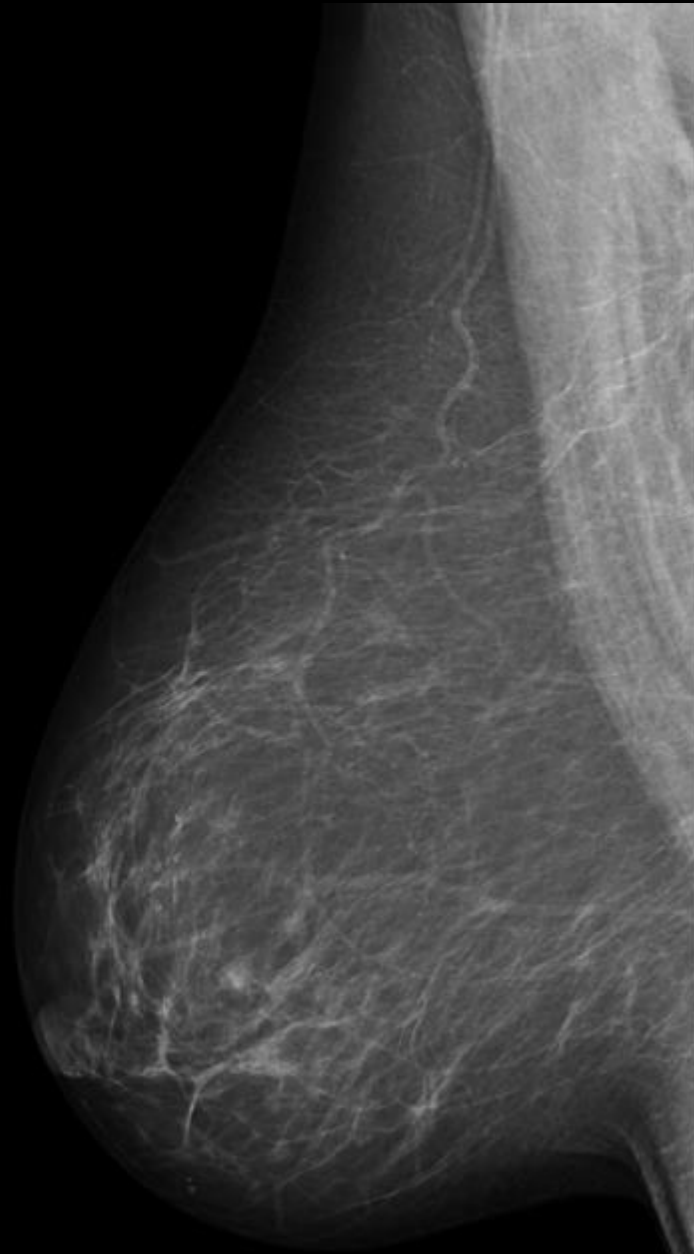




1.0.8075  
[1.48 cm]  
interpolated

20/12/2017

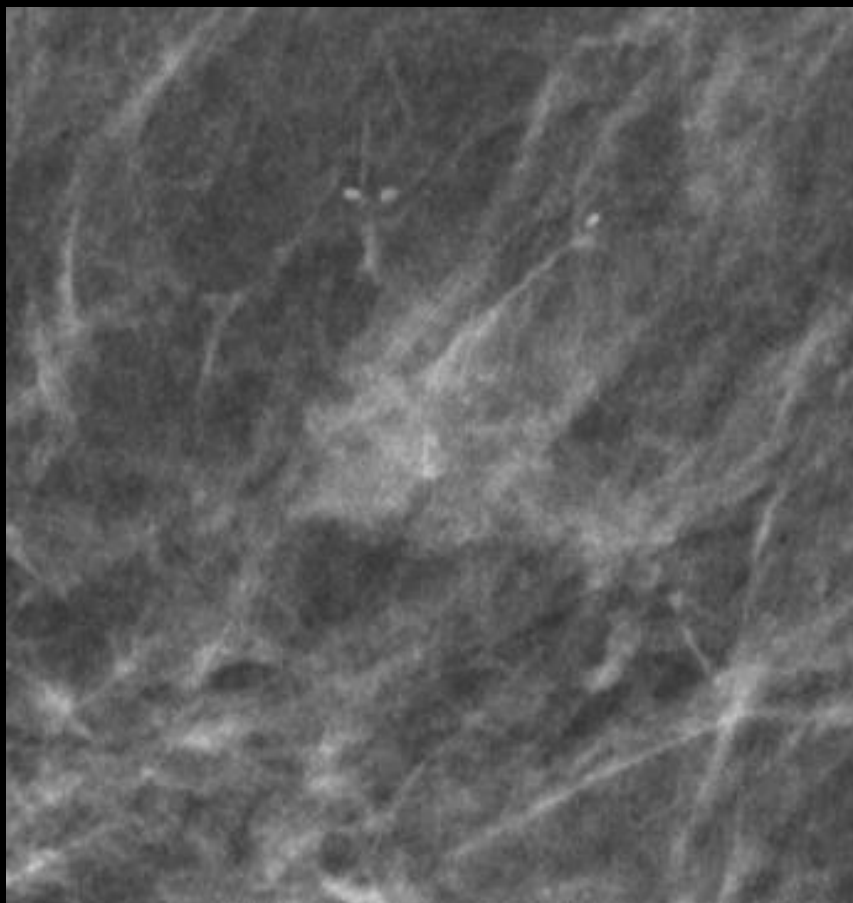
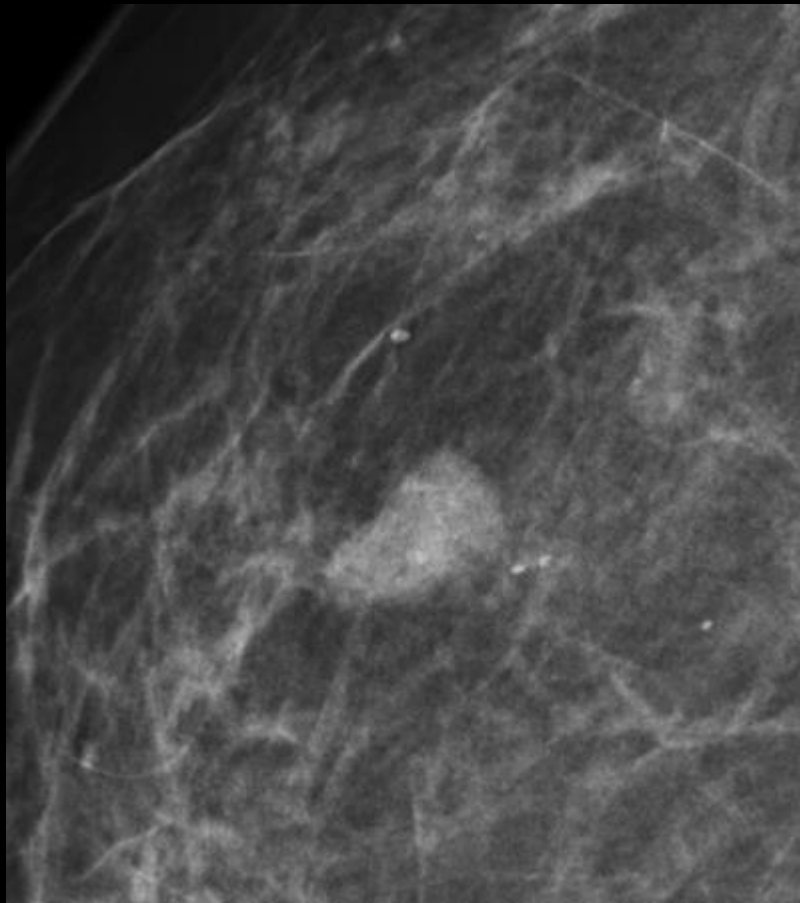
1cm



1.0.8075  
[1.48 cm]  
interpolated

11/12/2013

1cm



# RECALL ?

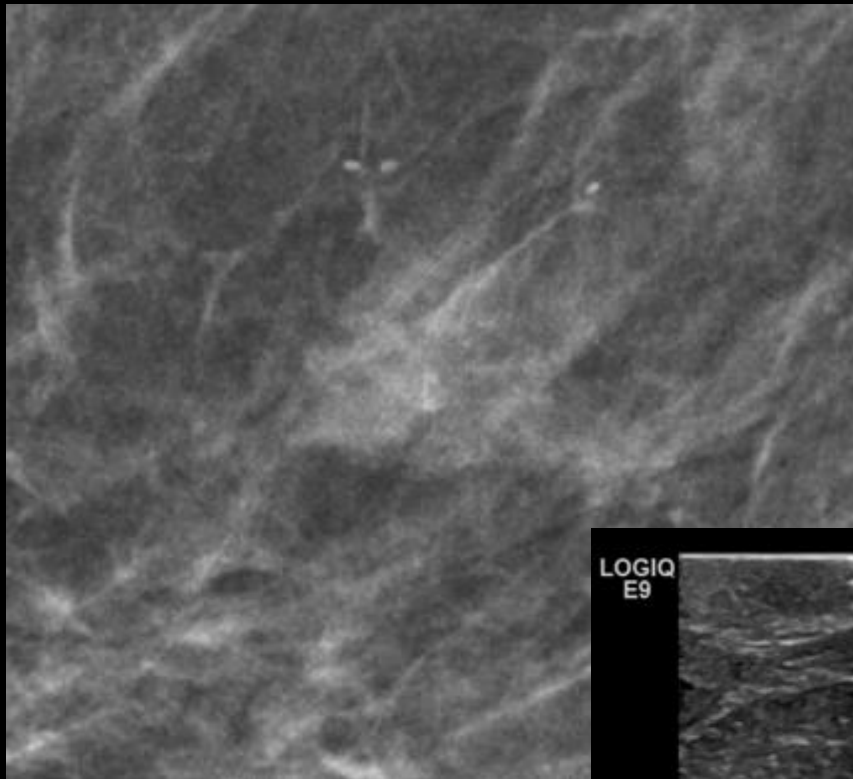
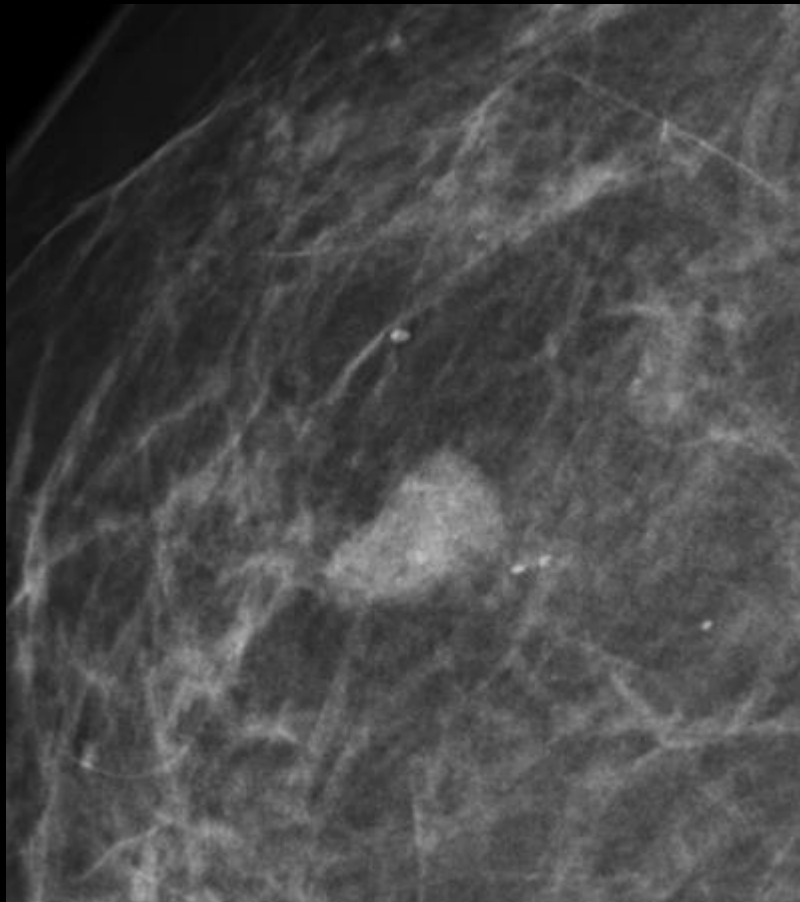
Votes please !



 Universiteit  
Antwerpen

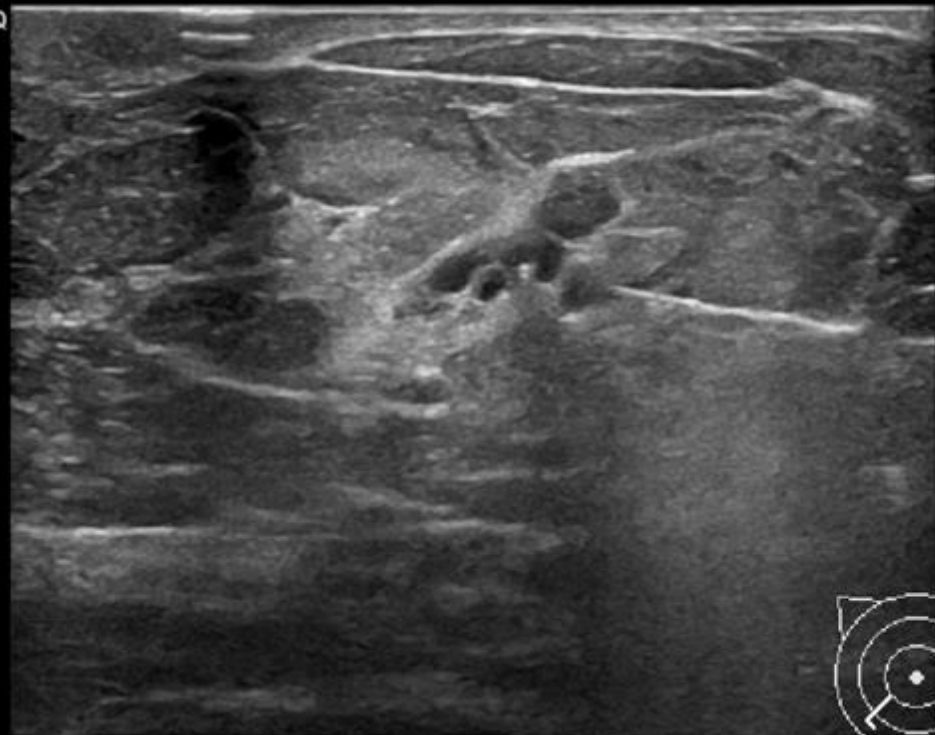


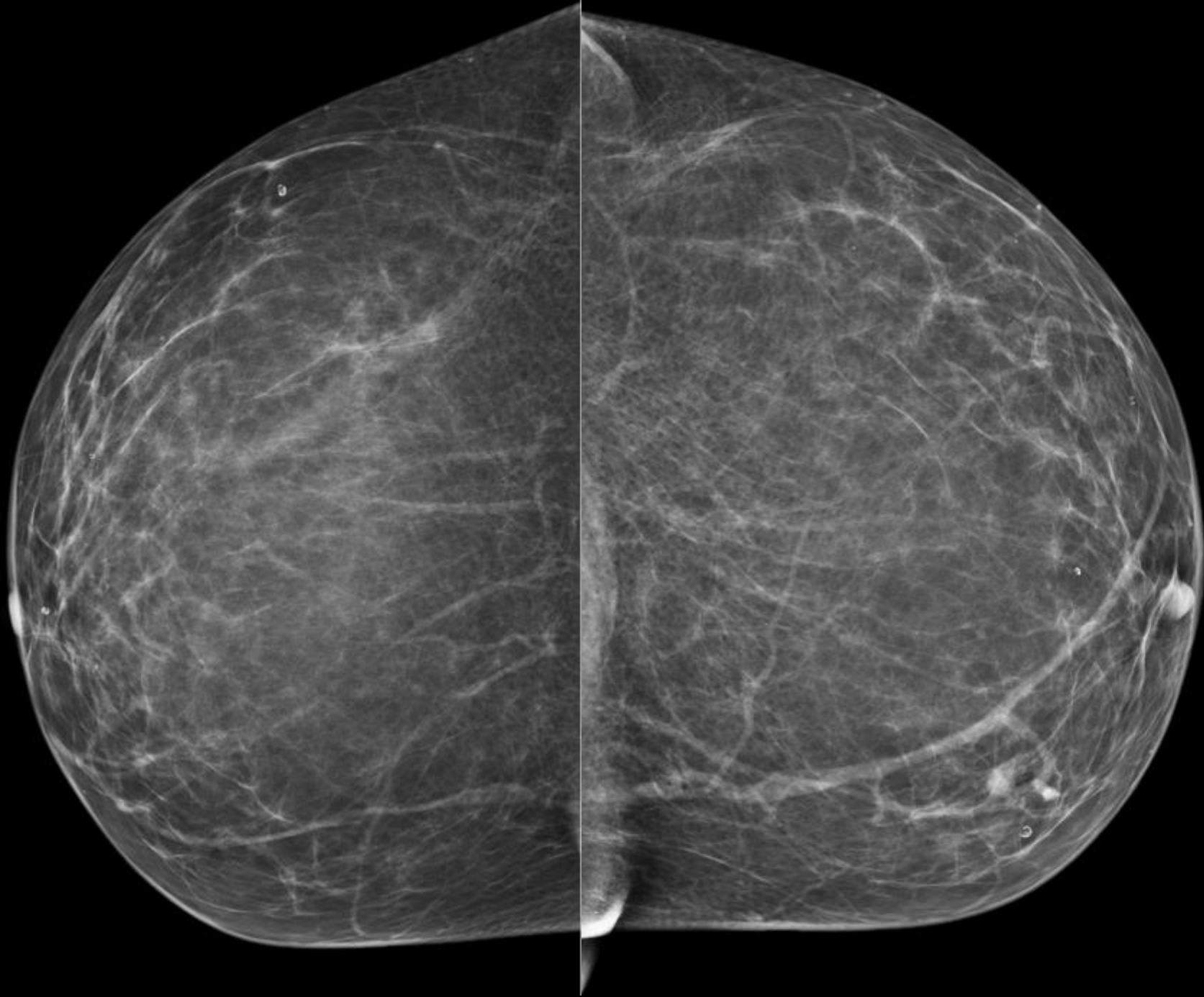


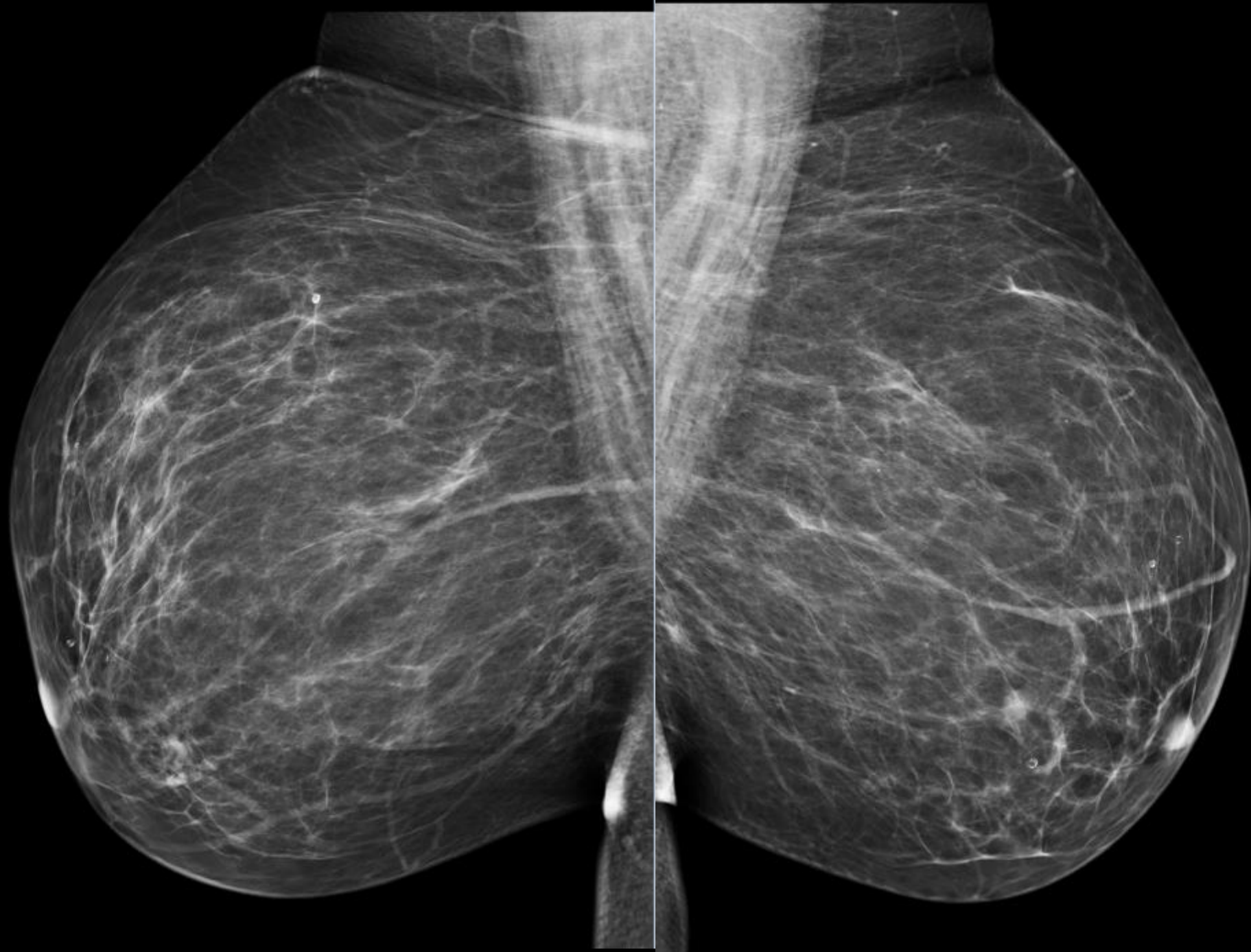

Benigne veranderingen  
B2

LOGIQ  
E9







# RECALL ?

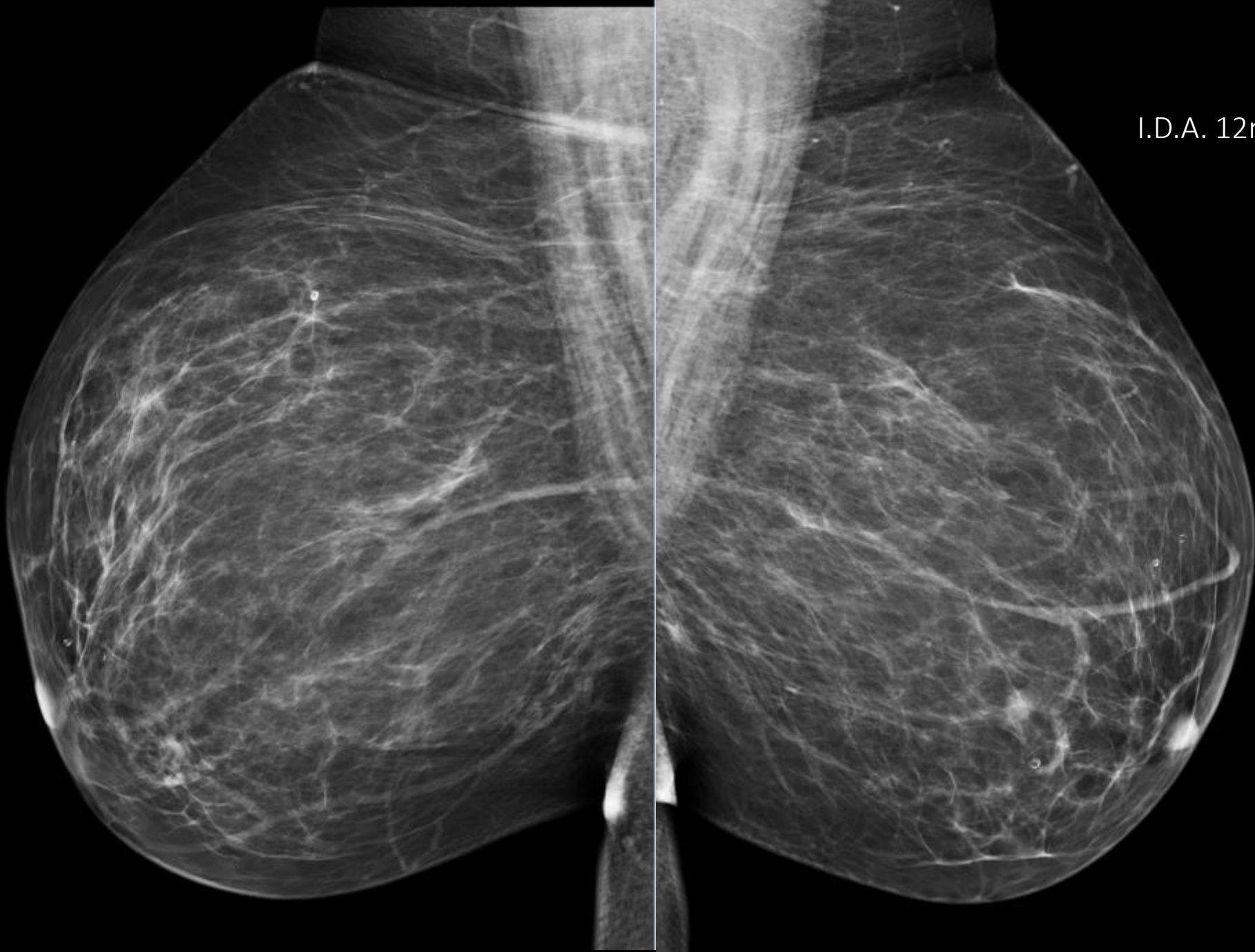
Votes please !



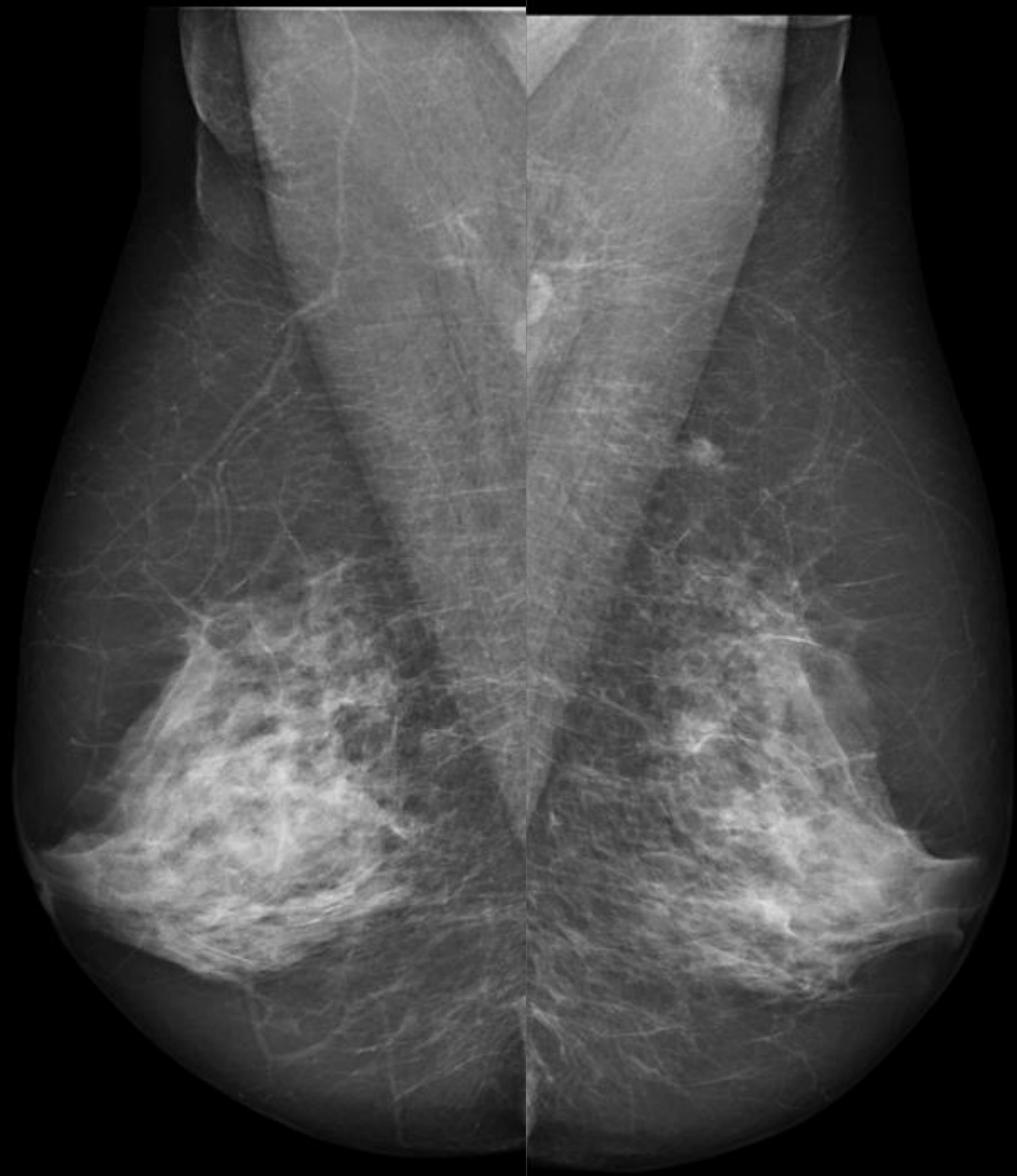 Universiteit  
Antwerpen

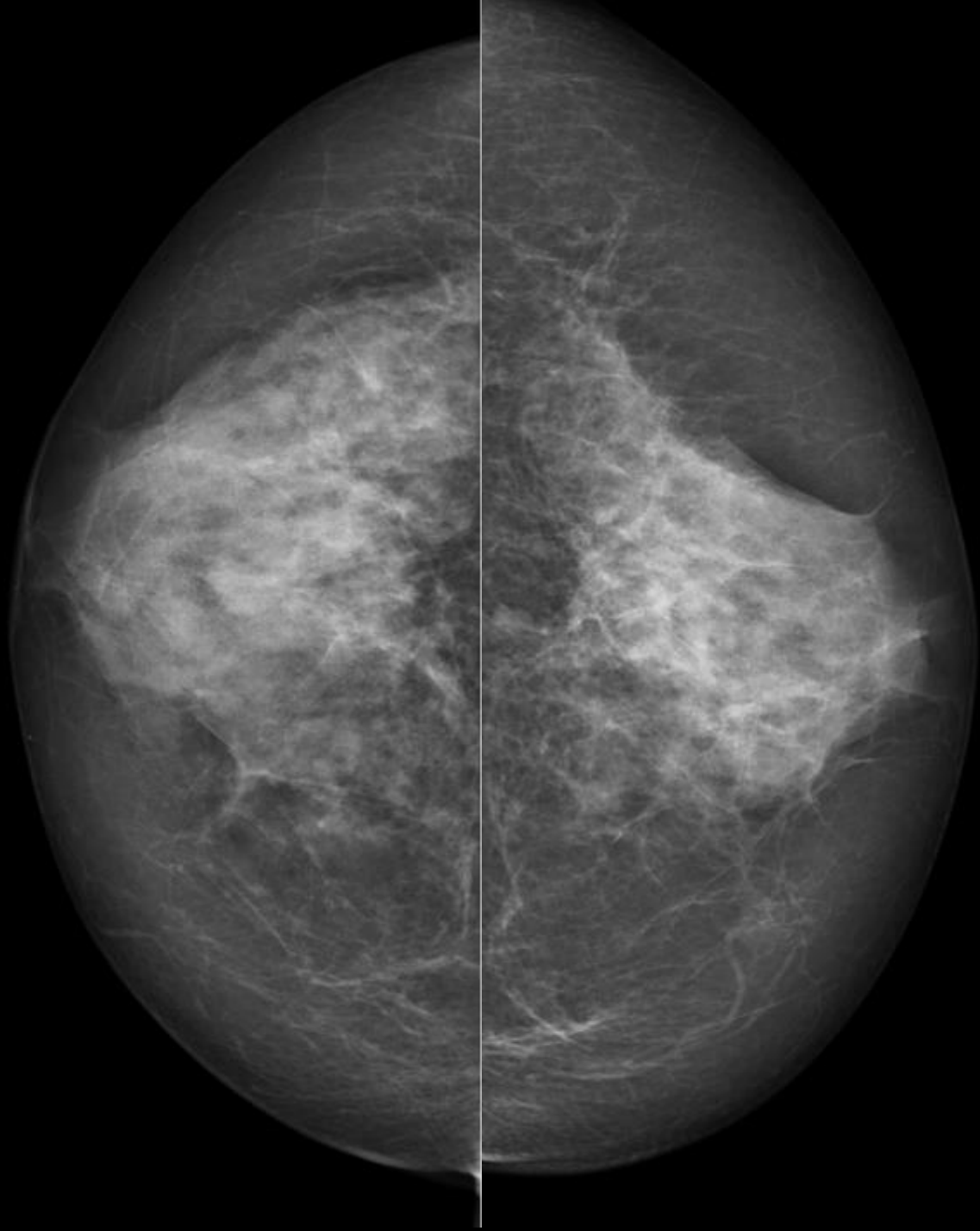






I.D.A. 12mm.





# RECALL ?

Votes please !

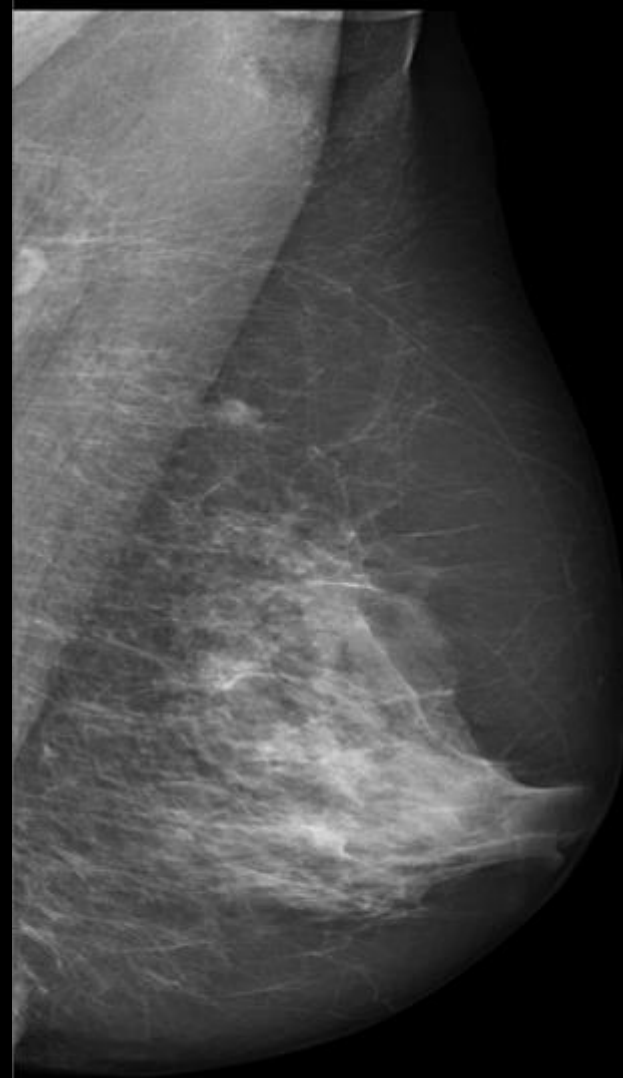
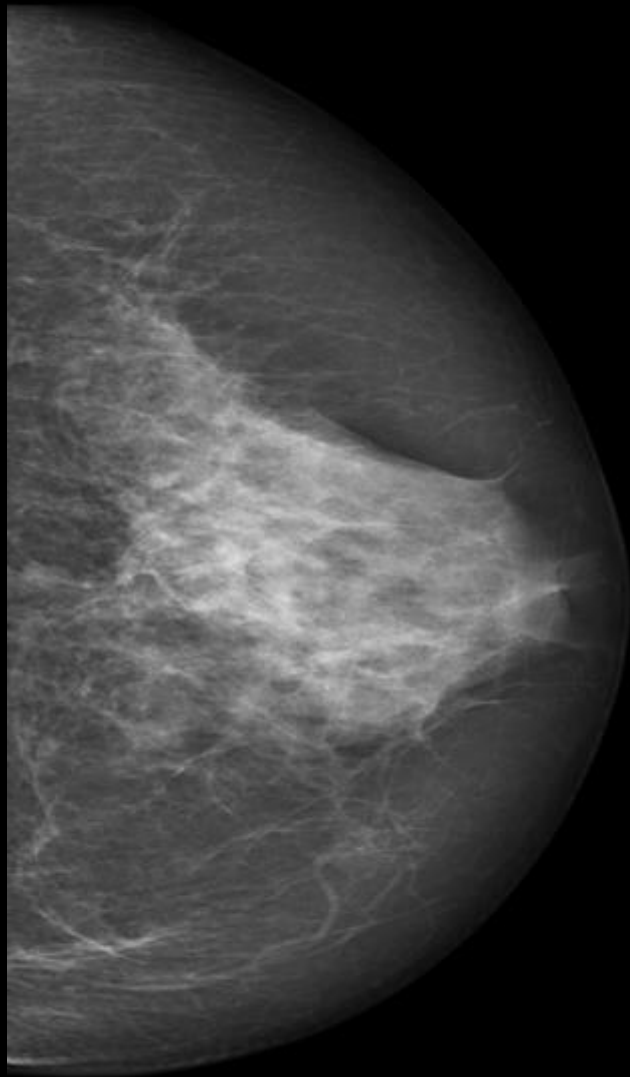


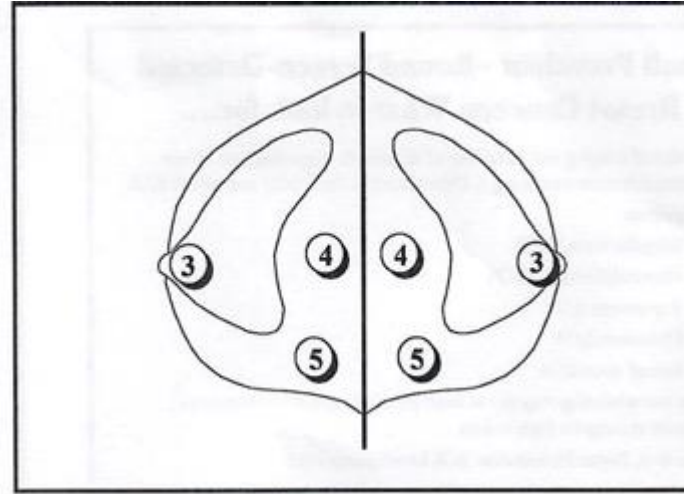
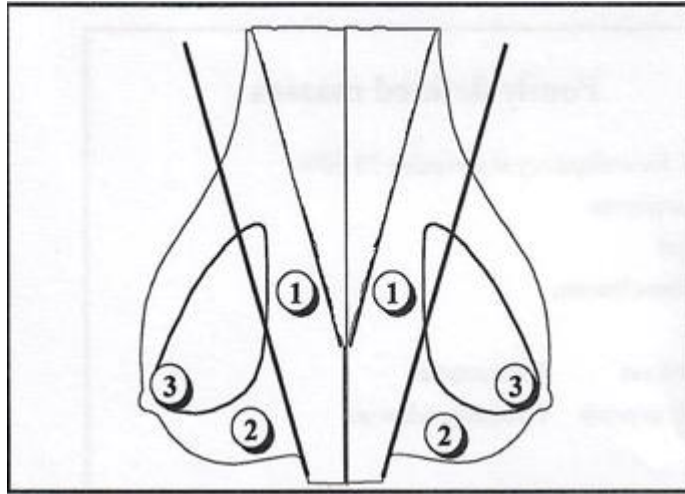
 Universiteit  
Antwerpen

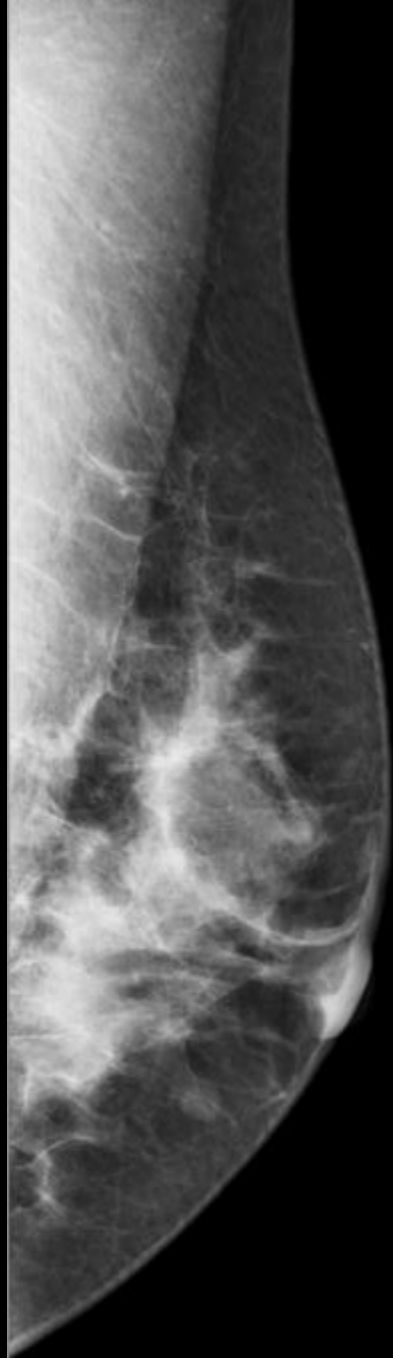
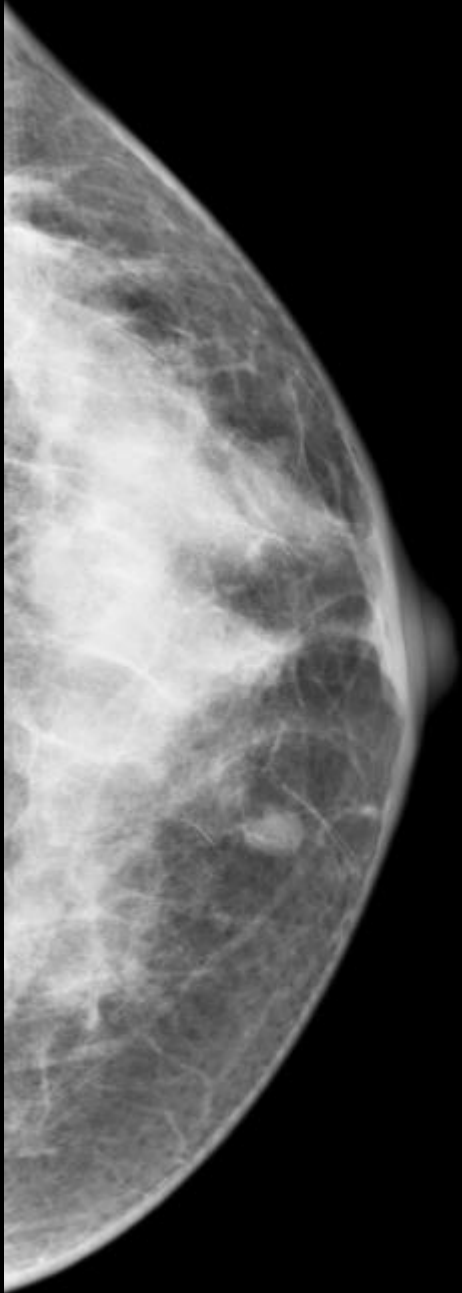


I.D.A. + D.C.I.S.







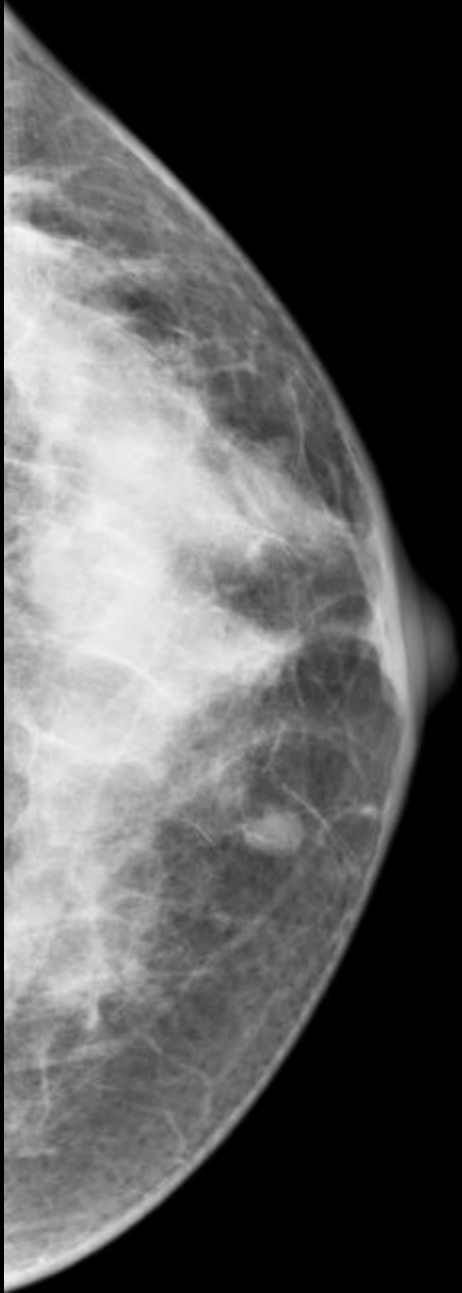
# RECALL ?

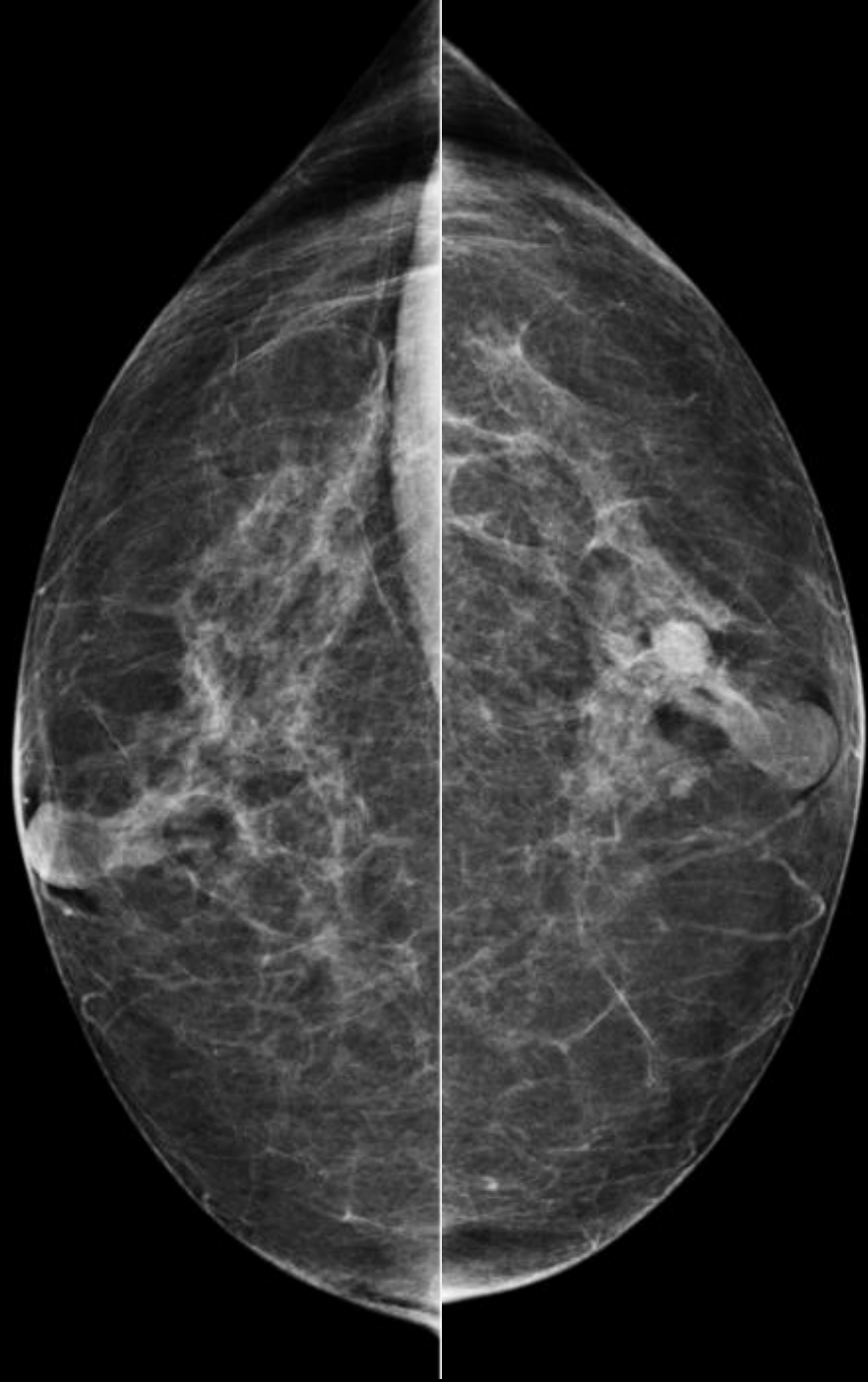
Votes please !

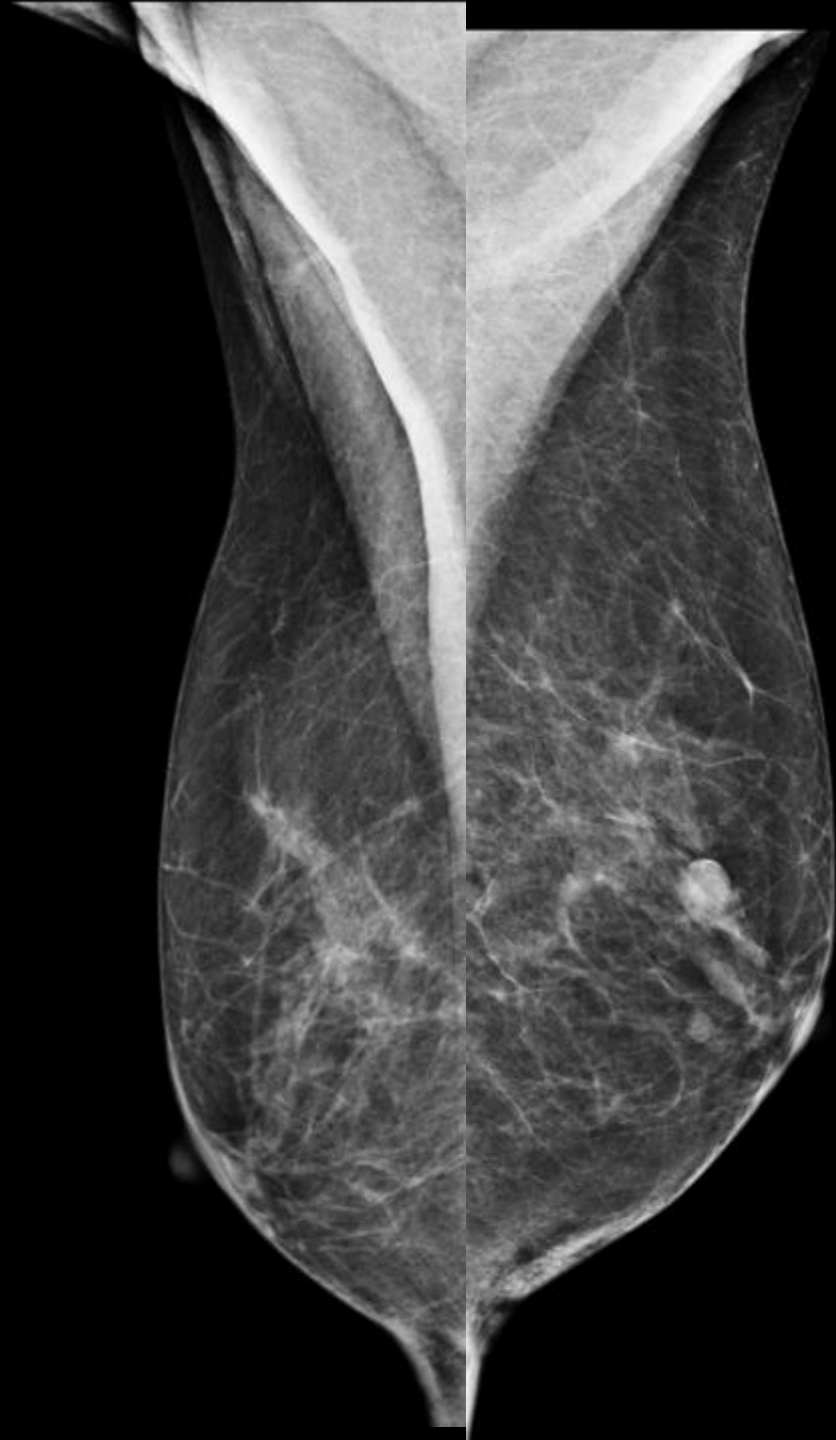

 Universiteit  
Antwerpen











# RECALL ?

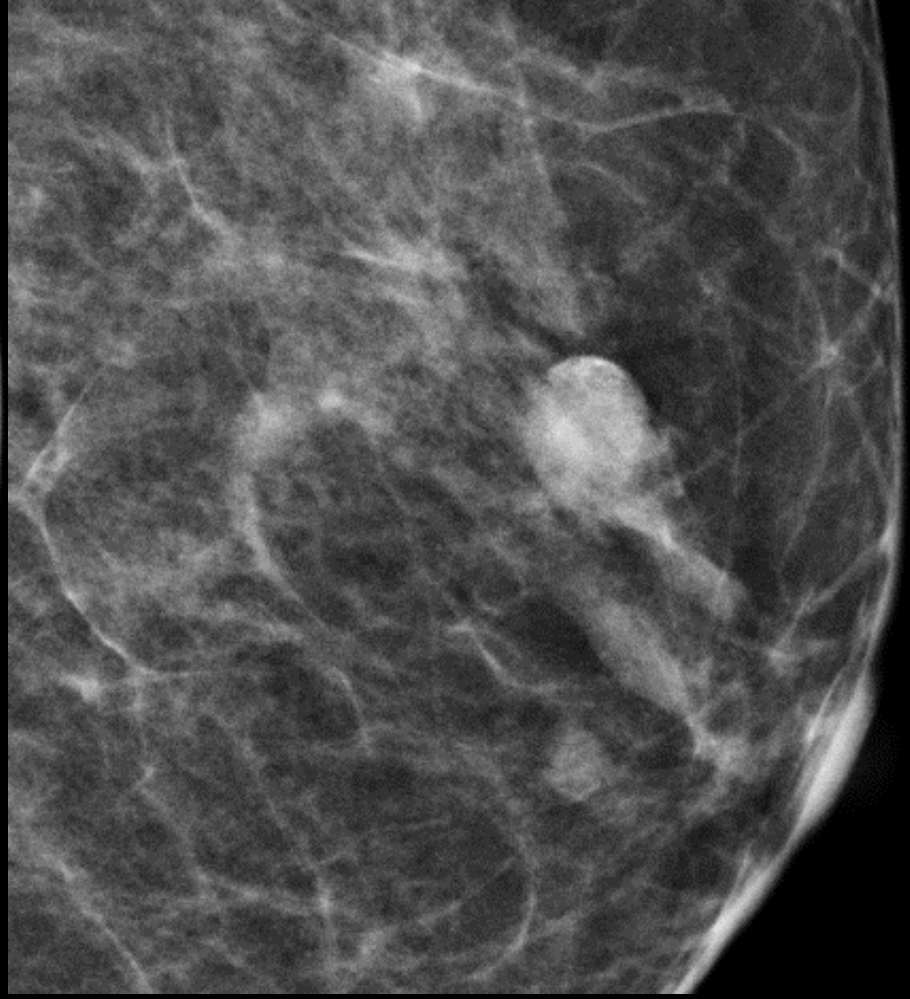
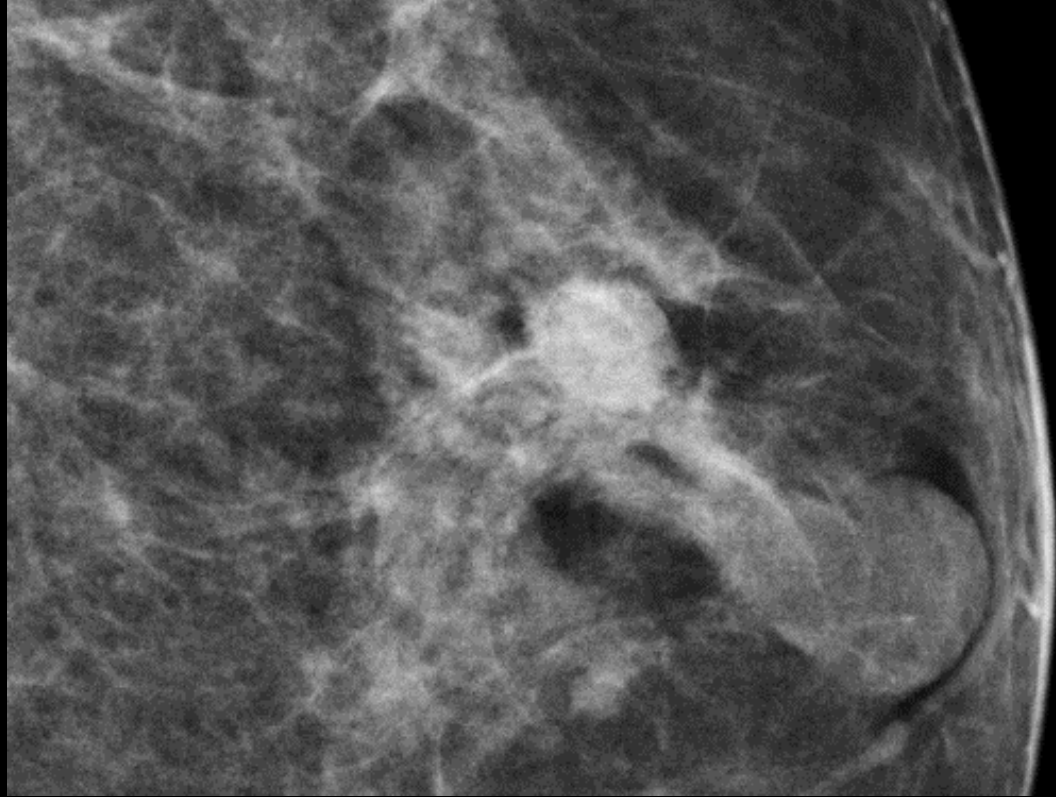
Votes please !



 Universiteit  
Antwerpen

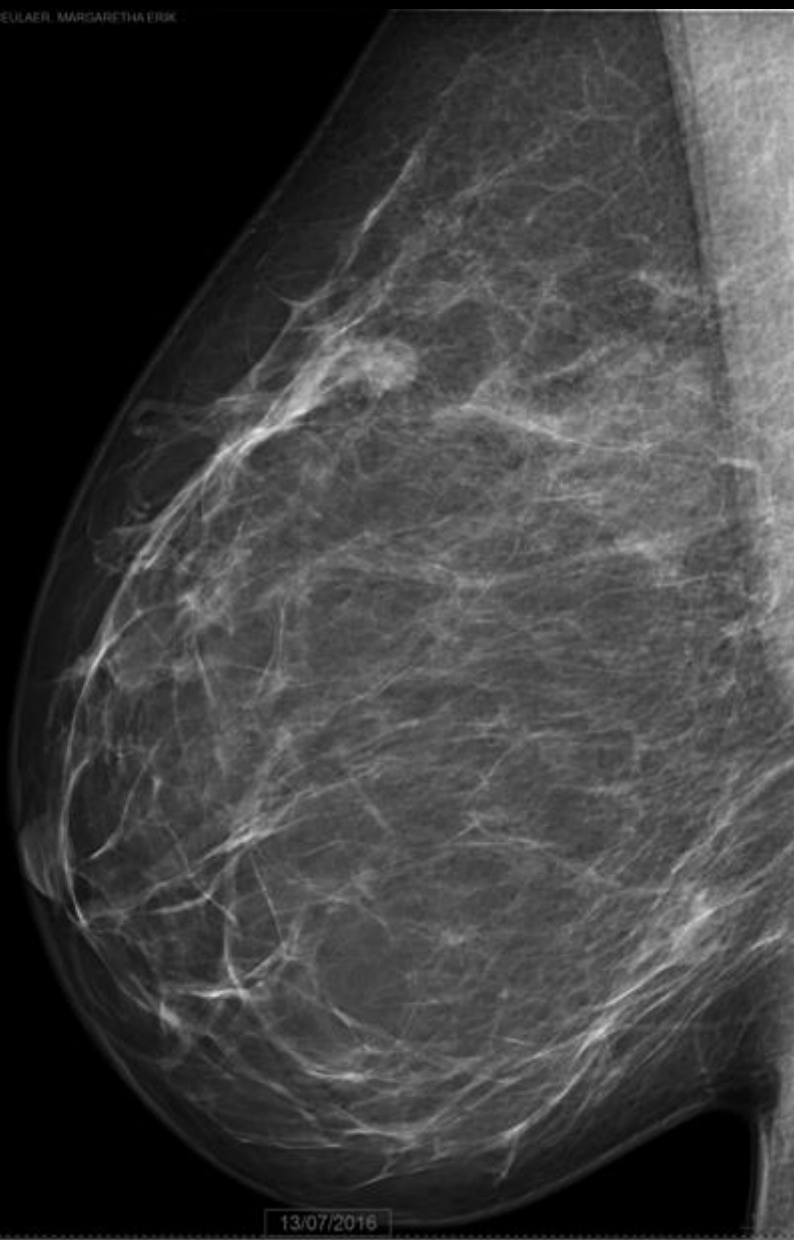






Patient [130270338] DE CELLAER, MARGARETHA ERIK

R  
ML

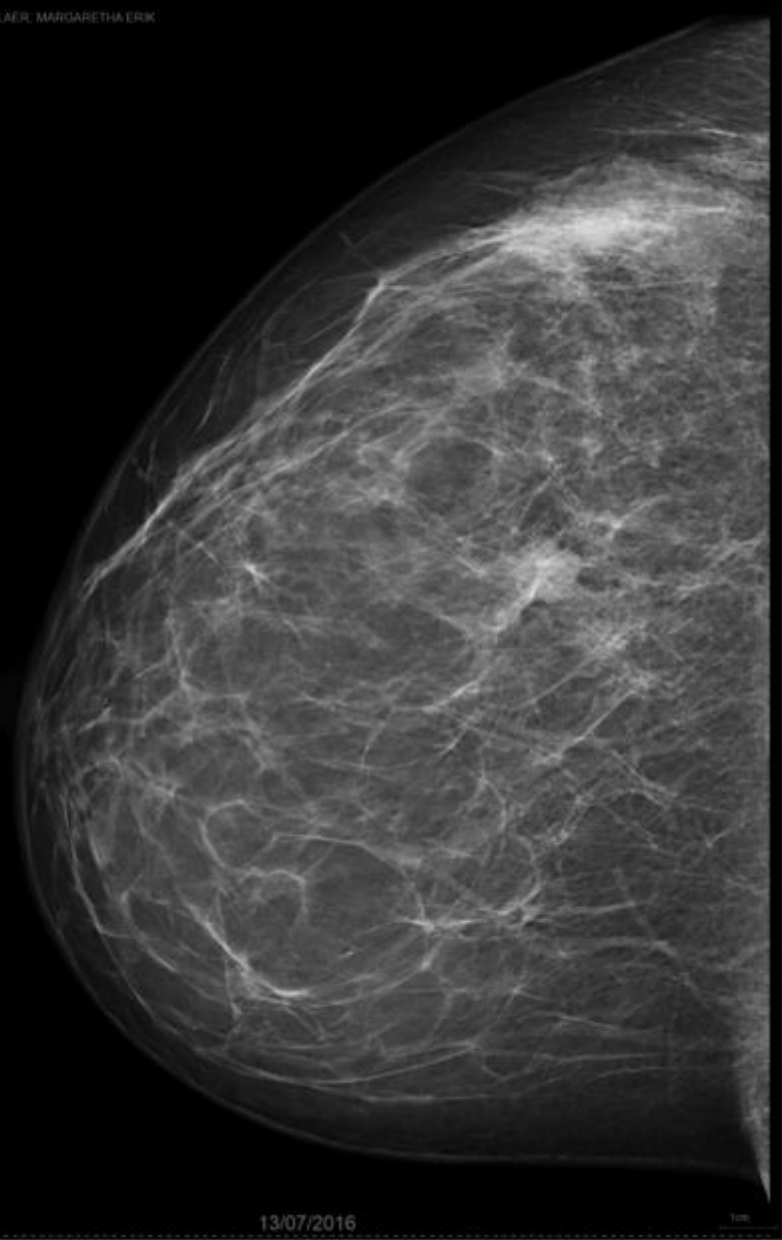


1.1.021  
11.07.2016  
vbramsted

13/07/2016

Patient [130270338] DE CELLAER, MARGARETHA ERIK

R  
CC



1.1.021  
11.07.2016  
vbramsted

13/07/2016

100

# RECALL ?

Votes please !



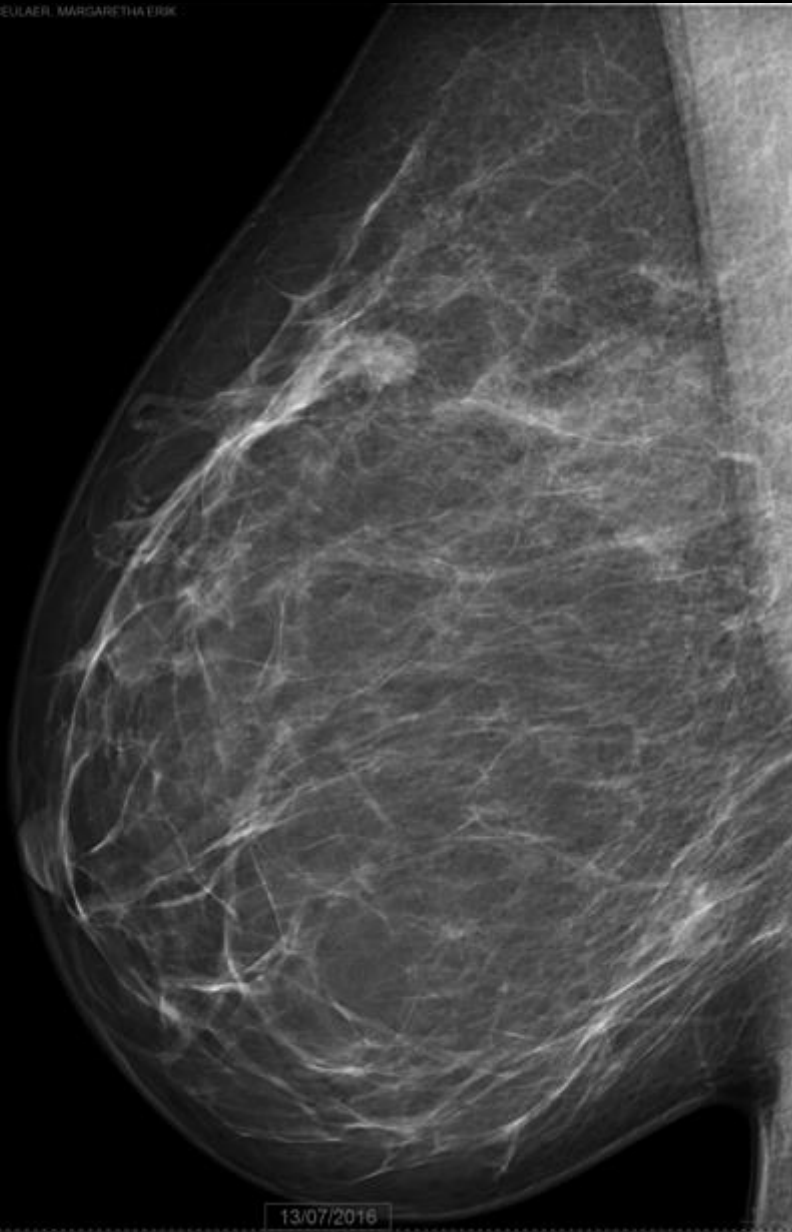
 Universiteit  
Antwerpen



IDA

Patient [130270338] DE CELLAER, MARGARETHA ERIK

R  
ML

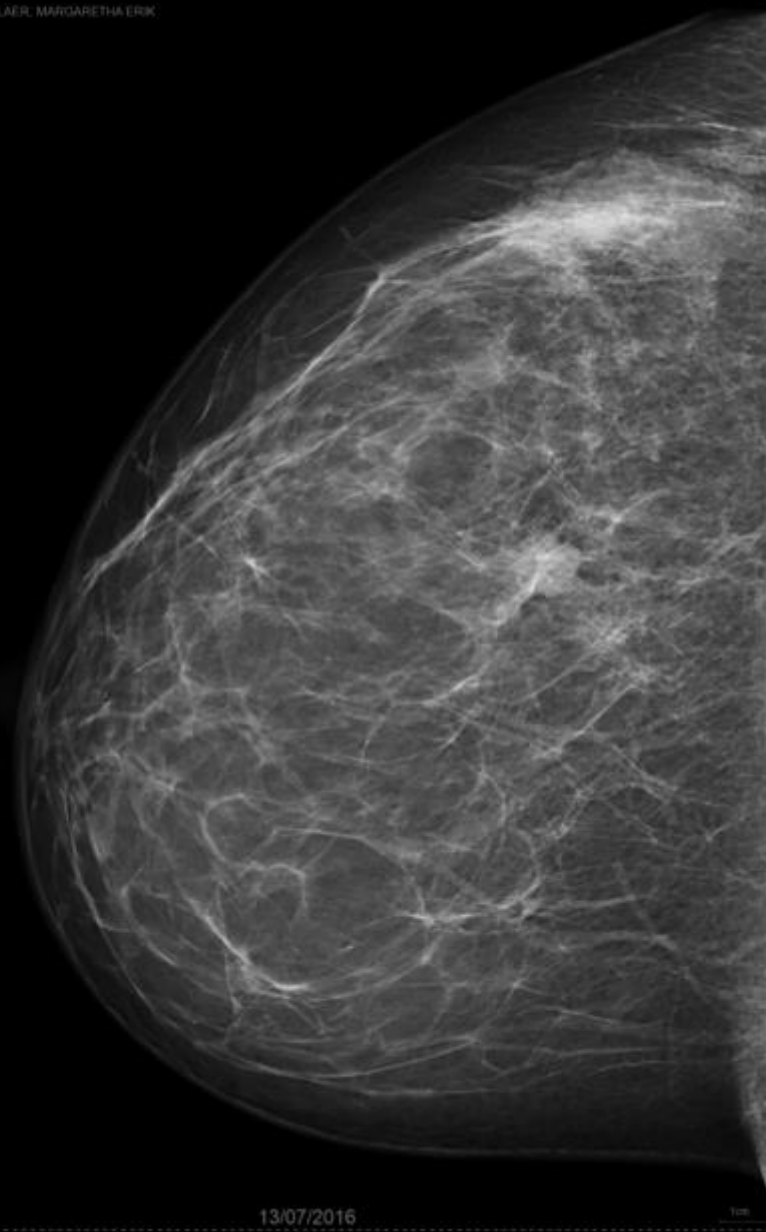


1.1.021  
1.1.87.001  
vbram00000

13/07/2016

Patient [130270338] DE CELLAER, MARGARETHA ERIK

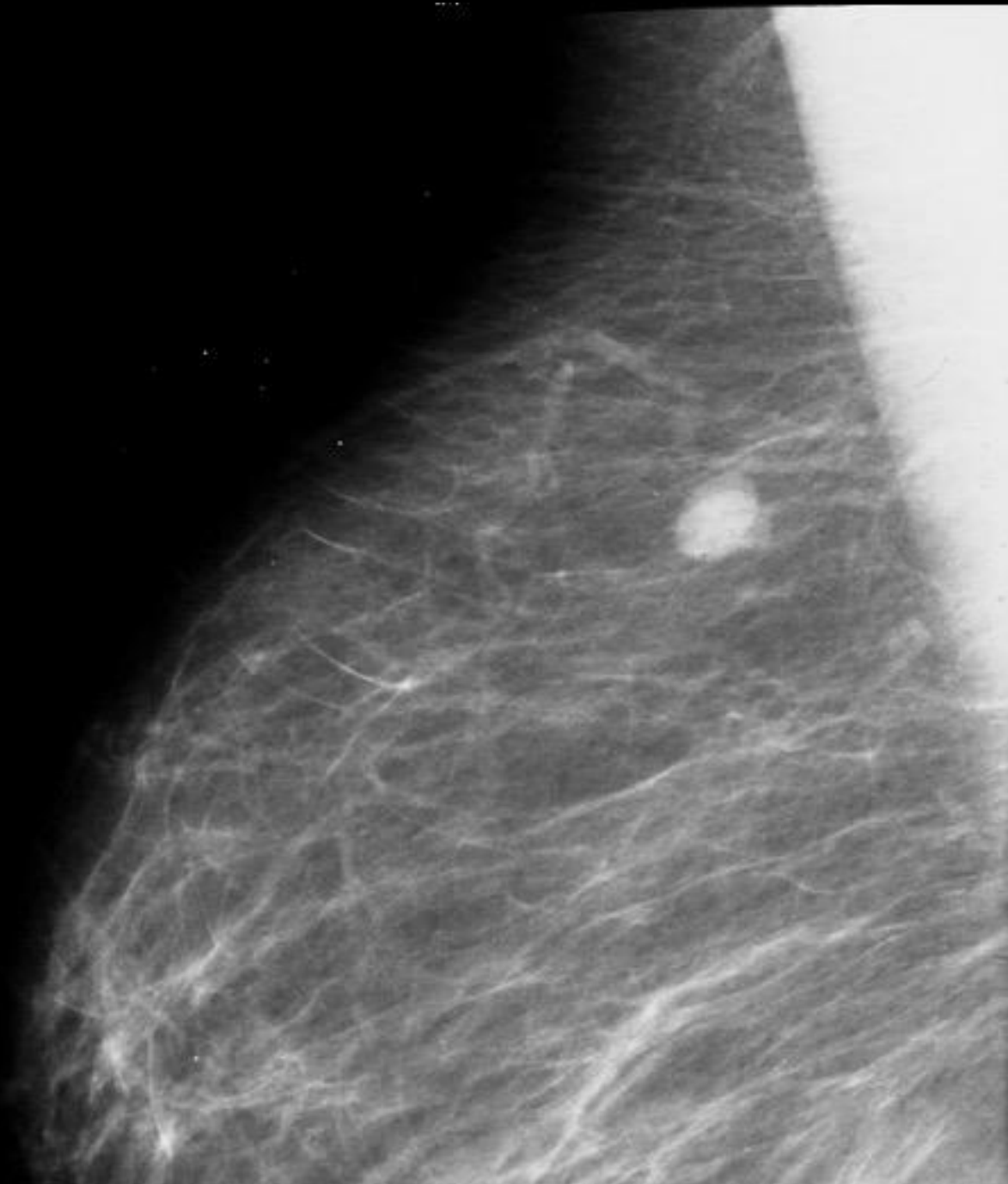
R  
CC



1.1.021  
1.1.87.001  
vbram00000

13/07/2016

100





# RECALL ?

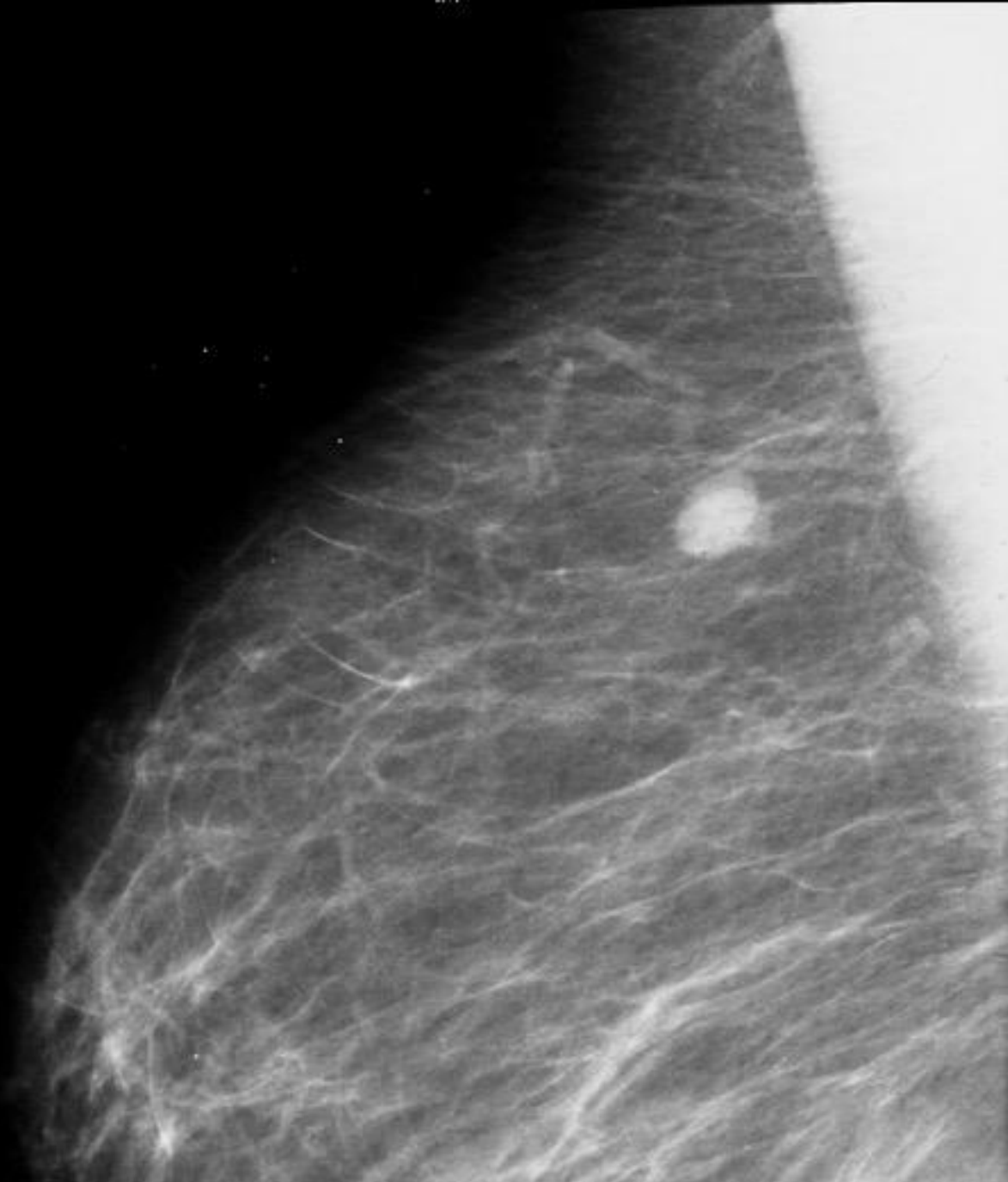
Votes please !

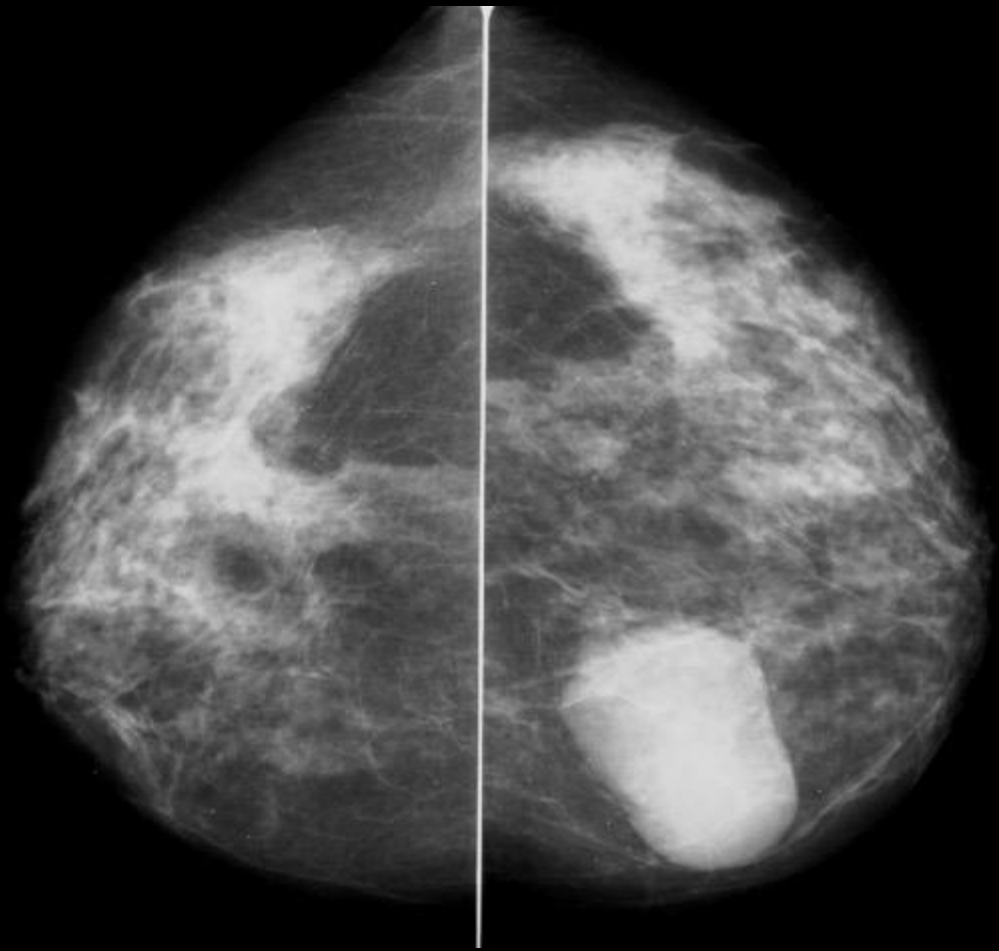


 Universiteit  
Antwerpen



I.D.A.







# RECALL ?

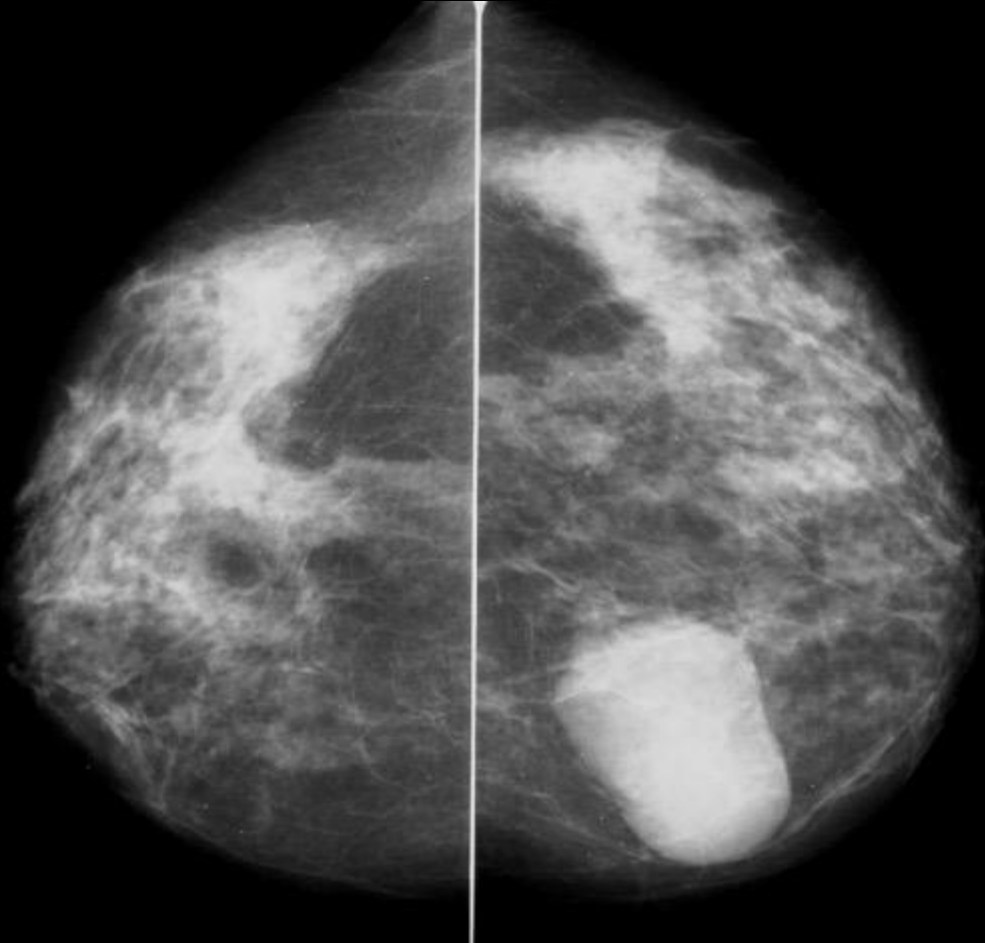
Votes please !



 Universiteit  
Antwerpen



klierweefsel



Minimal sign intervalkankers kunnen misschien niet worden gevonden binnen de normale screening zonder de recall-rate te laten ontsporen.



# Evolutieve goed afgelijnde massa's

Mireille Van Goethem  
Lieve Hufkens

G. Mortier - I. Verslegers - A. Van Hoyweghen  
Prof. dr. P. Parizel (head of department)



# Recall glad afgelijnde massa's

Als:

- Niet zeker (75%) goed aflijnbaar
- Nieuwe massa (1)
- Goed afgelijnd maar volumetoename
- Gelokaliseerd buiten het glandulaire weefsel



# Recall glad afgelijnde massa's

Slechts 4 % van de screen-detected kankers zijn scherp afgelijnde massa's. (PPV 3.1% 38/1213)

- 68 % waren dense massa's
- 11 % halo-teken
- 29 % slechts op 1 opname (meestal niet op CC)
- **75 % waren nieuw en**
- **25 % toonden volumetoename**

Taylor C., Cooke; Round mass lesions recalled from screening: a retrospective analysis of round mass cancers. Guilford 2004.





# Gemiste kankers

Radiology. 1992 Sep;184(3):613-7.

## Analysis of cancers missed at screening mammography.

Bird RE1, Wallace TW, Yankaskas BC.

- Kennis van de karakteristieken van gemiste kankers is een waardevolle hulp om de sensitiviteit van mammografie te verhogen.
- 320 kankers, 77 gemist.
- Vergelijk gemiste met 121 gedetecteerde:
  - Gemiste kankers toonden zich meer als een evolutieve opaciteit als indicatie voor kanker ( $P = .005$ )





# Misinterpretatie

- Asymmetrie
- Microverkalkingen
- Enkel zichtbaar op 1 opname
- Lage densiteit
- Traag groeiende massa's > oudere vorige



# Onscherp afgelijnde massa

## Recall behalve

- Indien gekend en onveranderd in vorige rondes
- Indien benigne biopsie

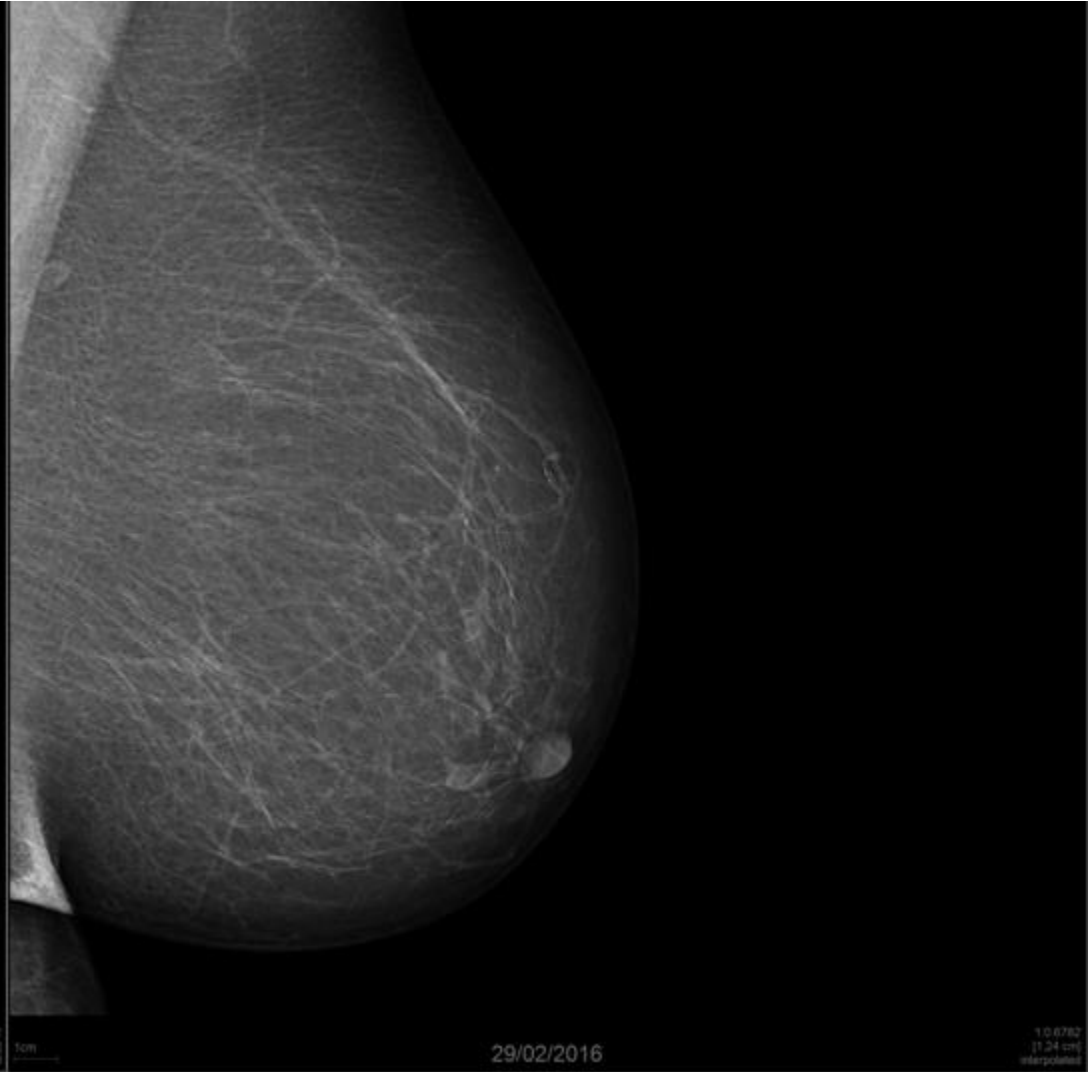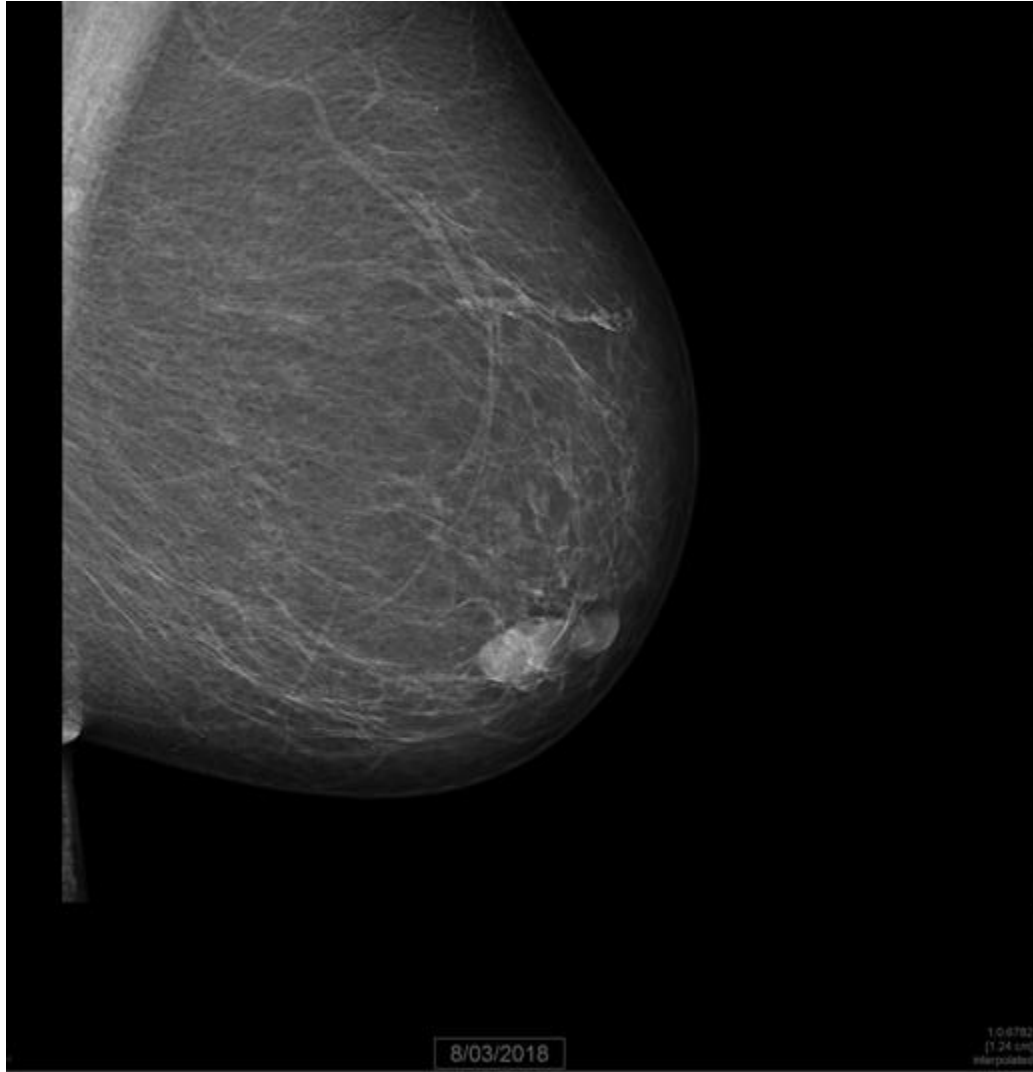


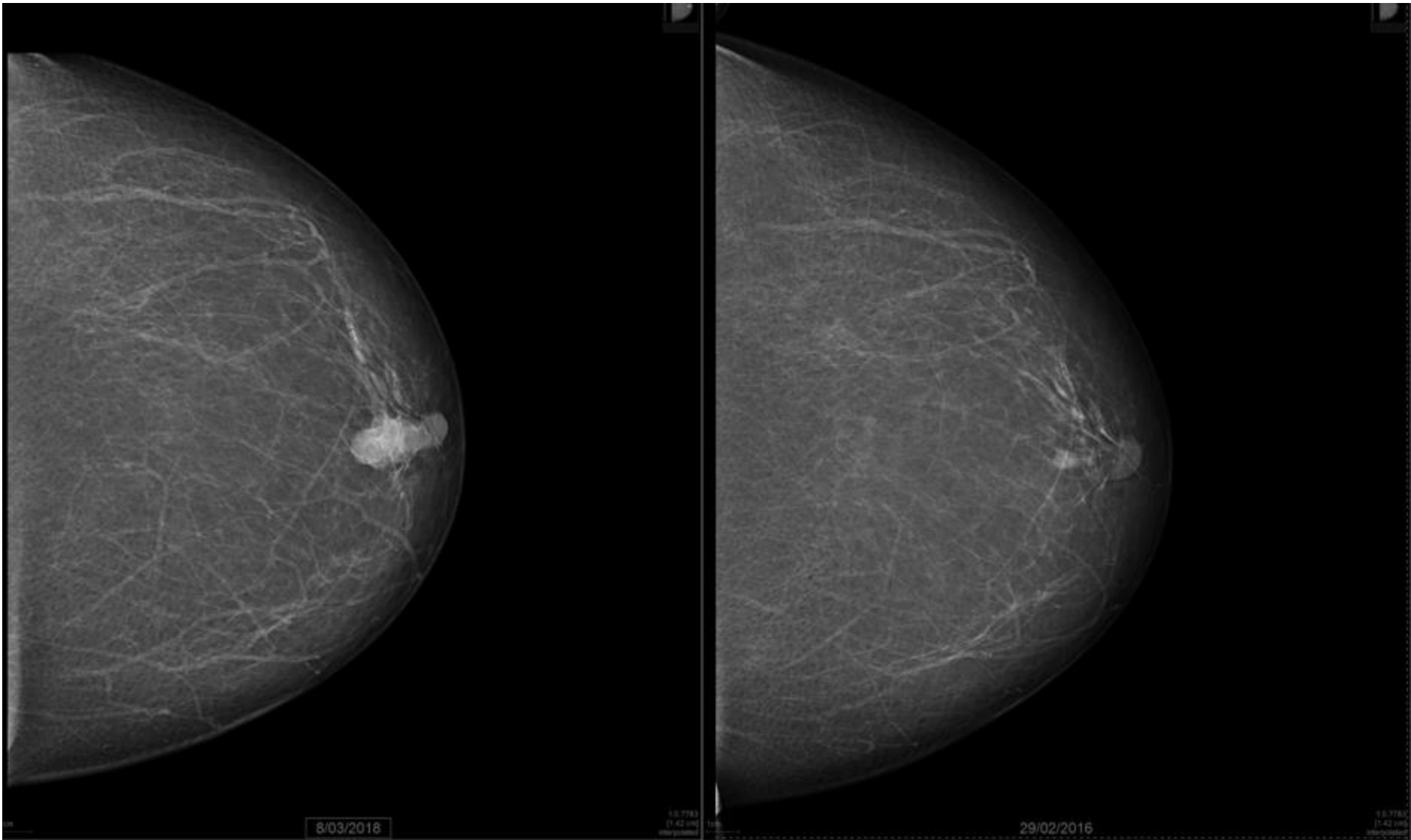
# Evolutieve asymmetrie

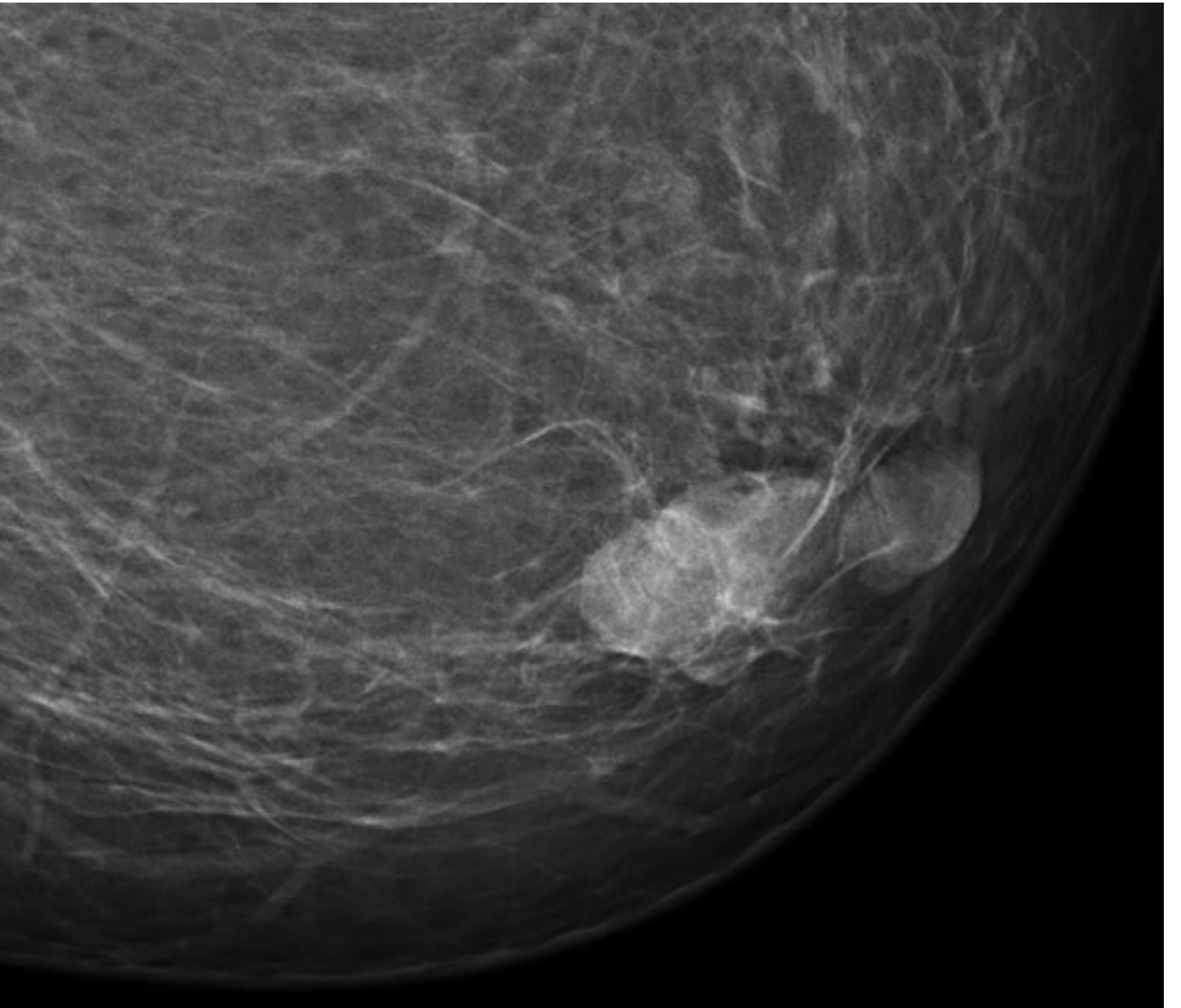
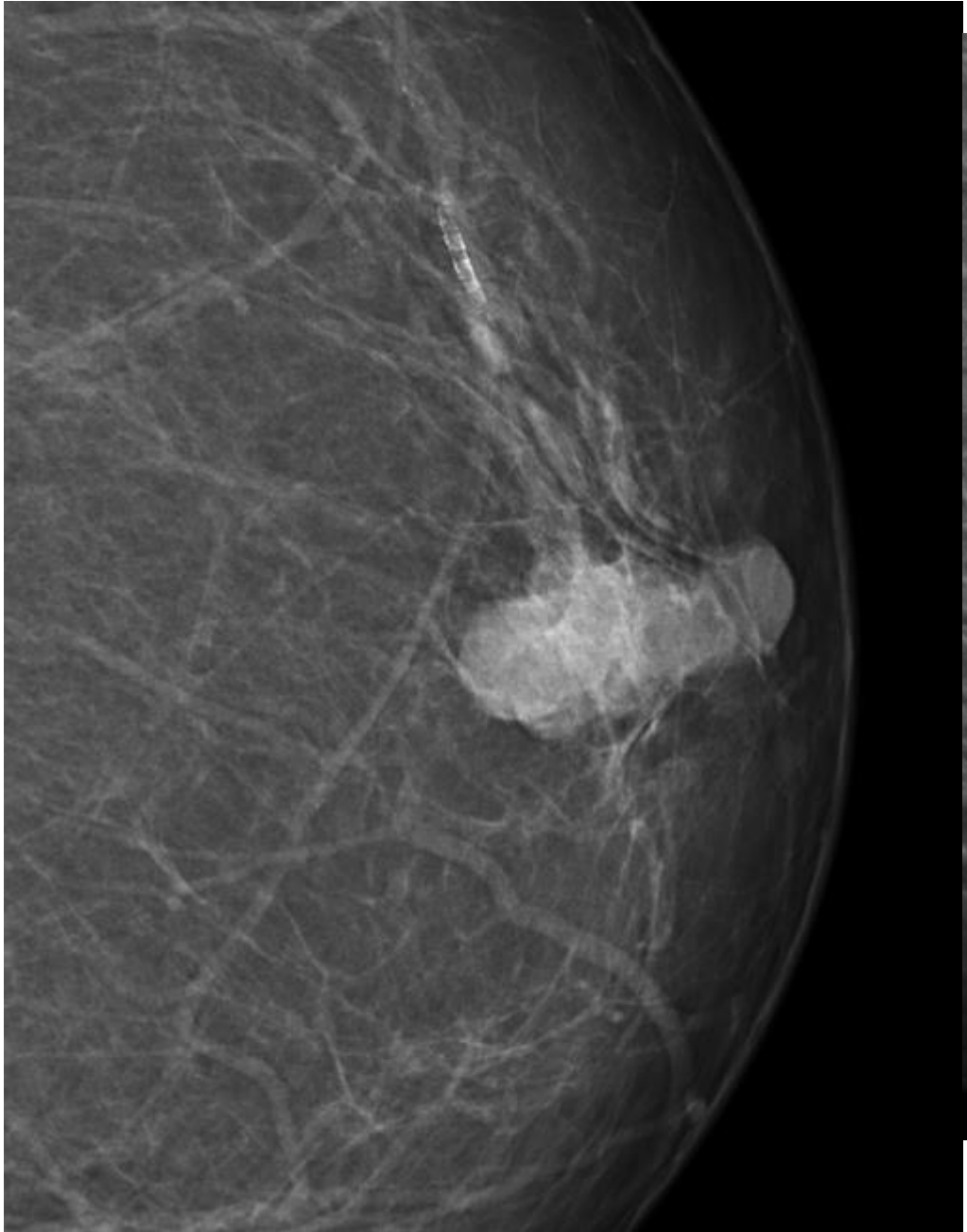
Leung en Sickles 2007

- Focale asymmetrie die nieuw is of groter is geworden.
- In screening: 12.8% maligne
- Subtiel > vergelijken met oudere







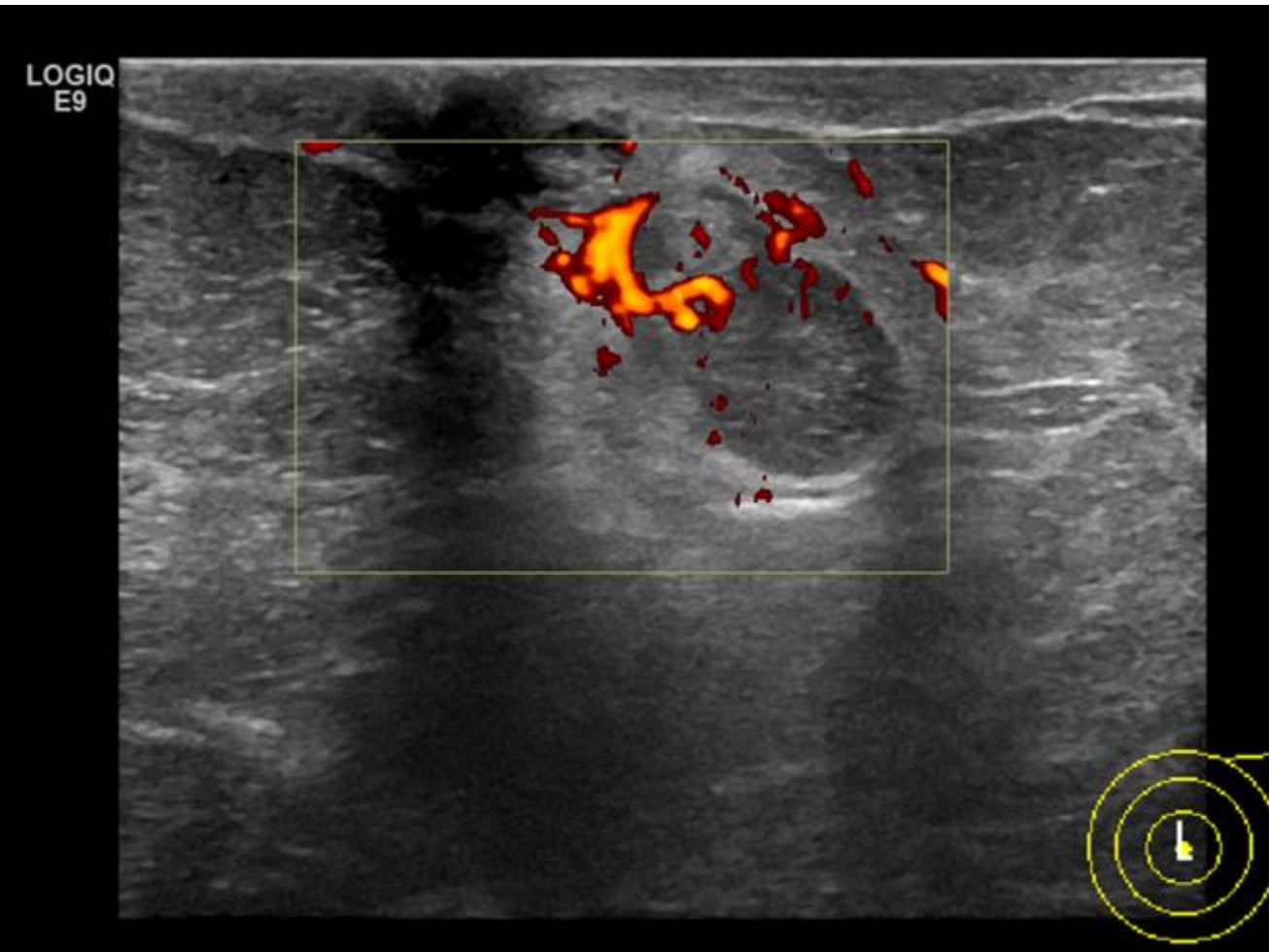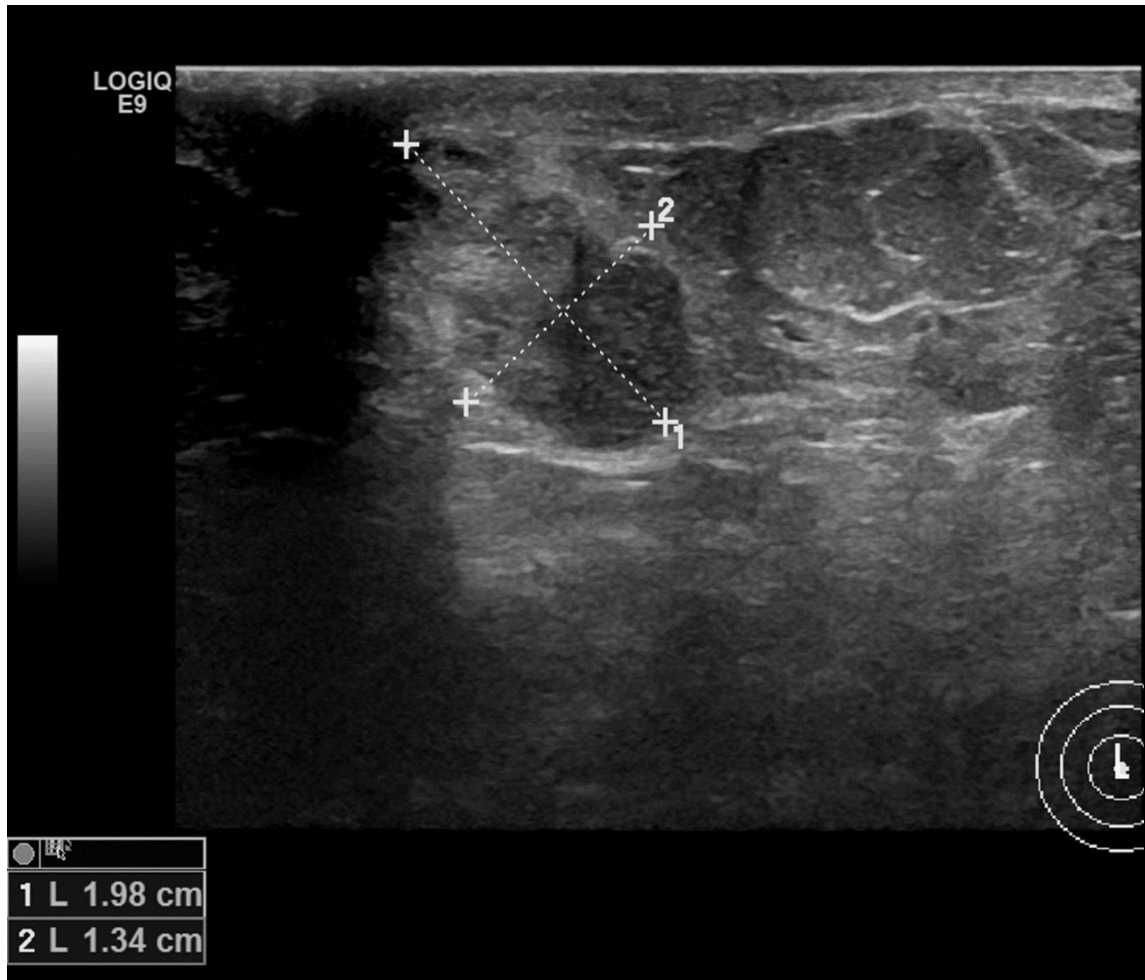


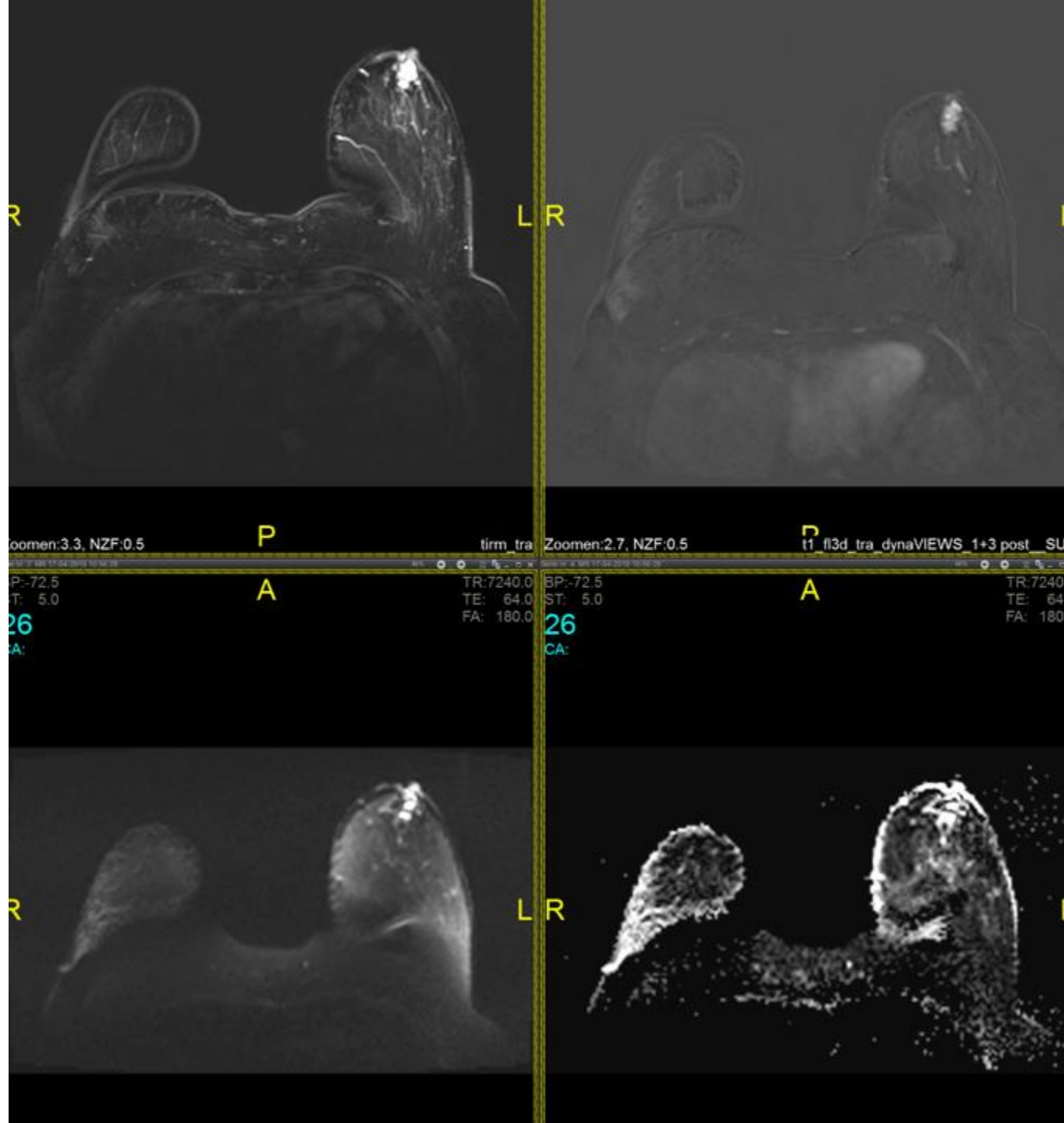
# Recall?

- Ja
- Nee

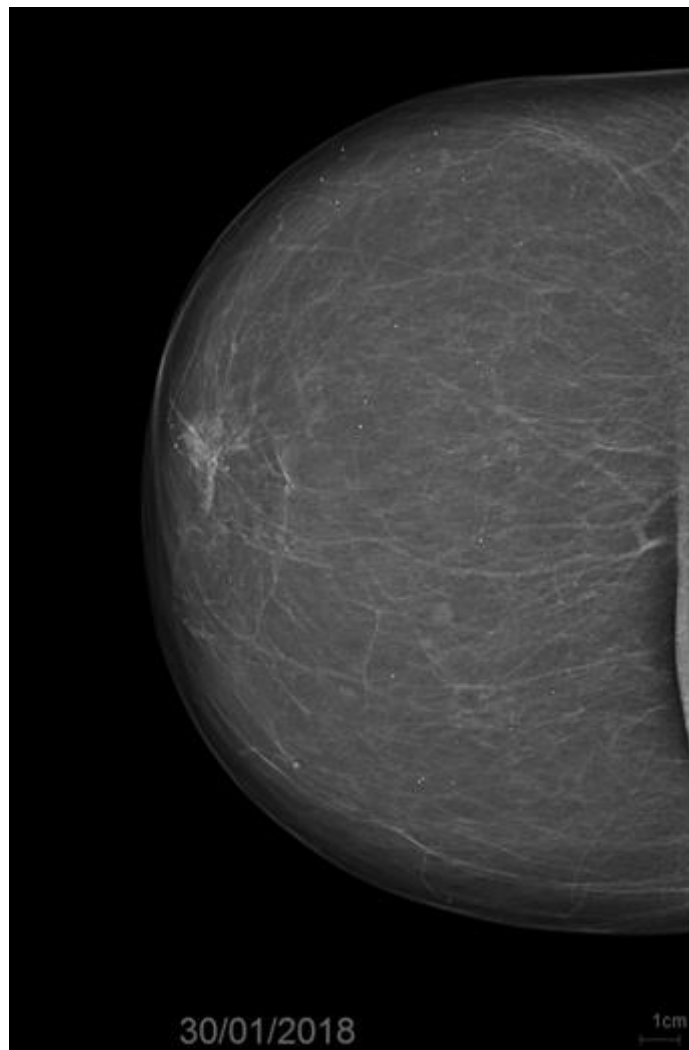
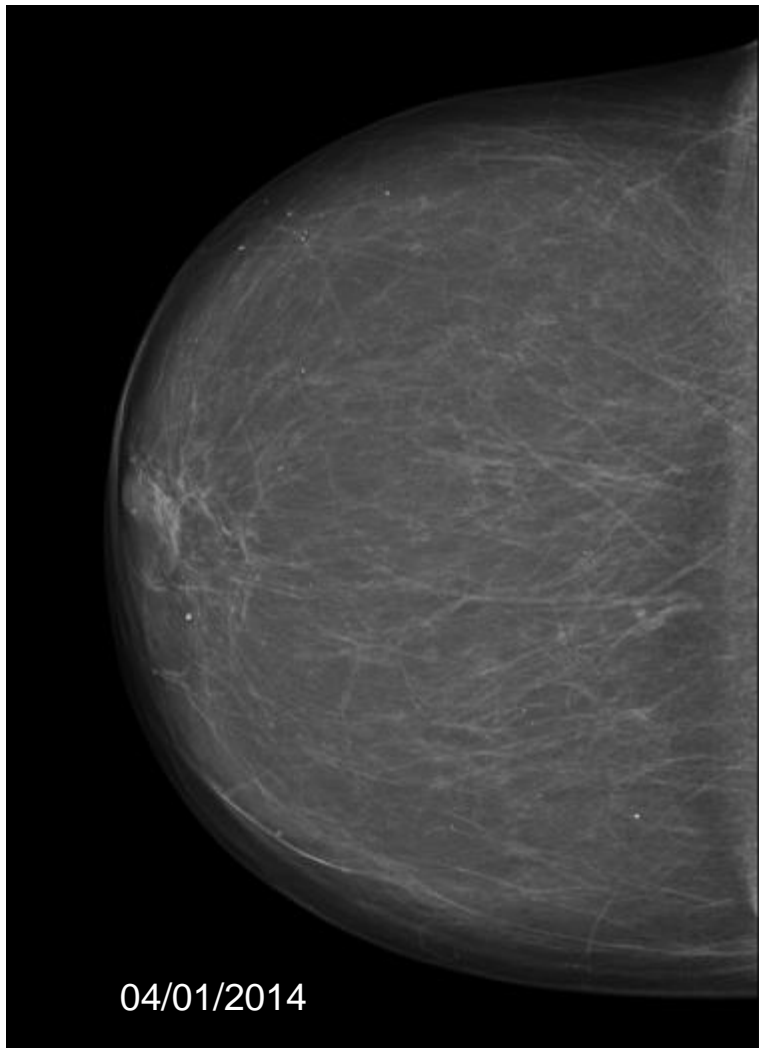


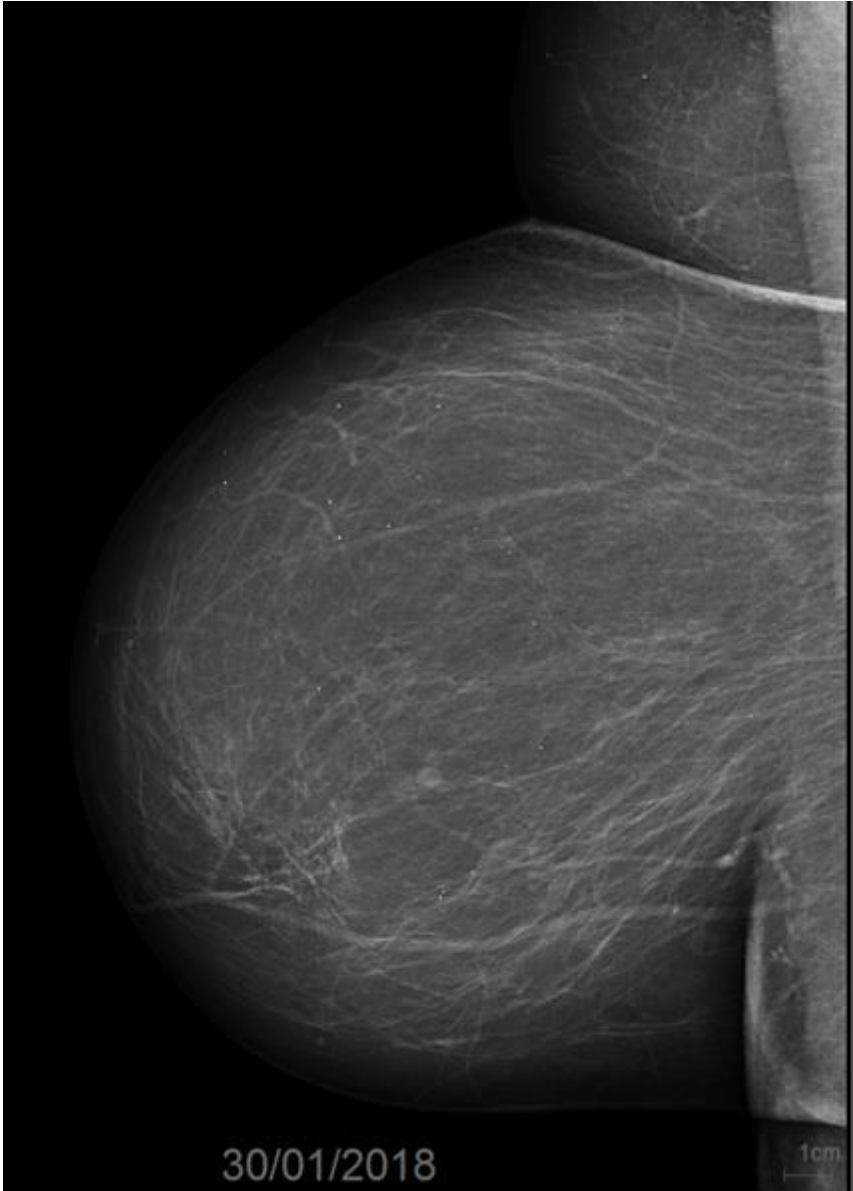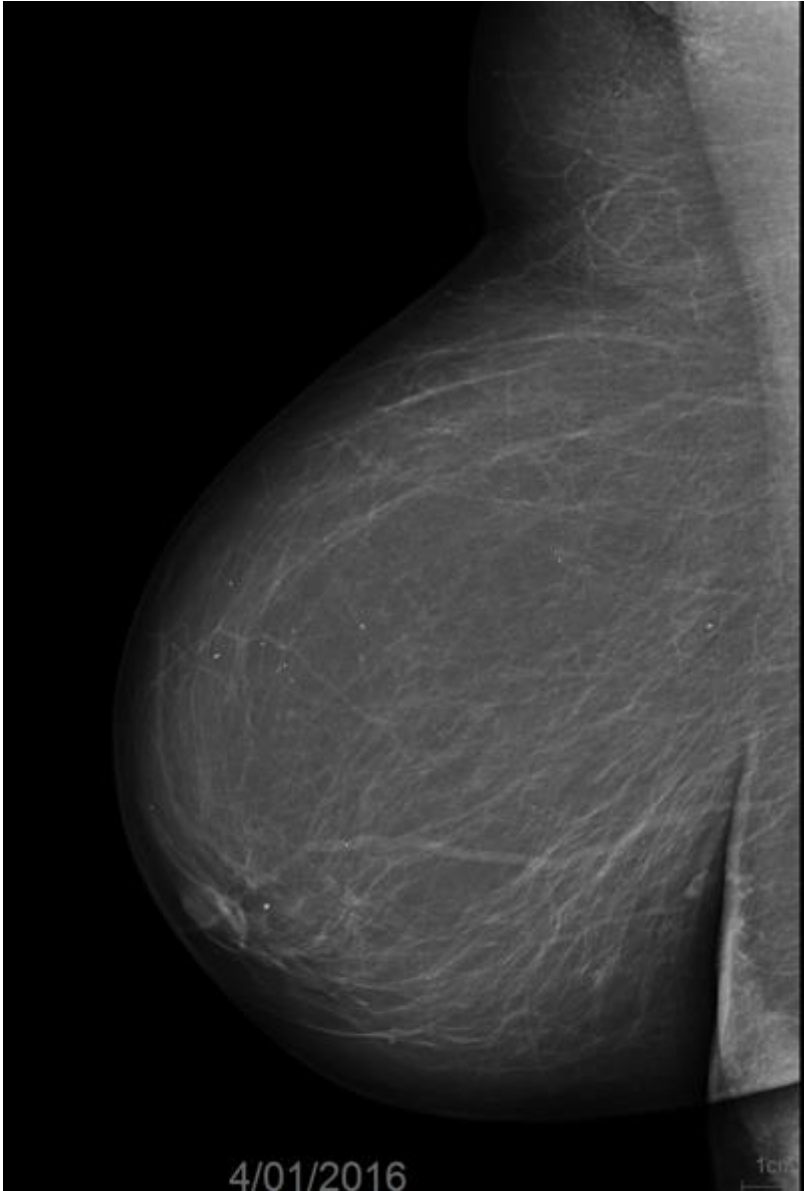


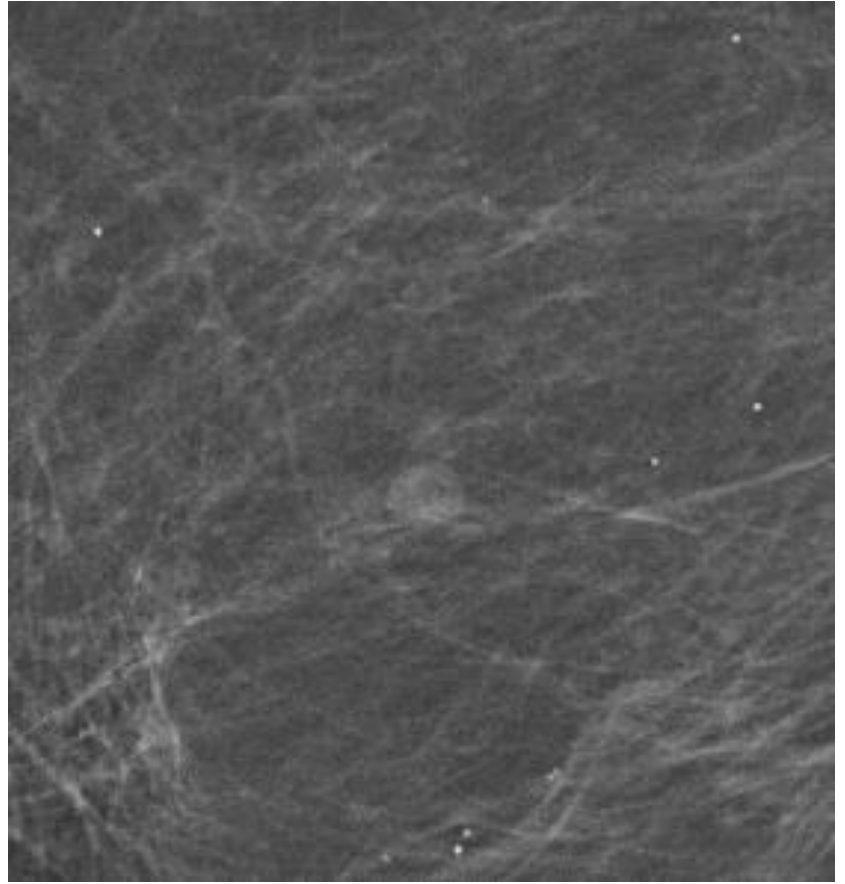
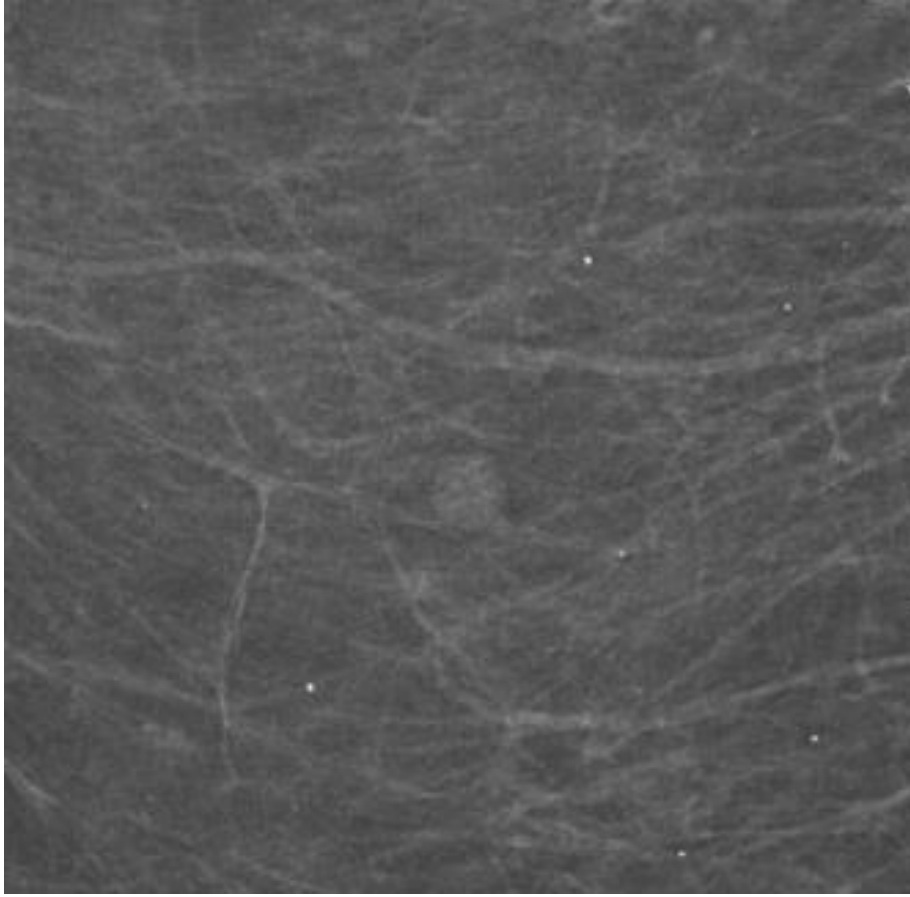




Invasief  
adenocarcinoom, NST met  
focaal  
mucineuze  
differentiatie,  
graad 1 volgens  
Nottingham





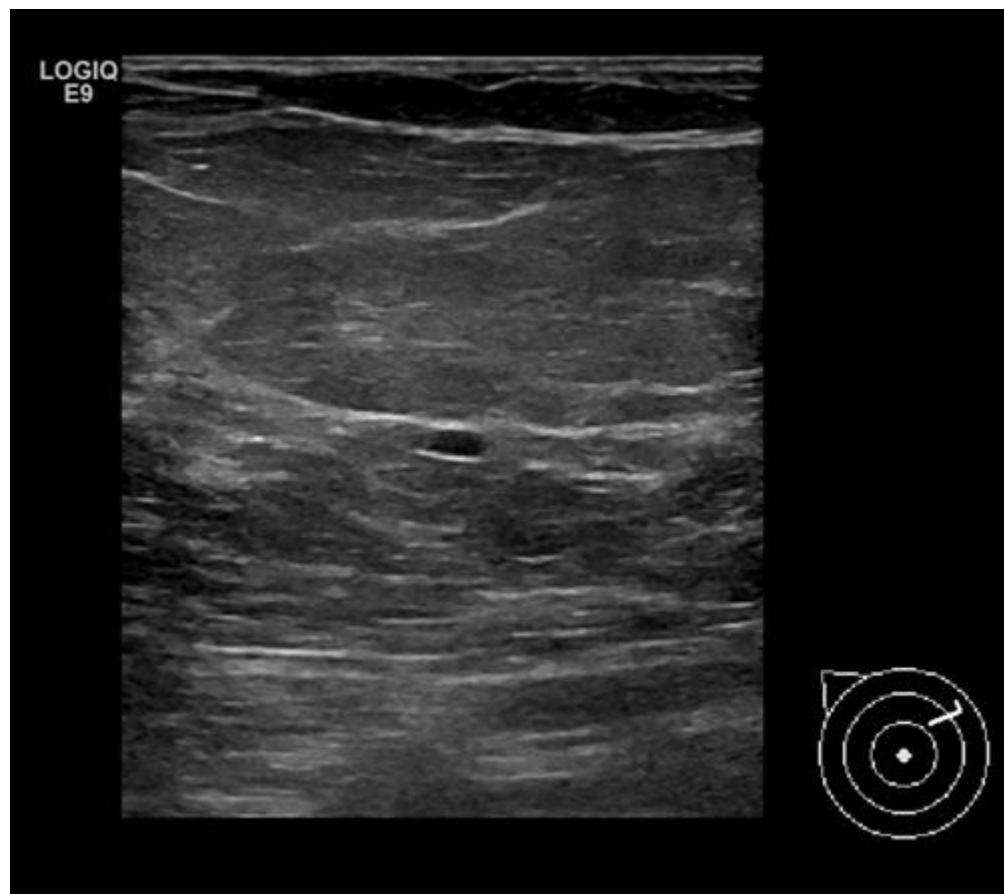
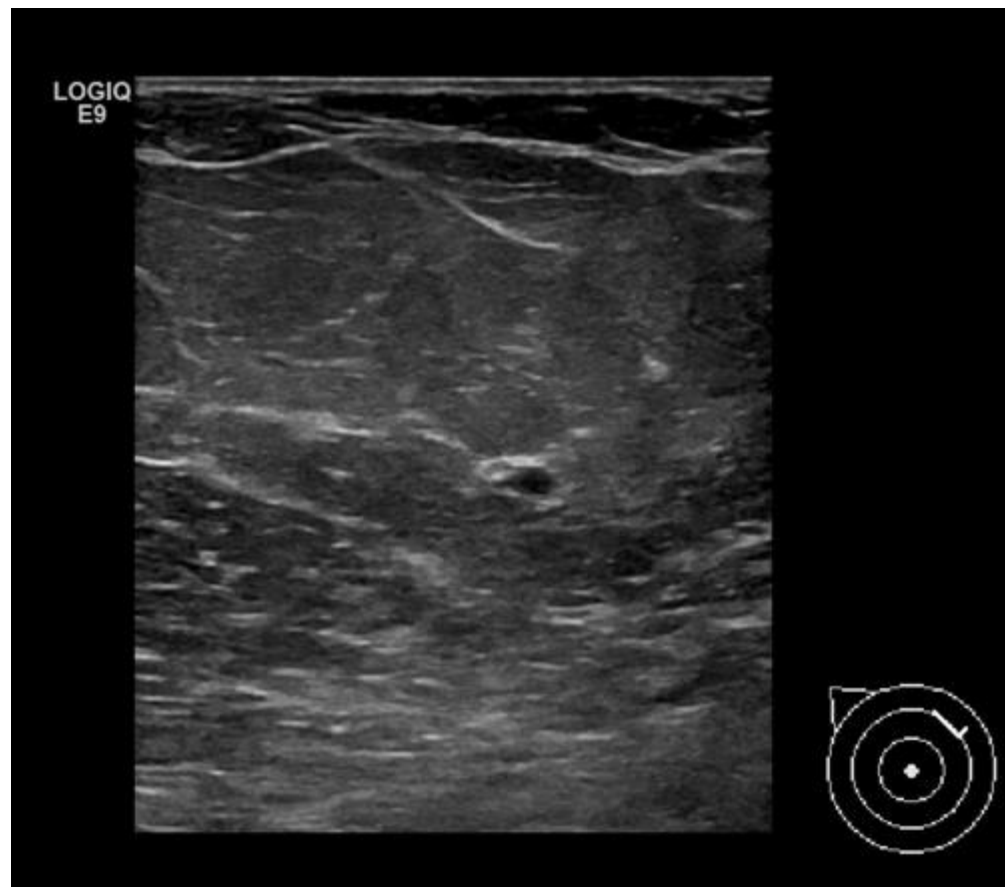


# Recall?

- Ja
- Nee

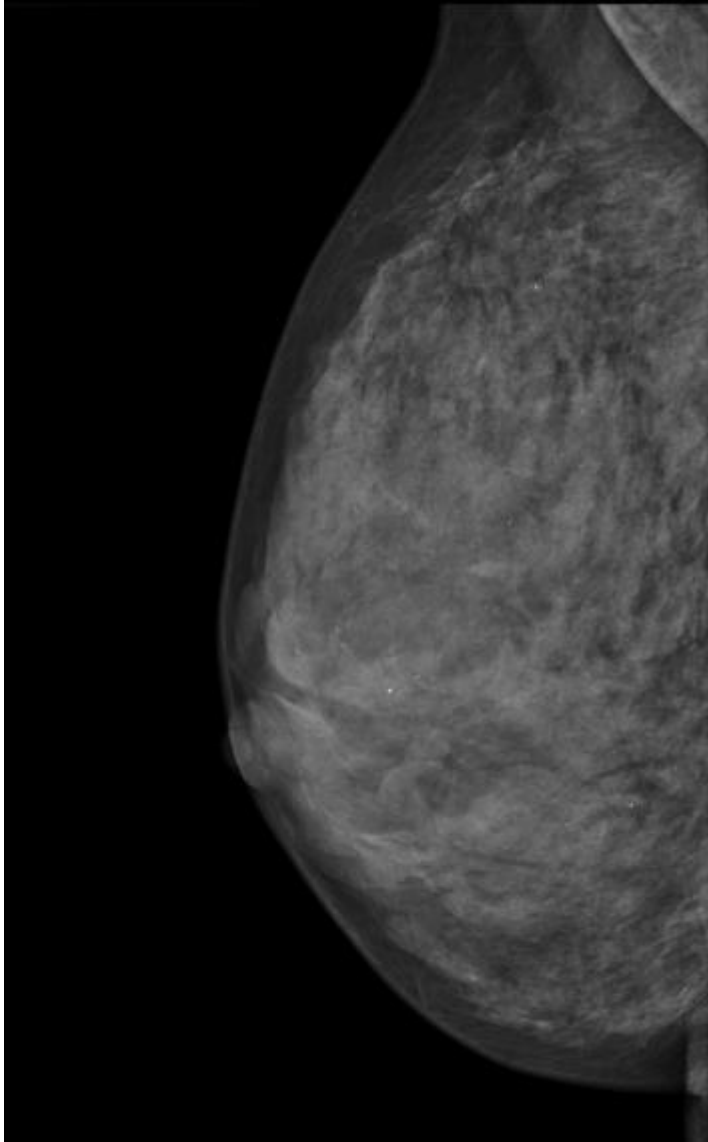




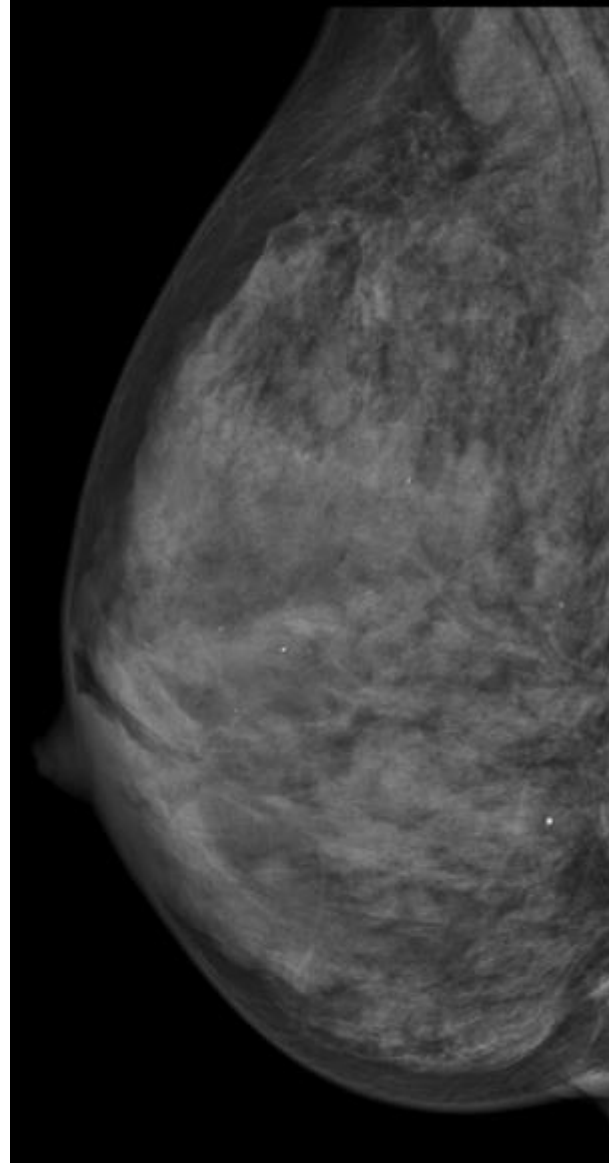




2012



2014

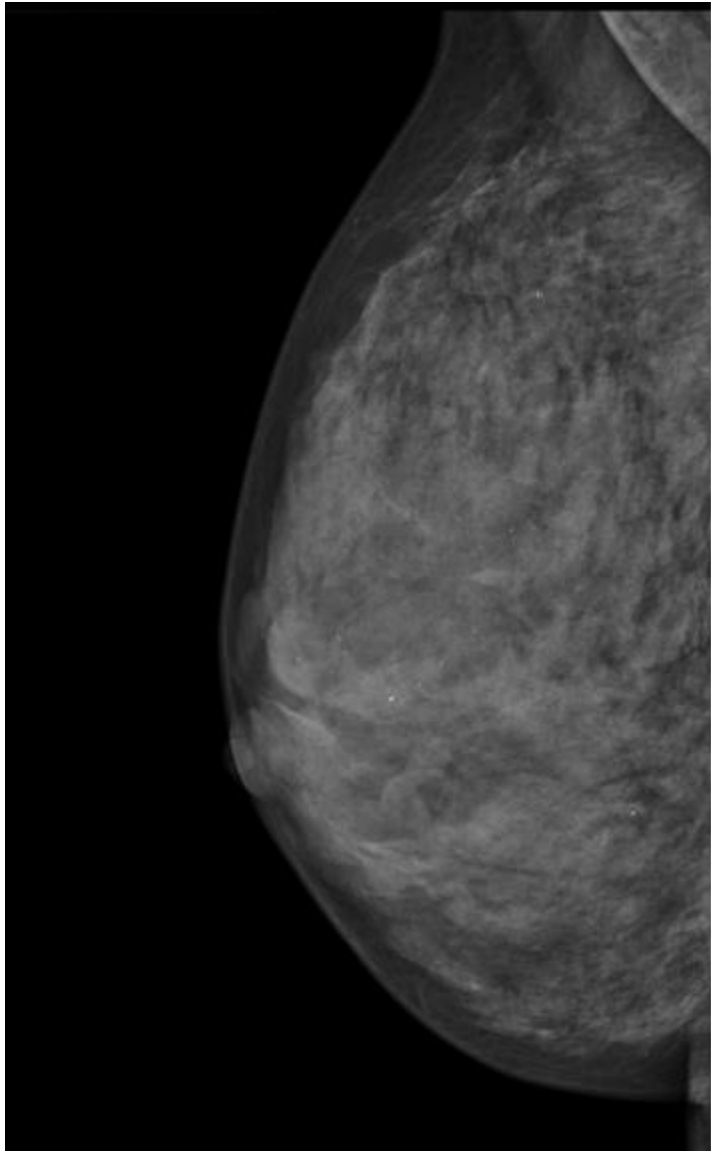


# Recall?

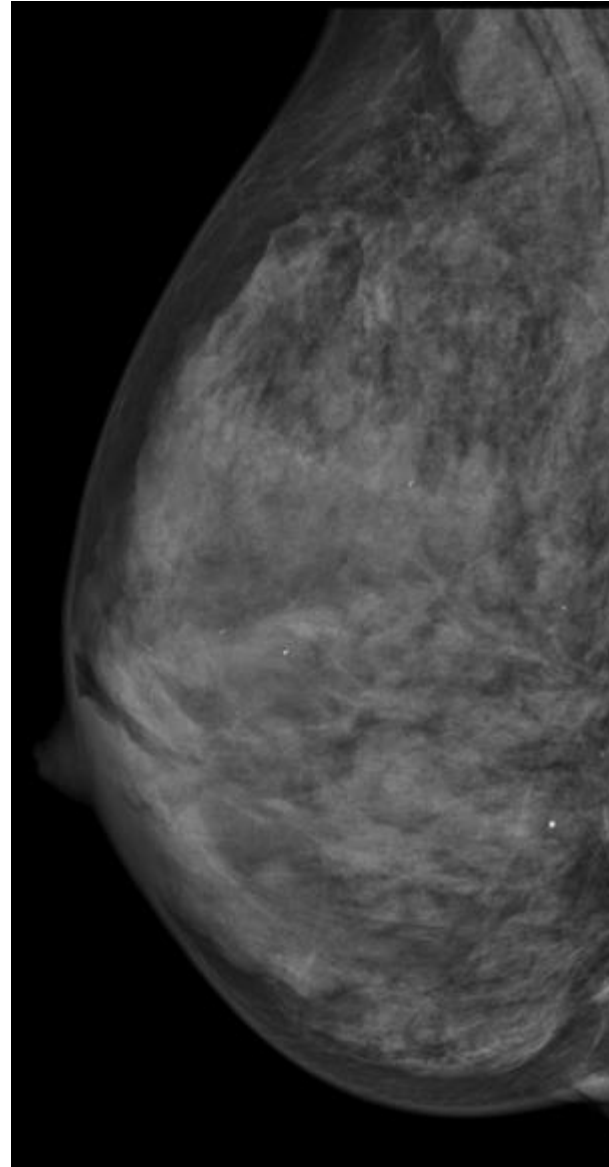
- Ja
- Nee



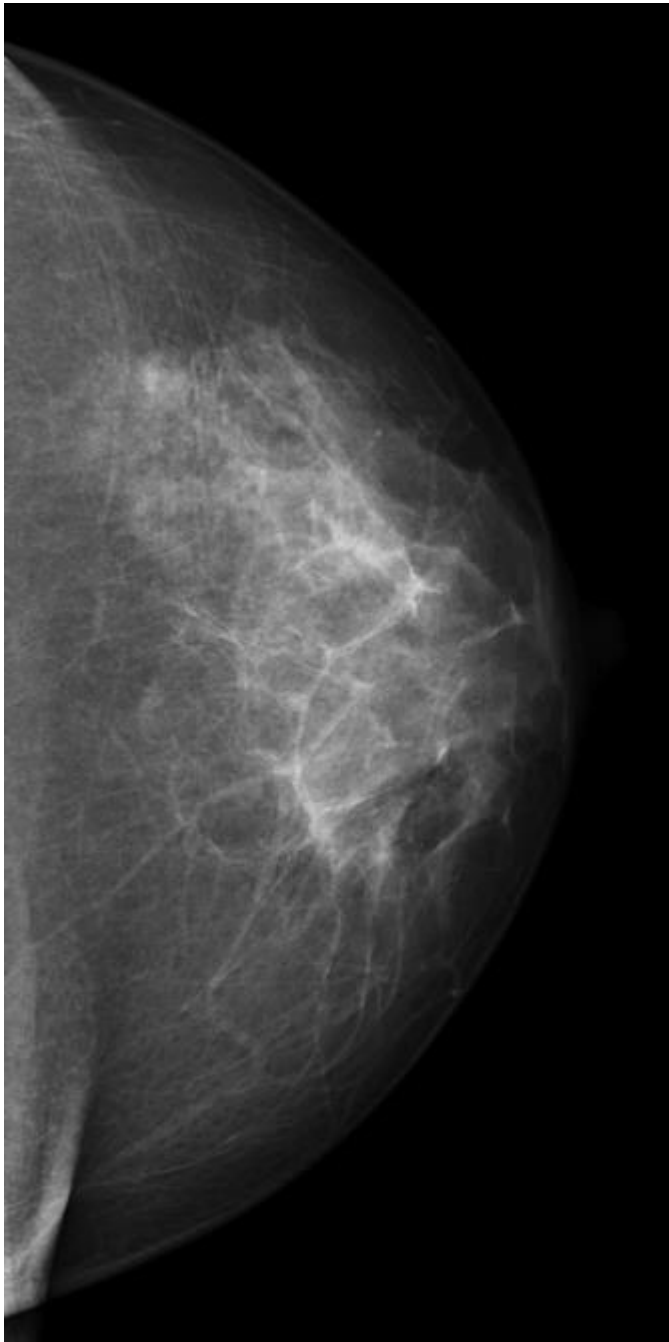
2012



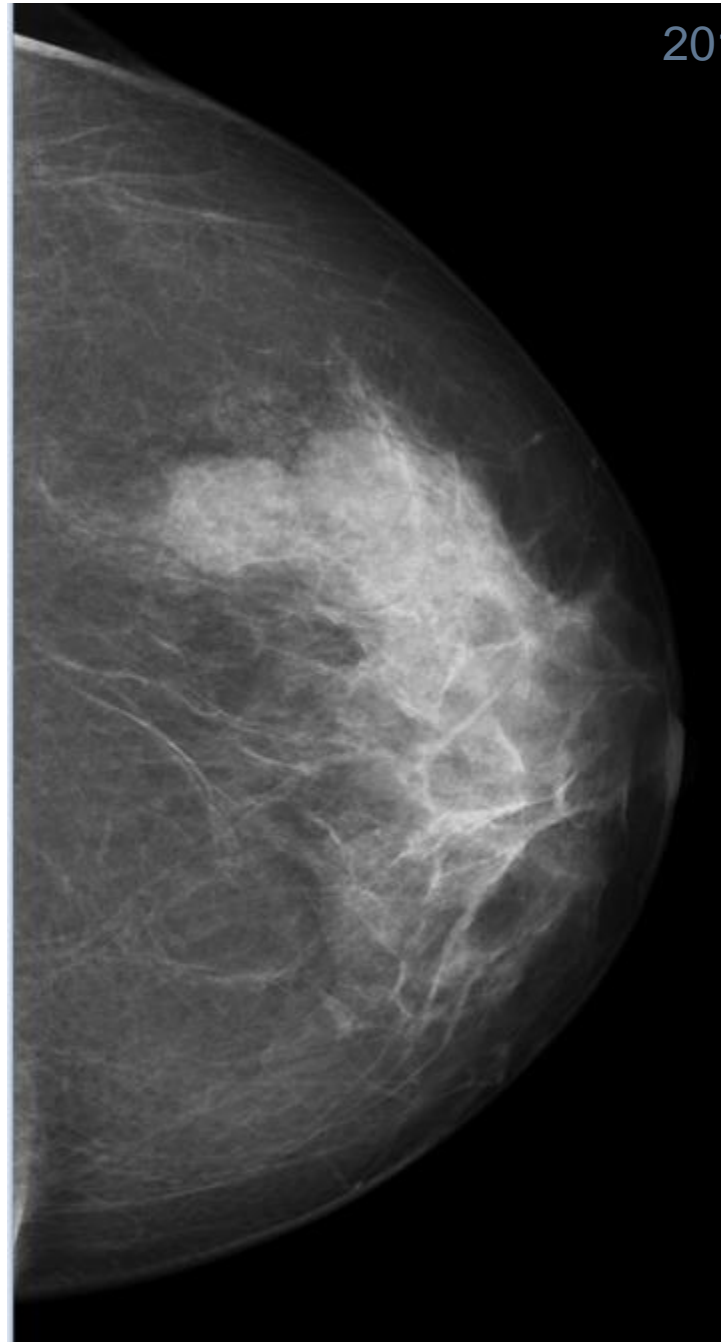
2014



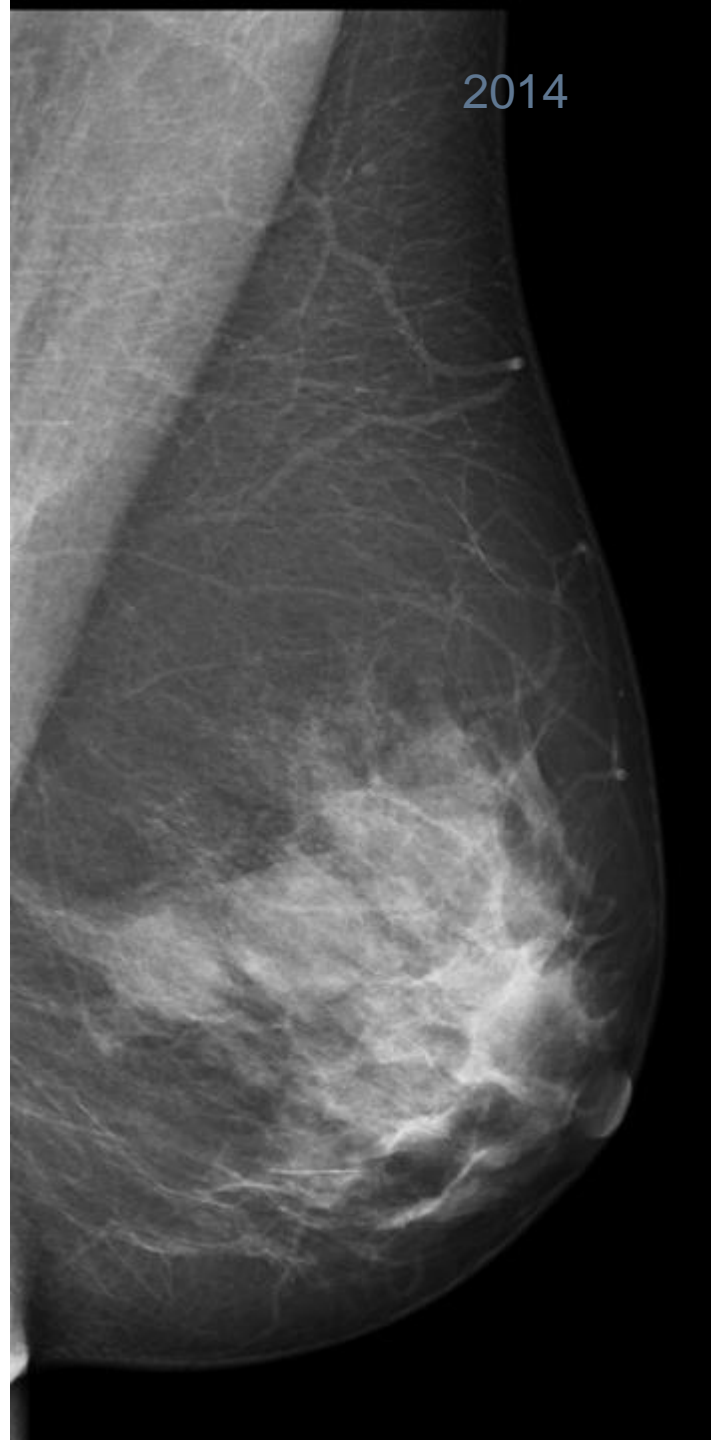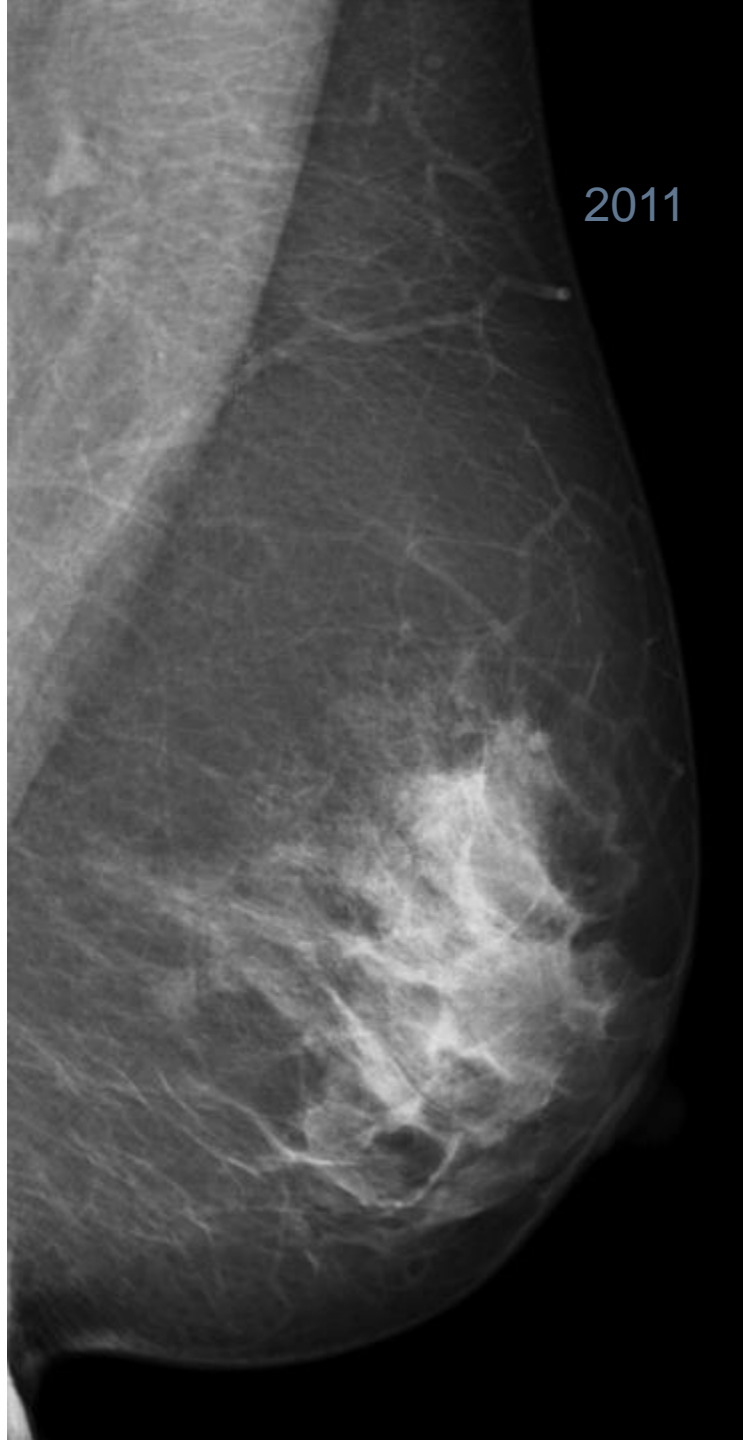
Invasief ca  
> 1 cm



2011



2014

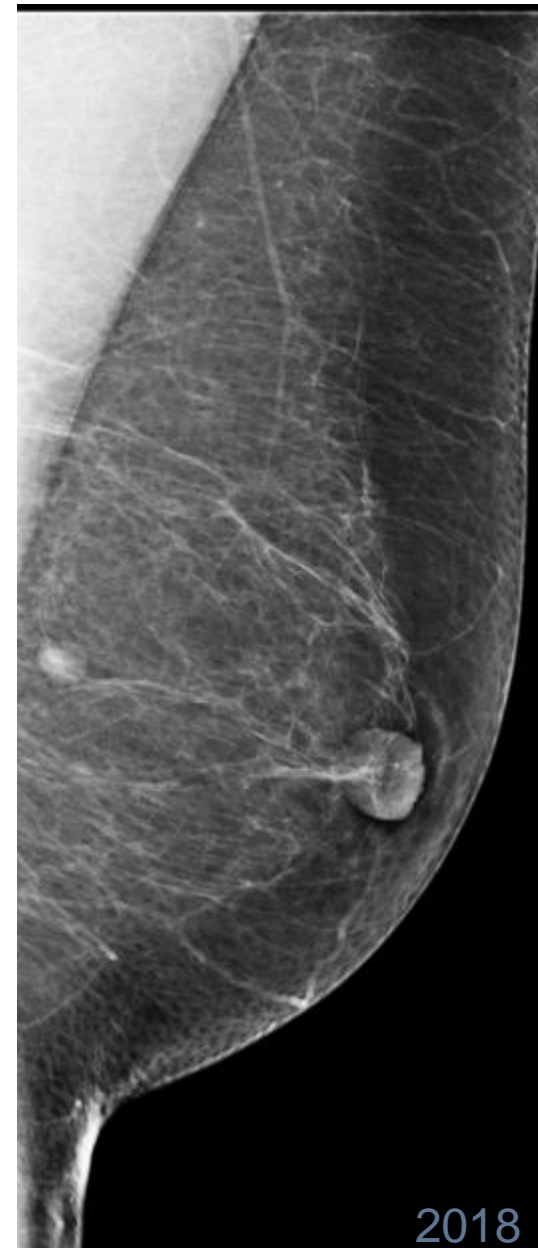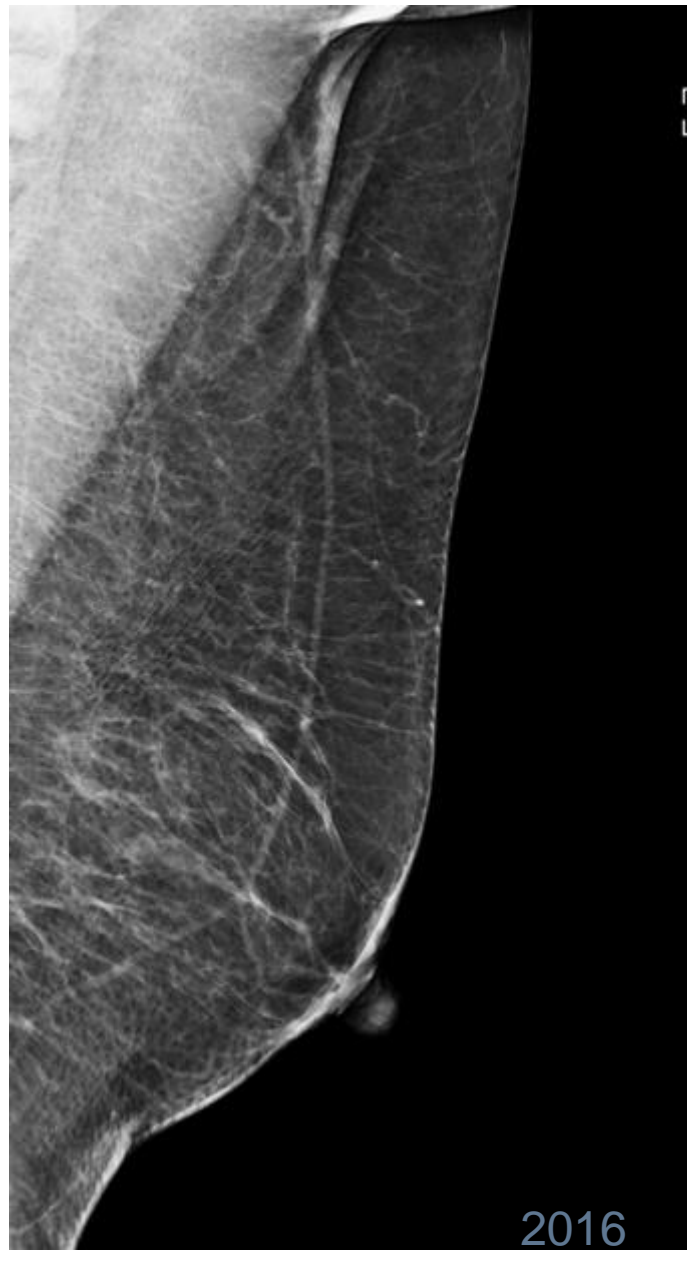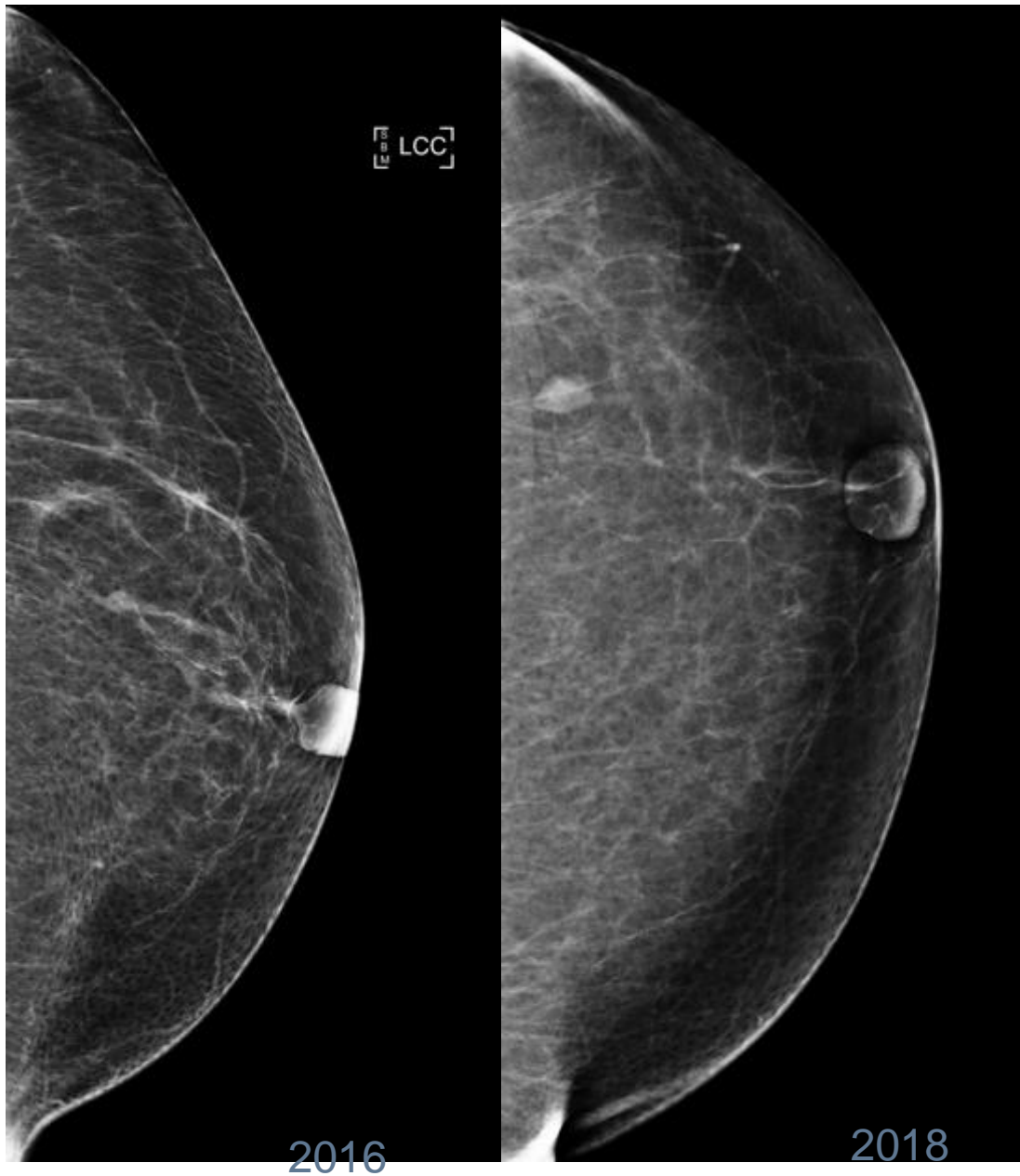


# Recall?

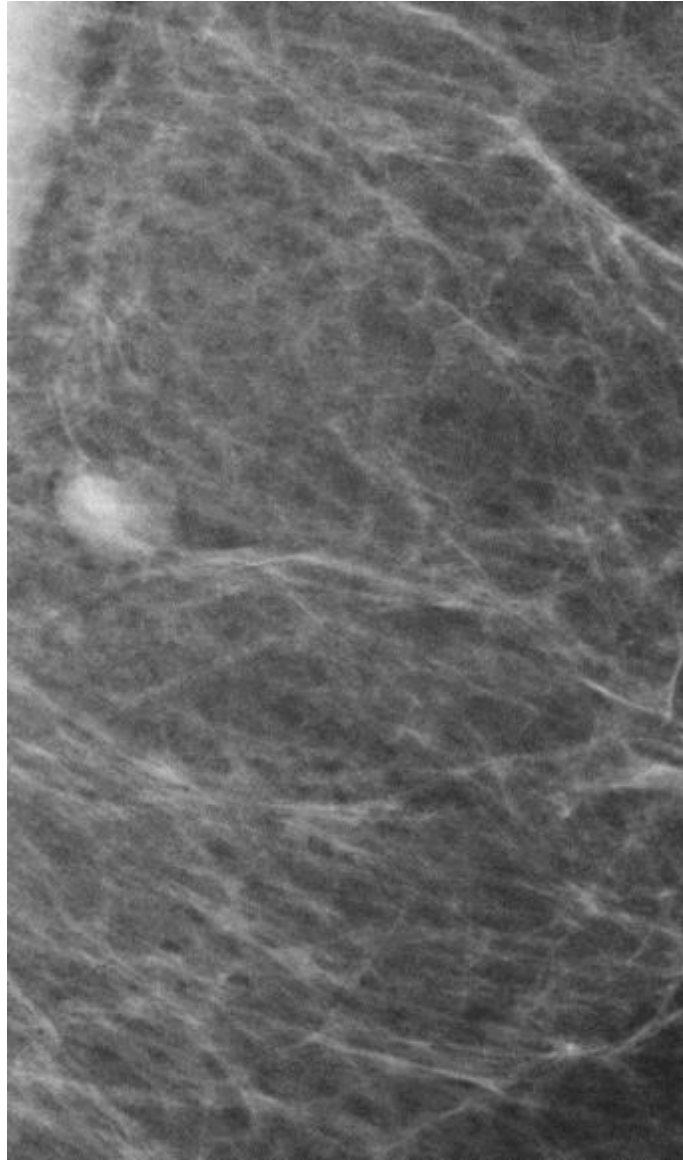
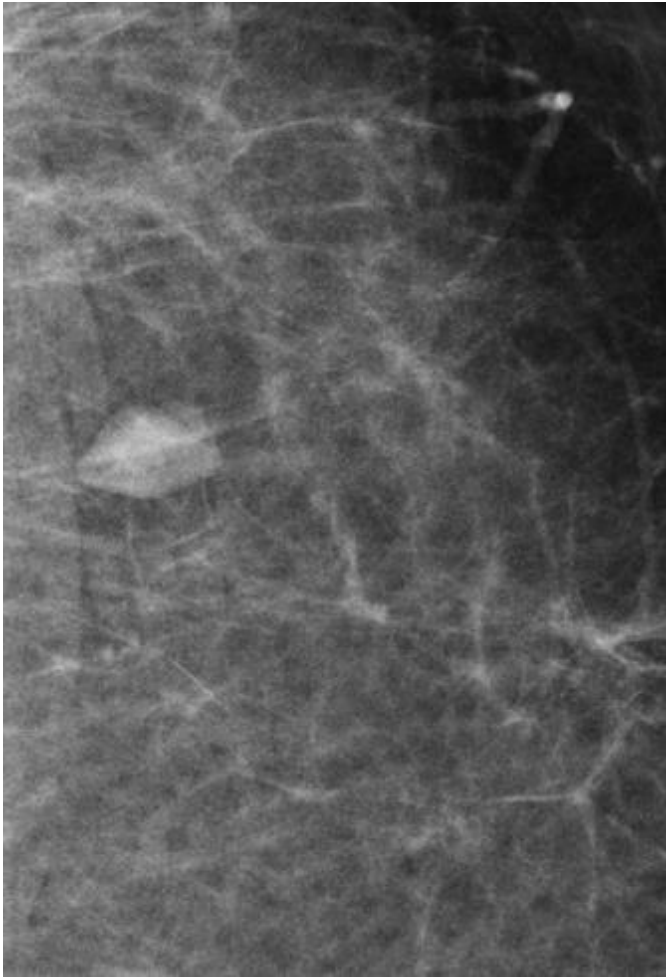
- Ja
- Nee







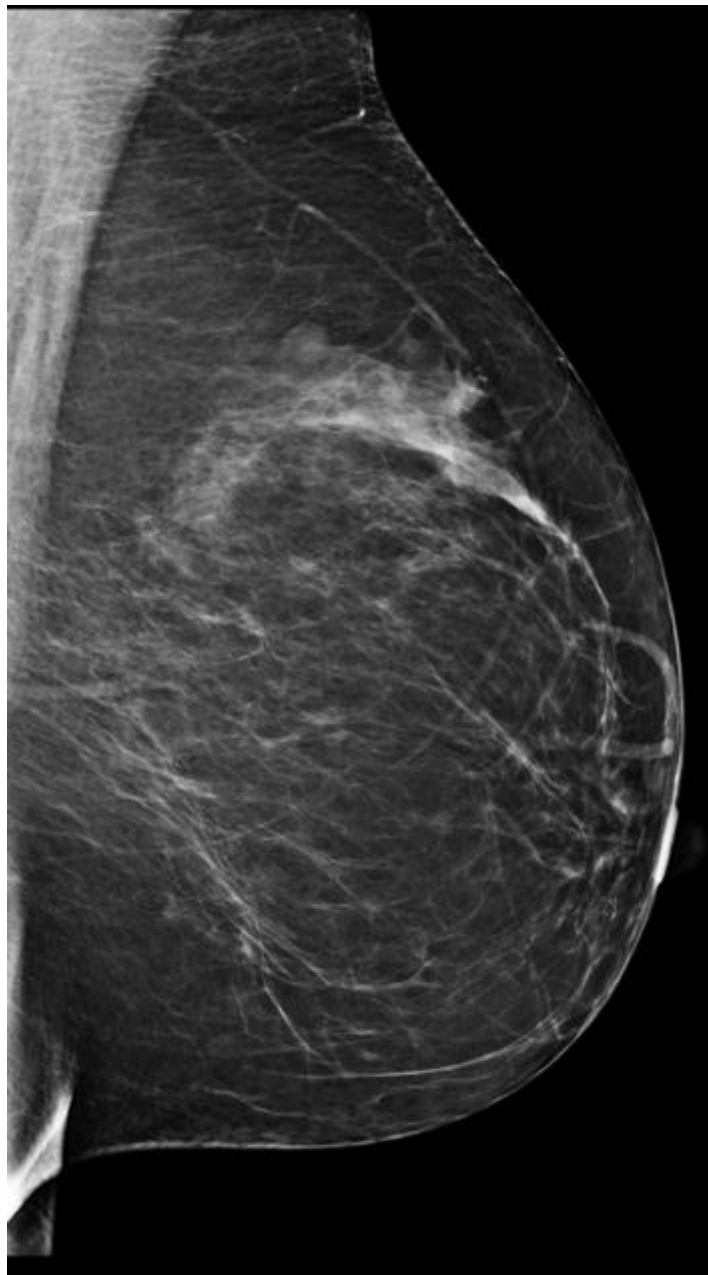
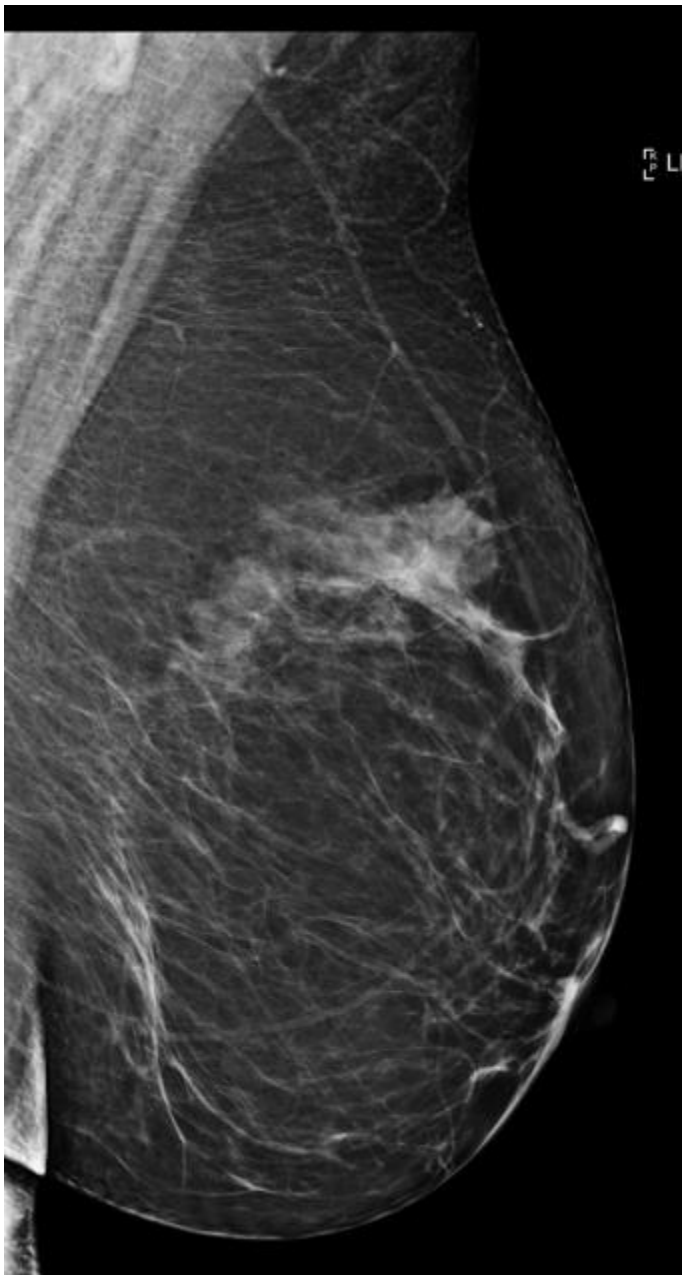


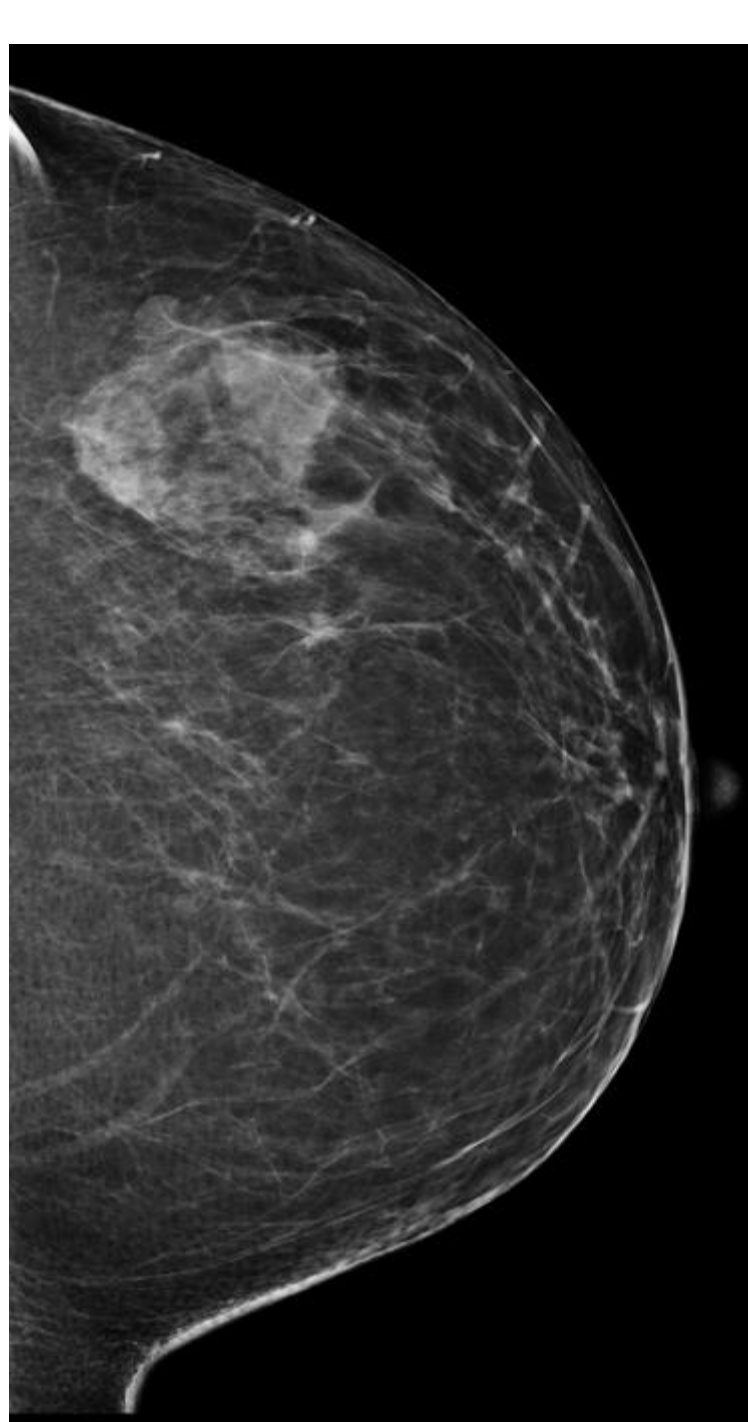
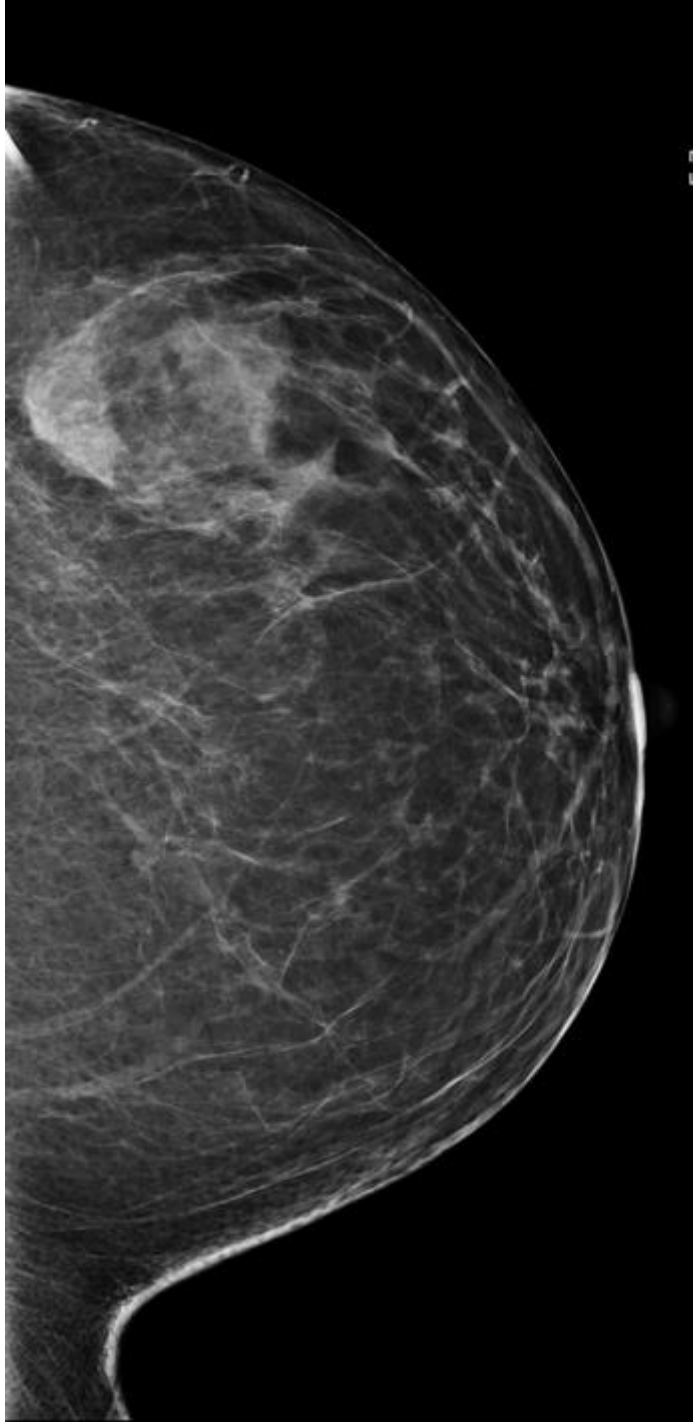


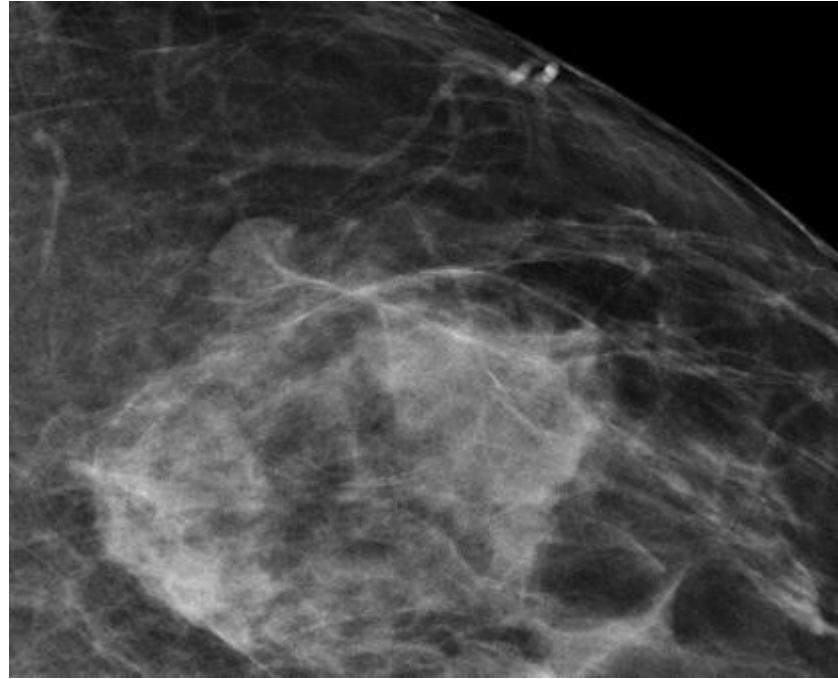
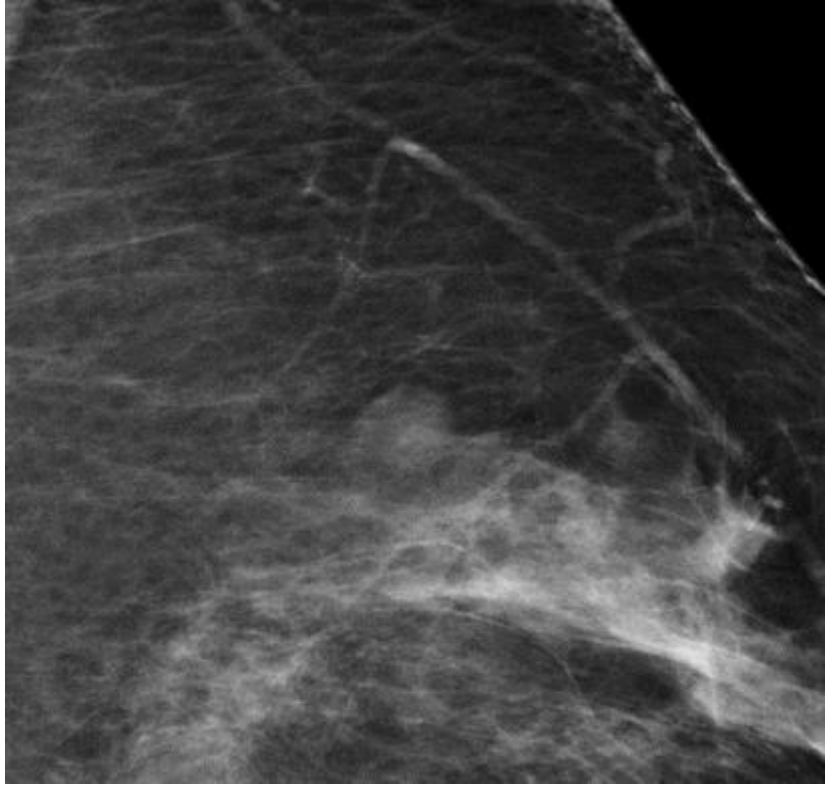
# Recall?

- Ja
- Nee





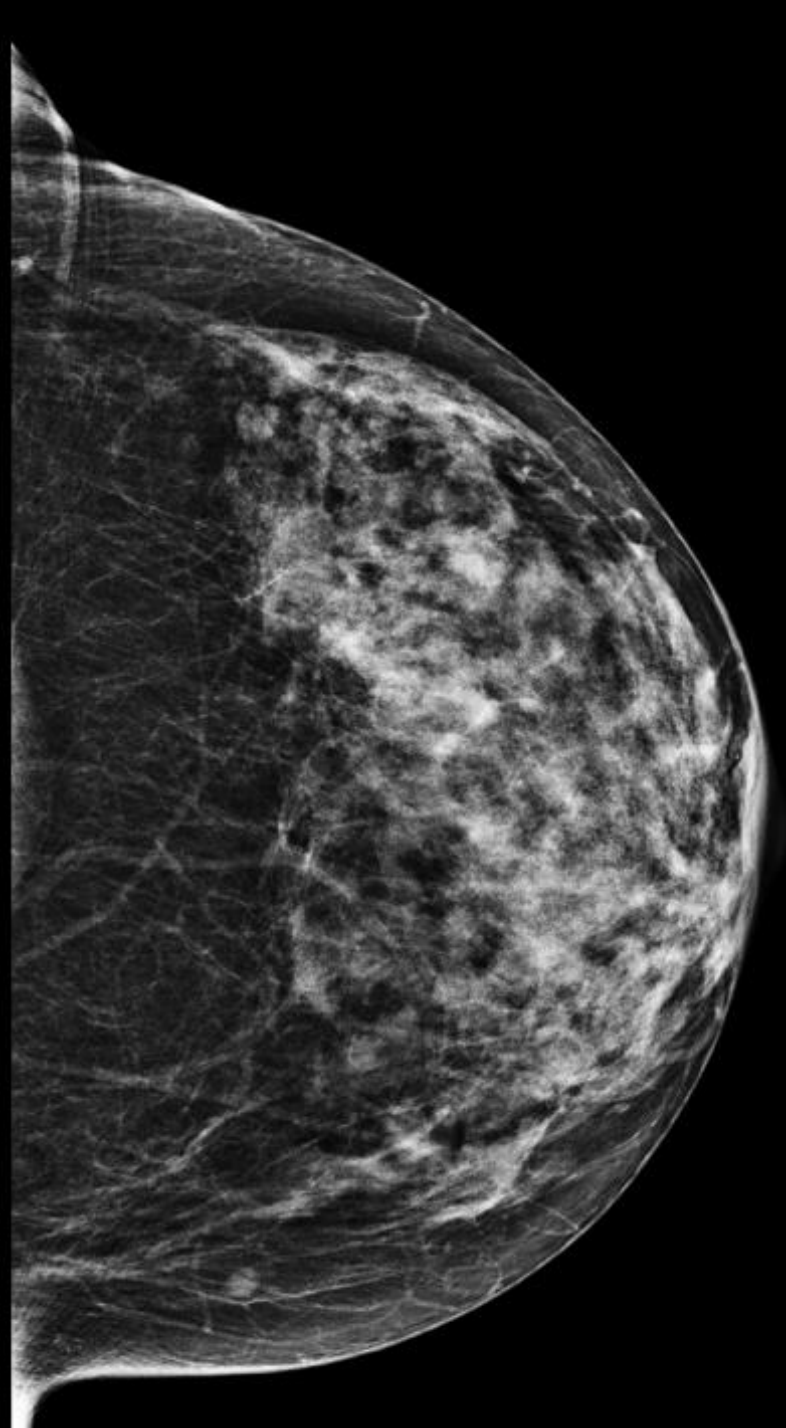




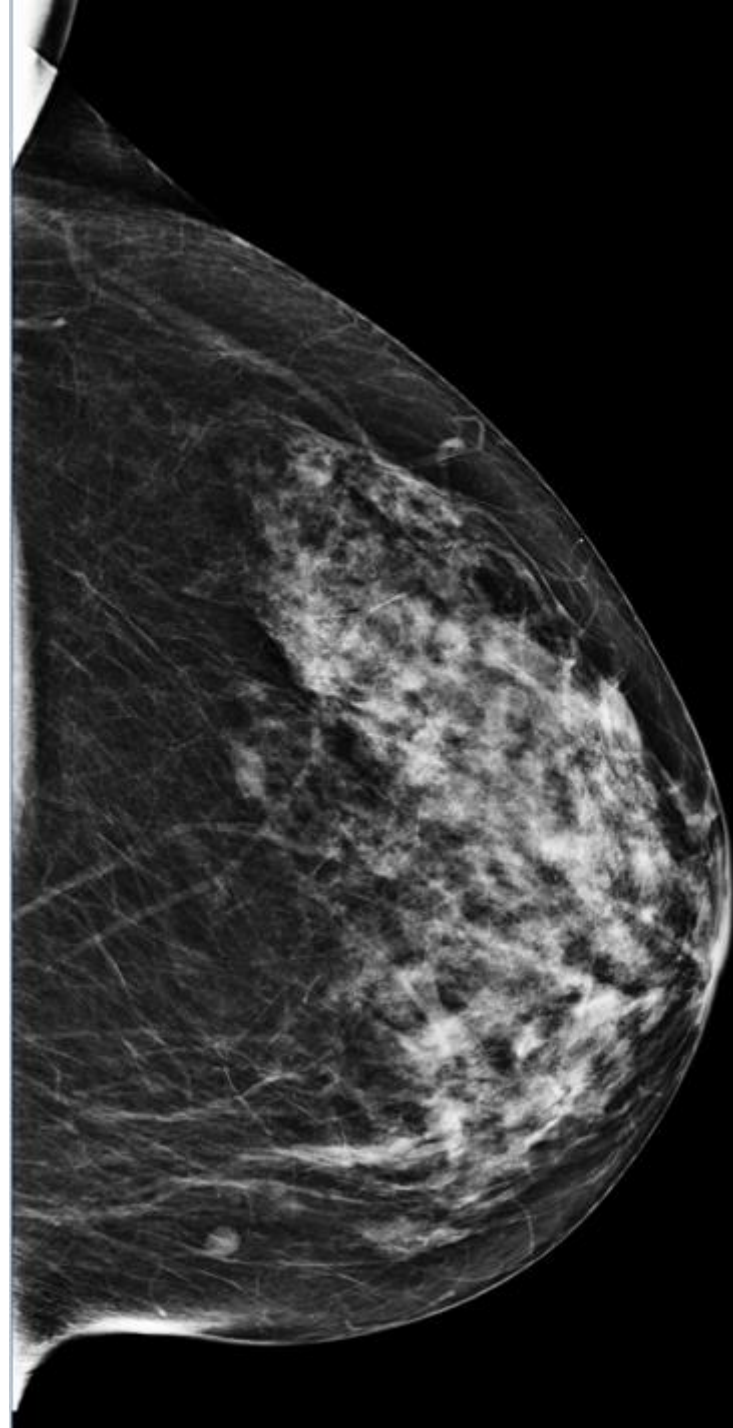
# Recall?

- Ja
- Nee



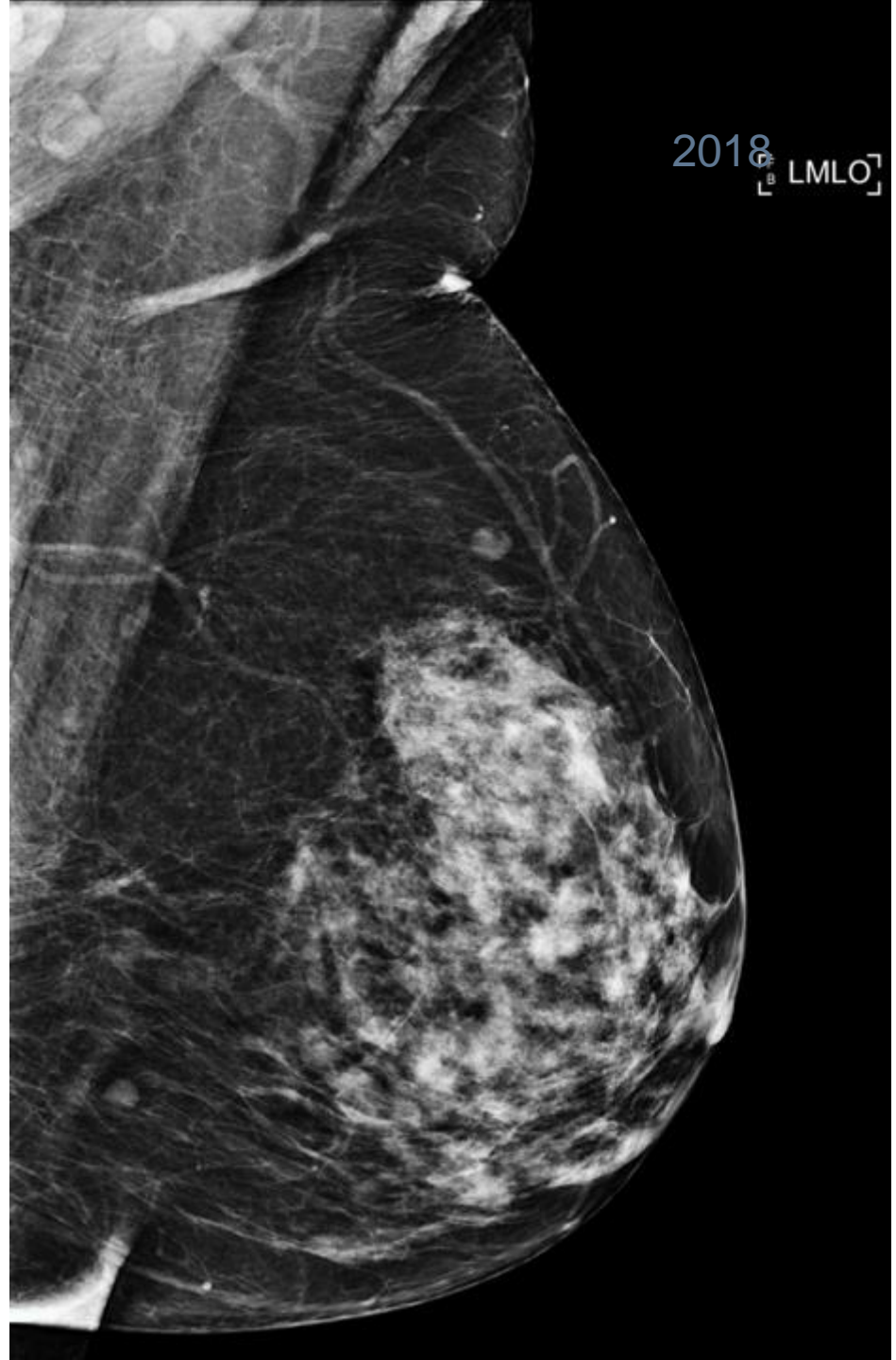
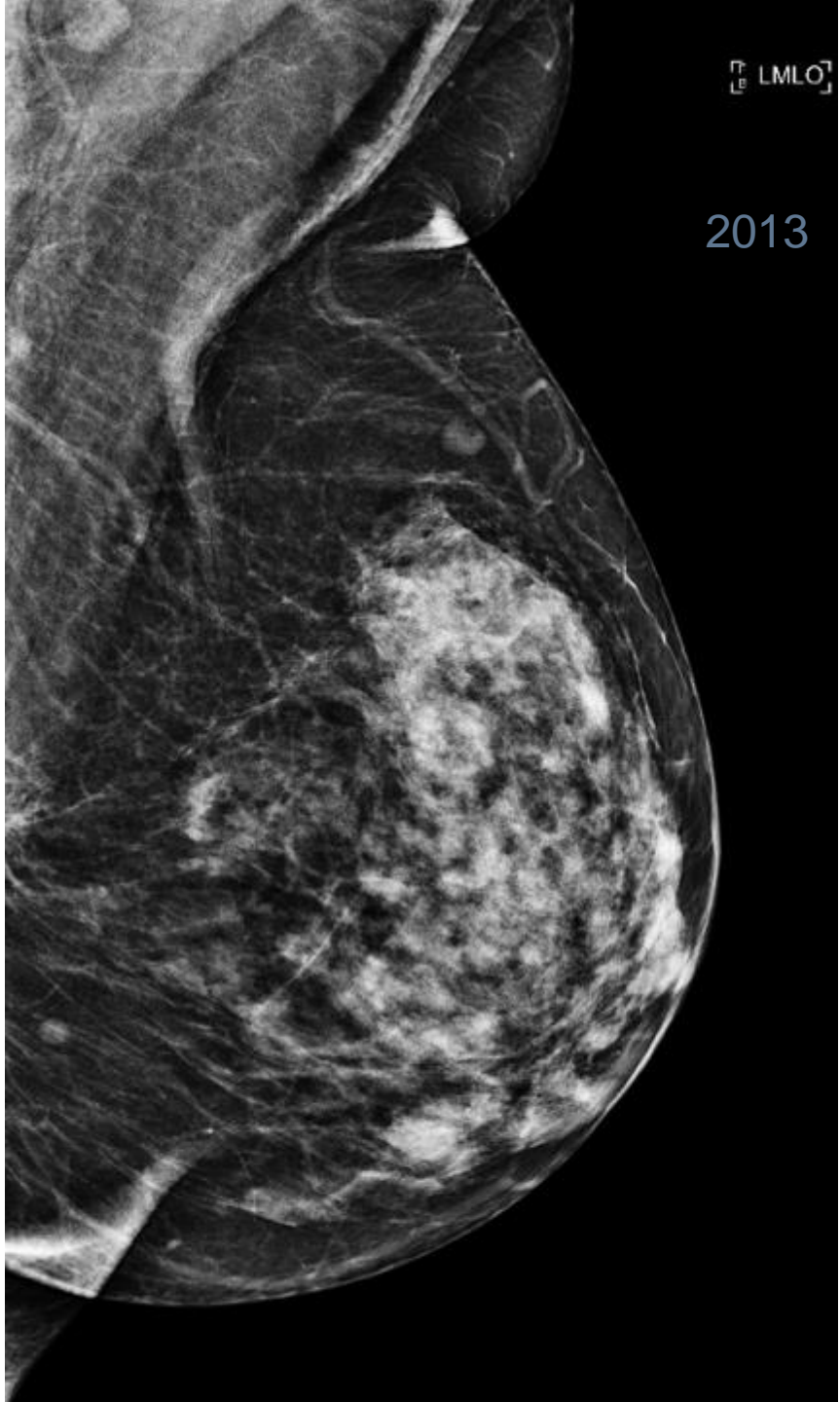


2013



2018

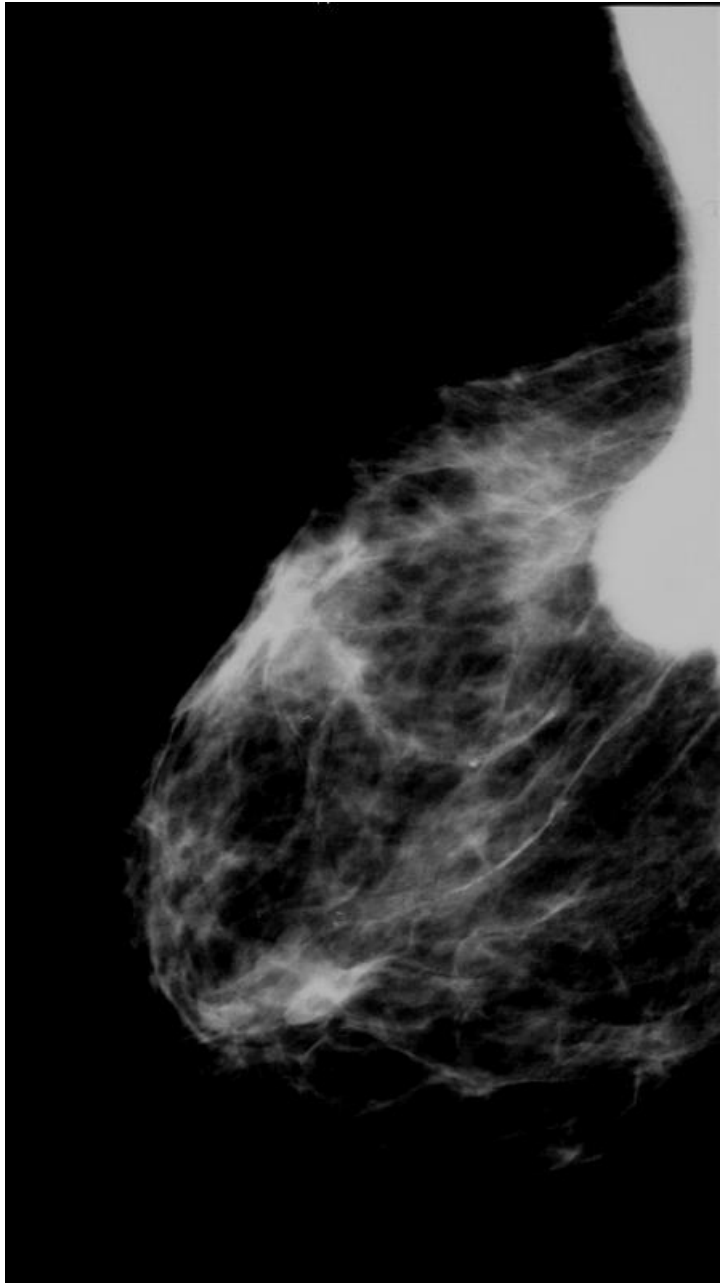




# Recall?

- Ja
- Nee

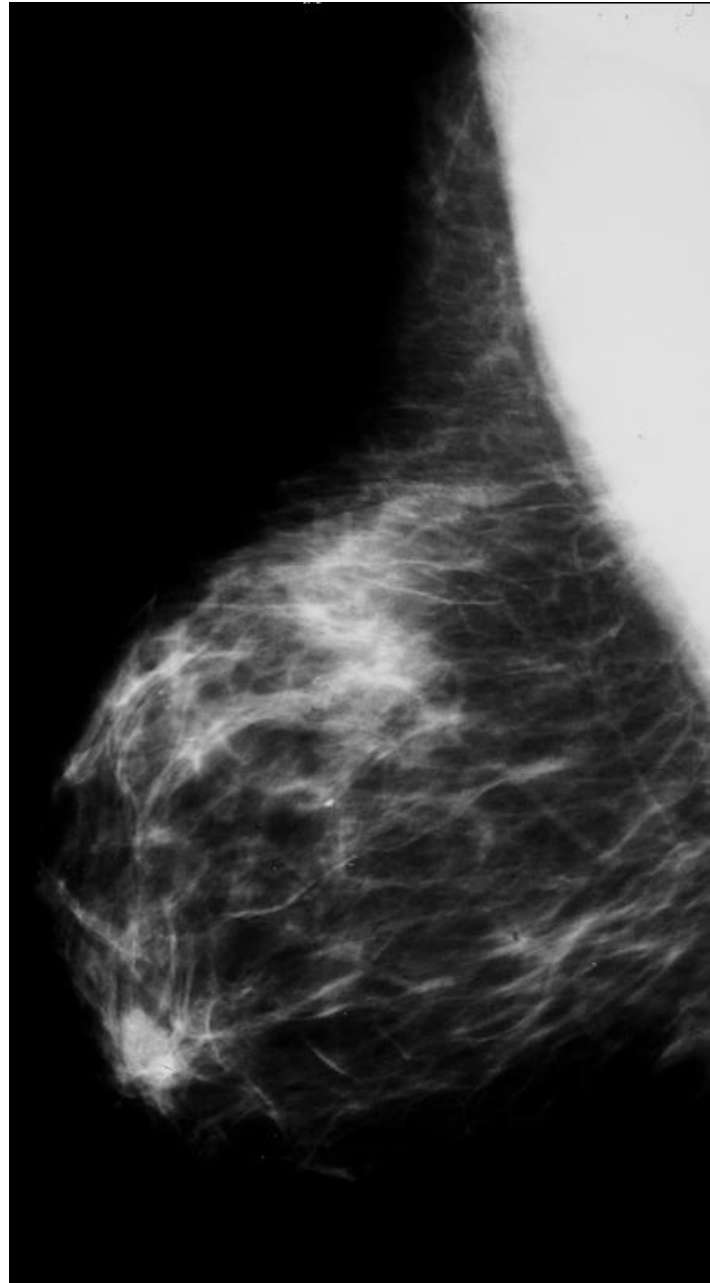
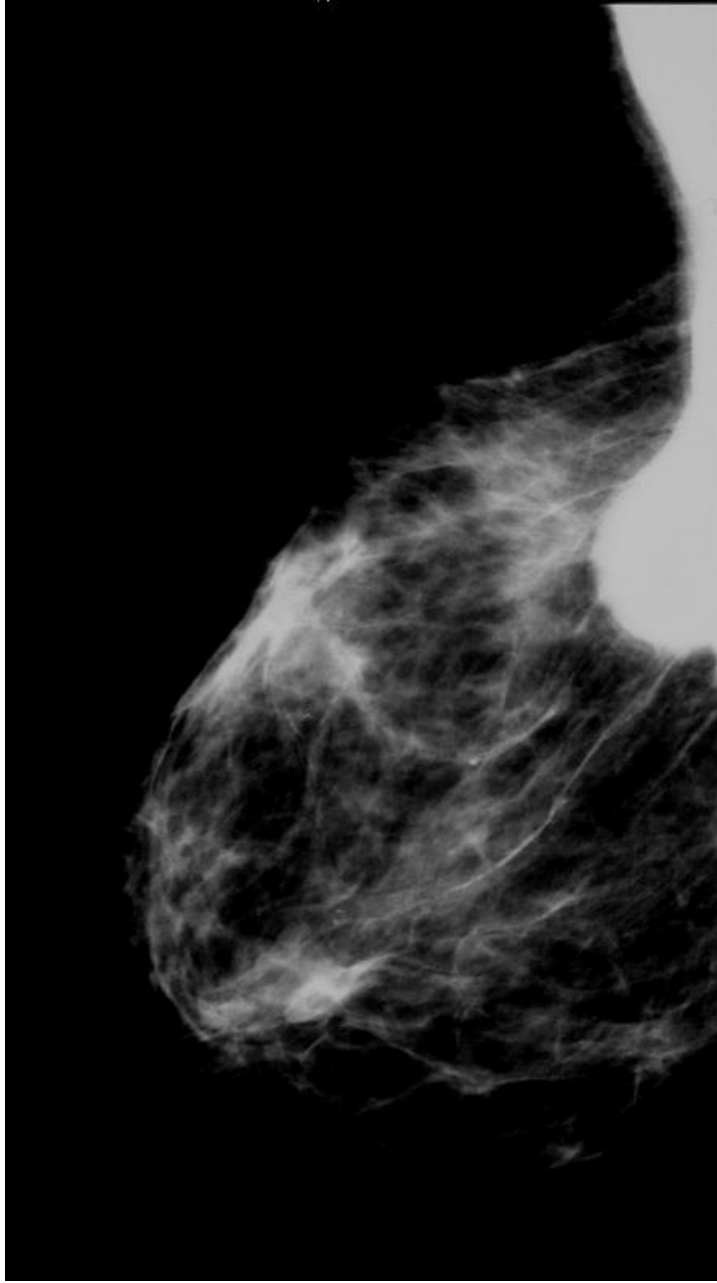


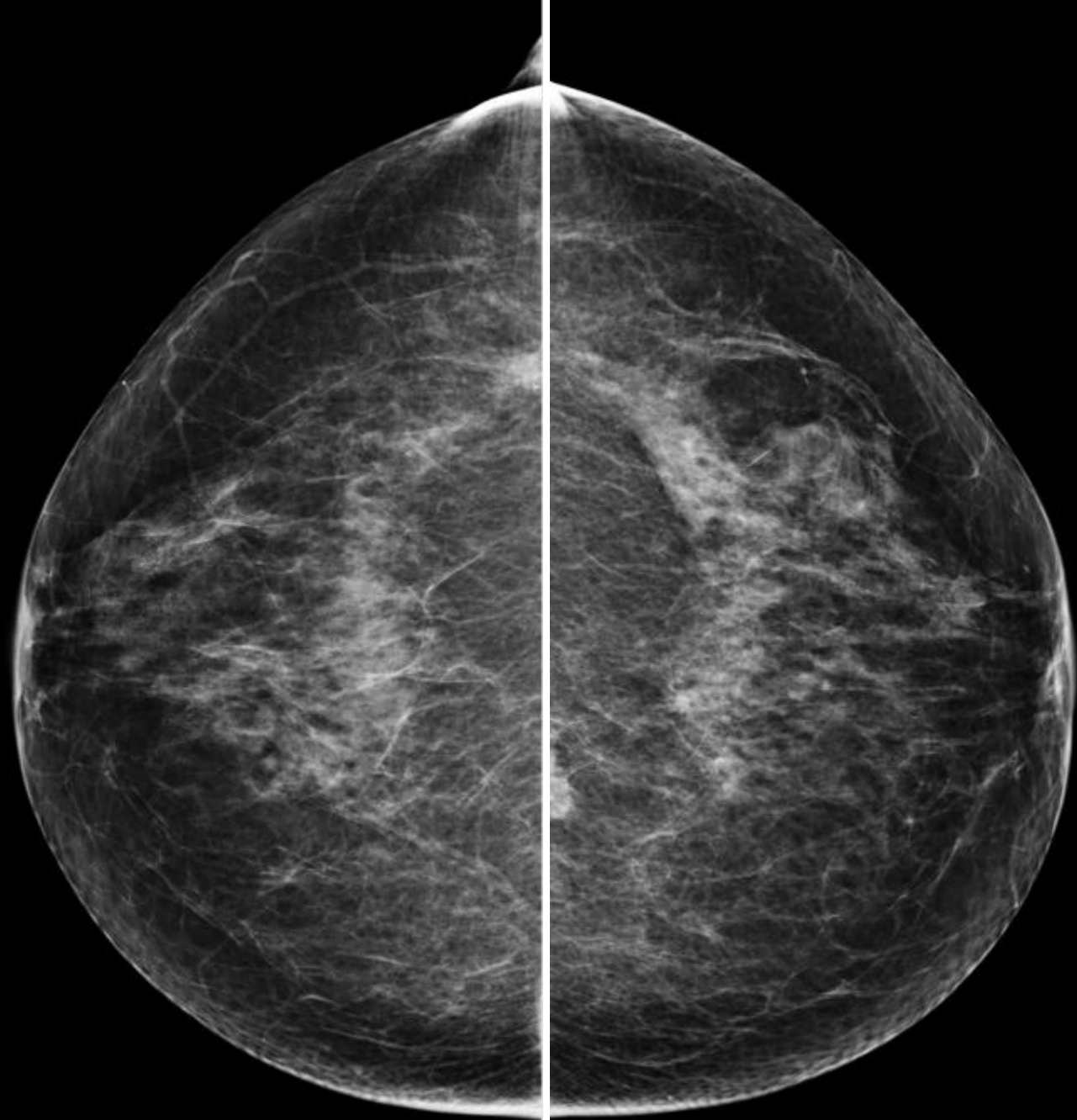


# Recall?

- Ja
- Nee

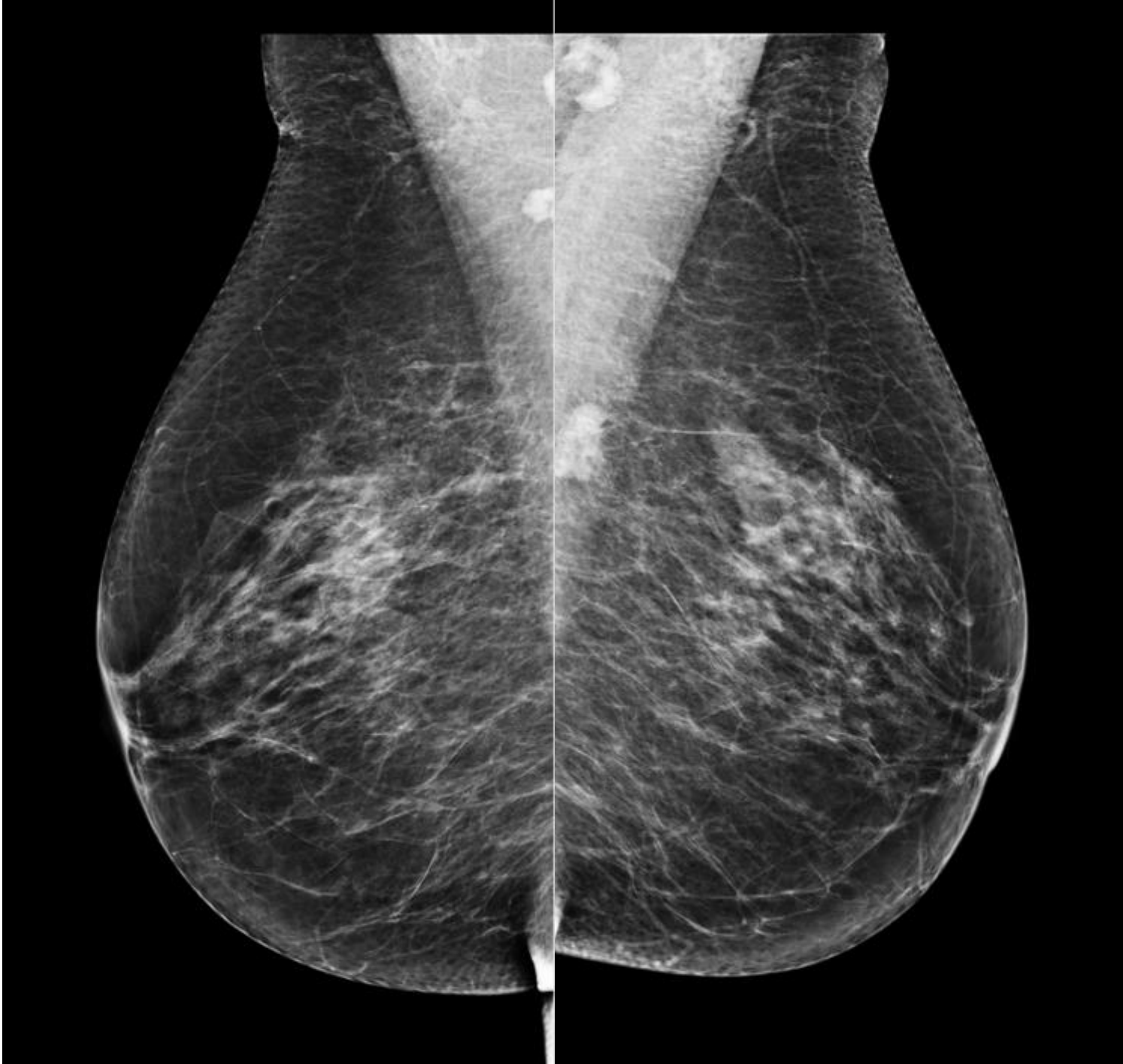





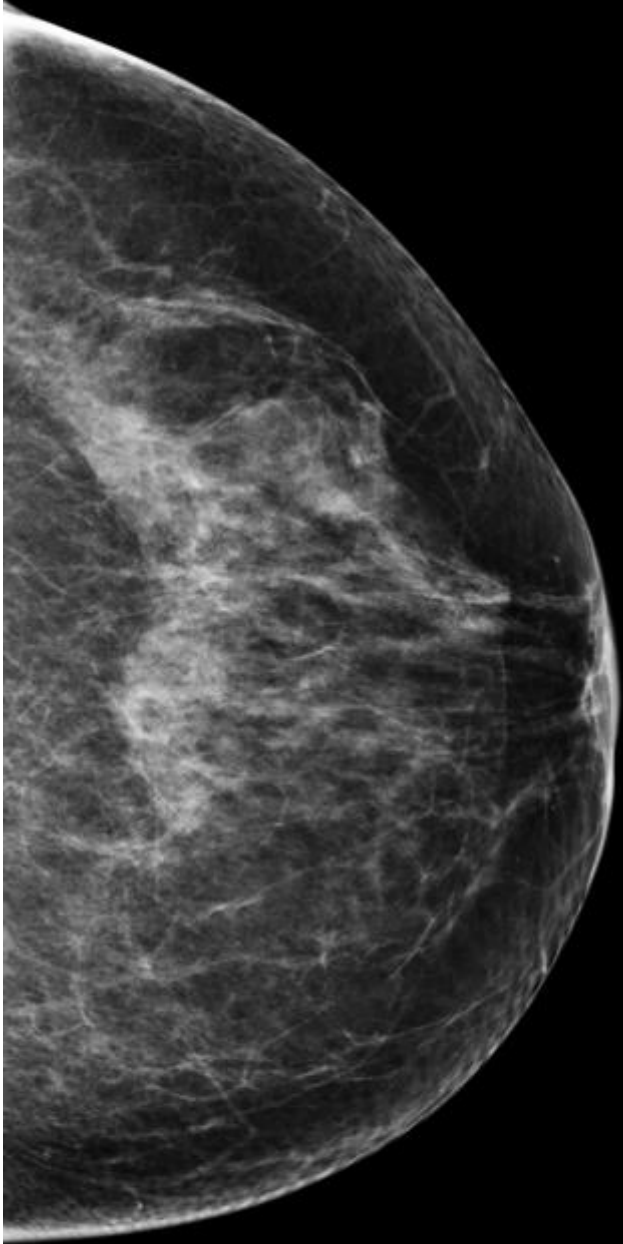
2018



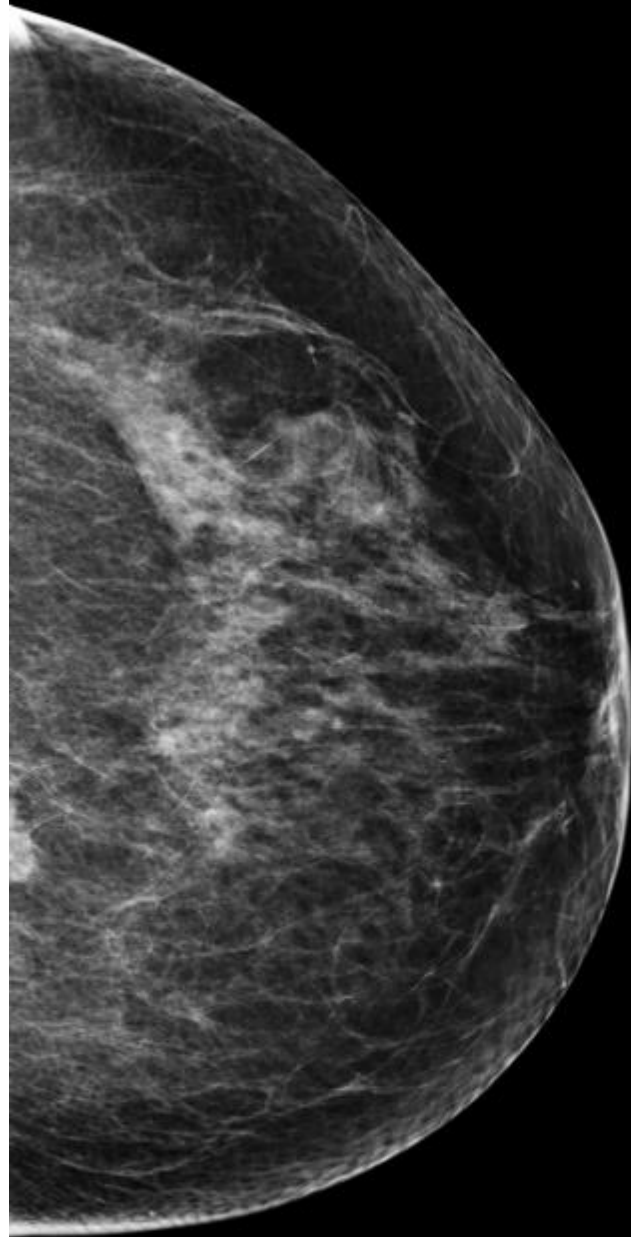


2018

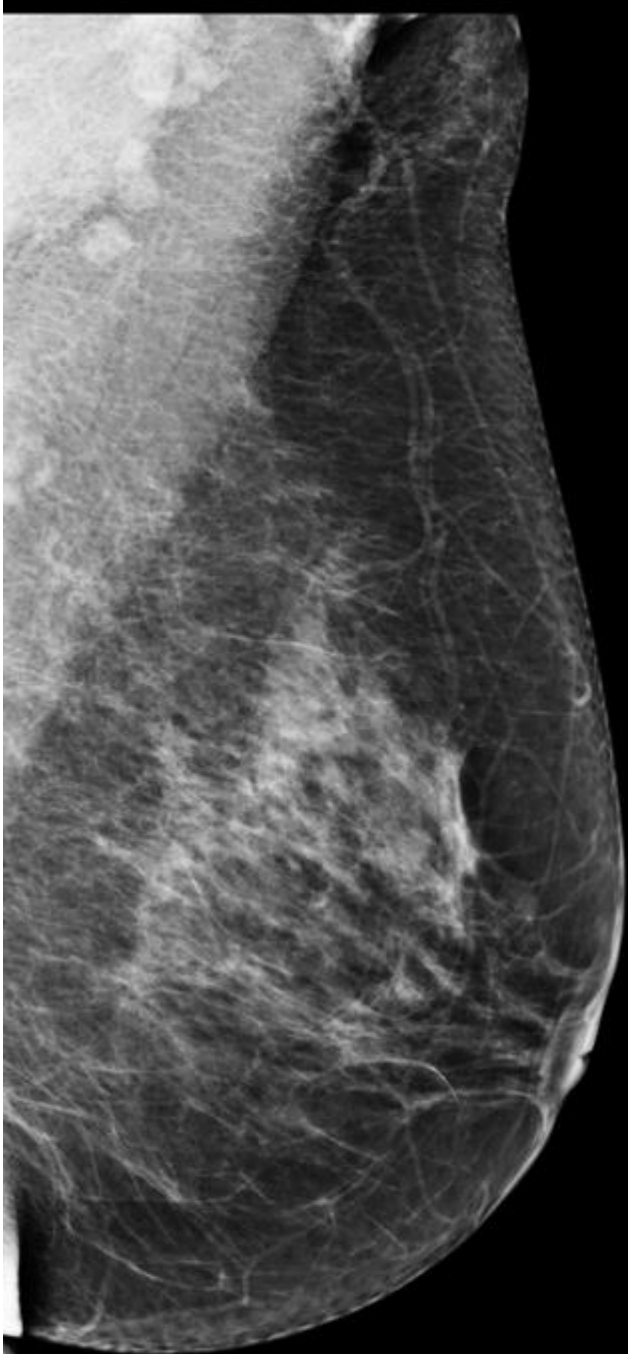




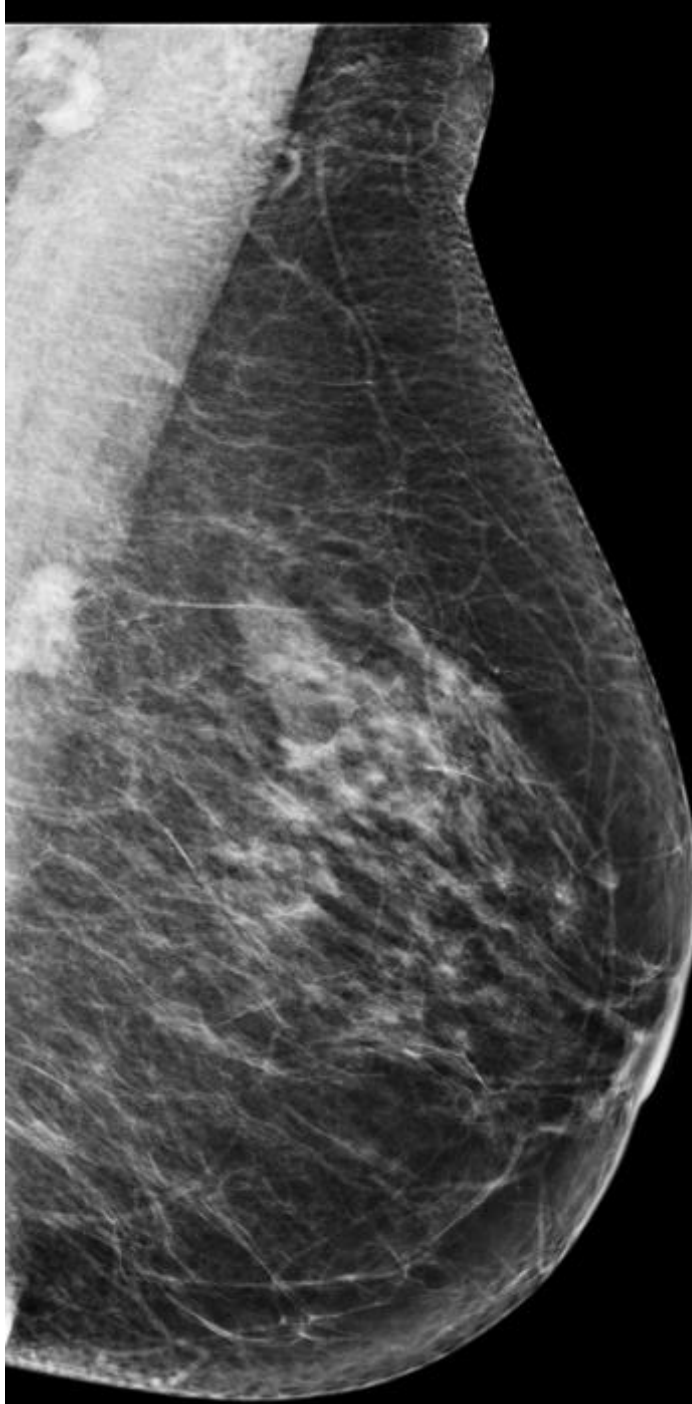
2012



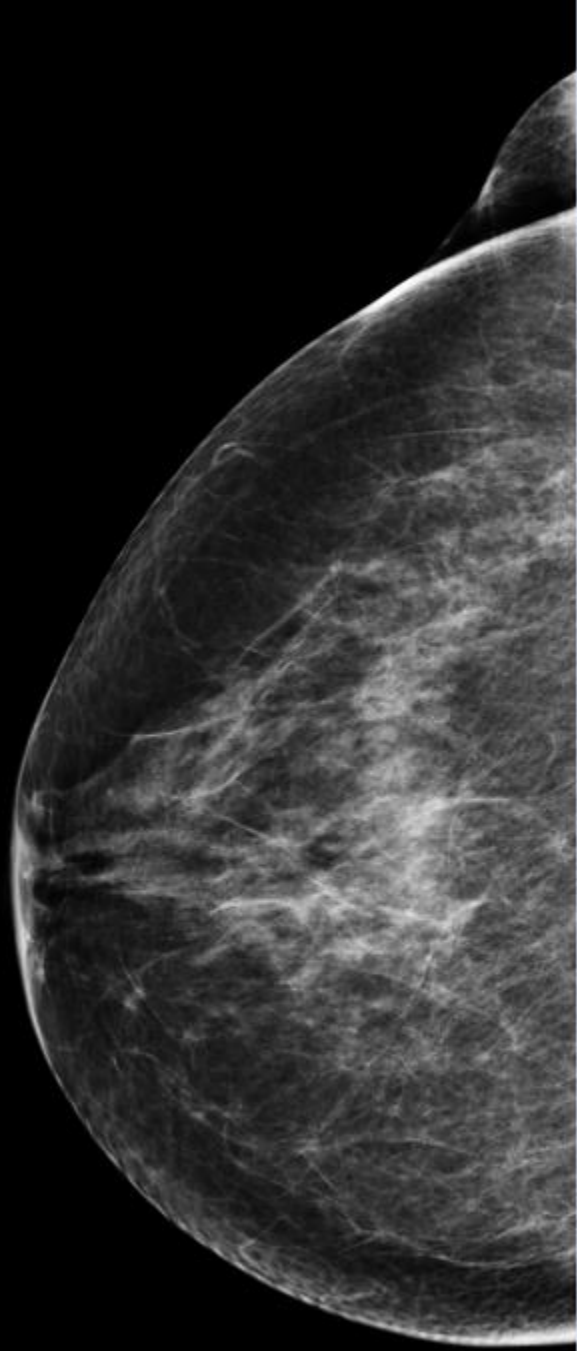
2018



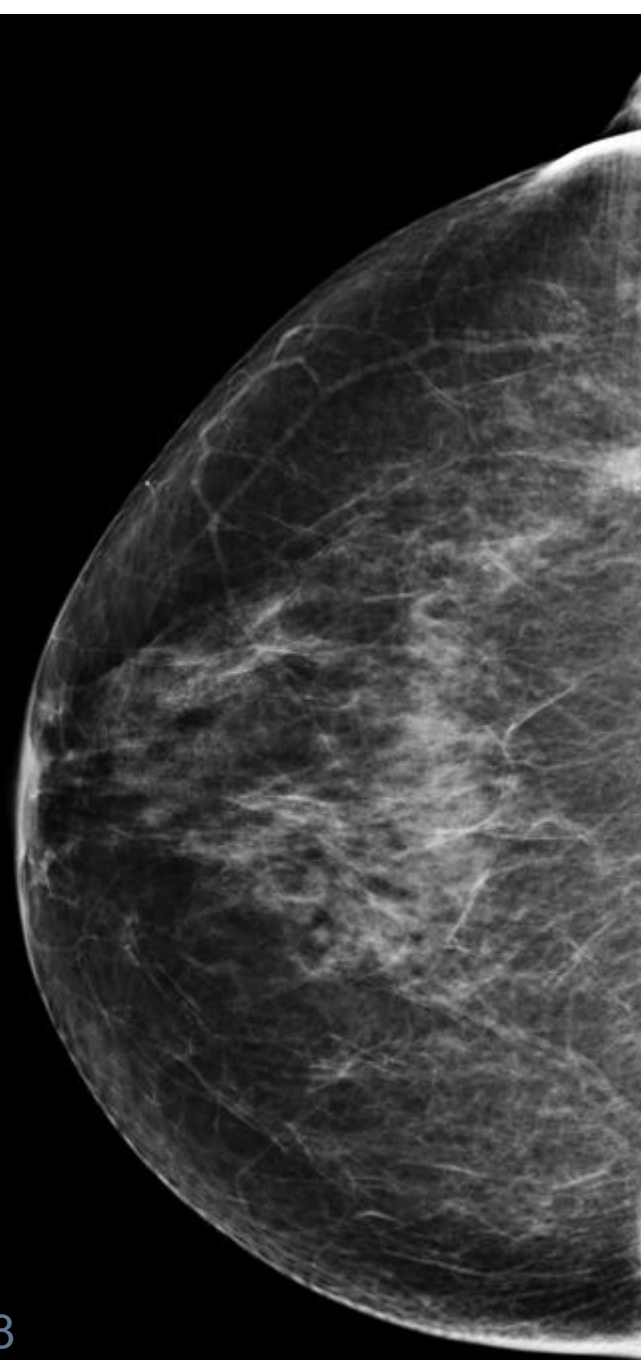
2012



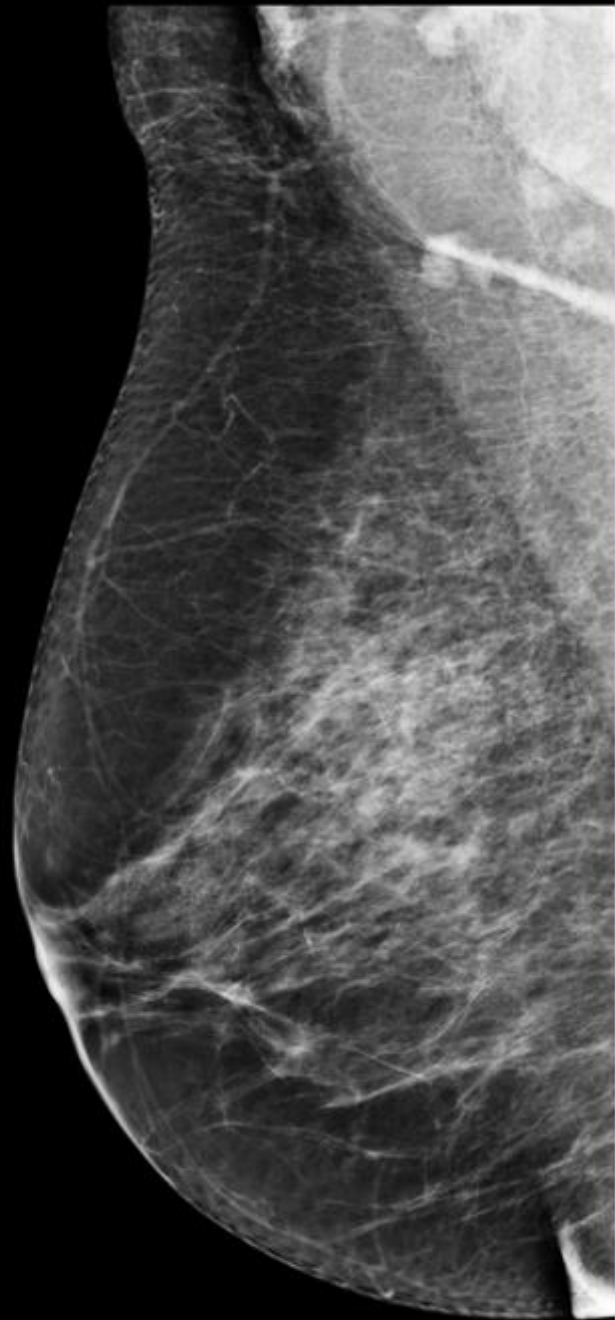
2018



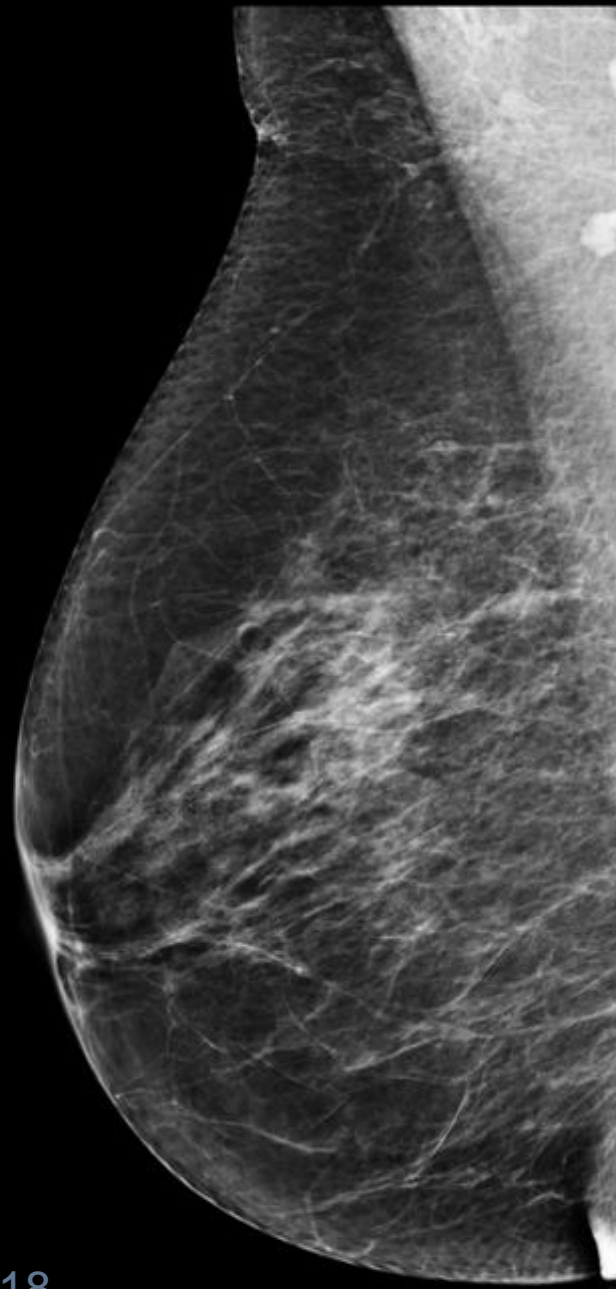
2012



2018



2012



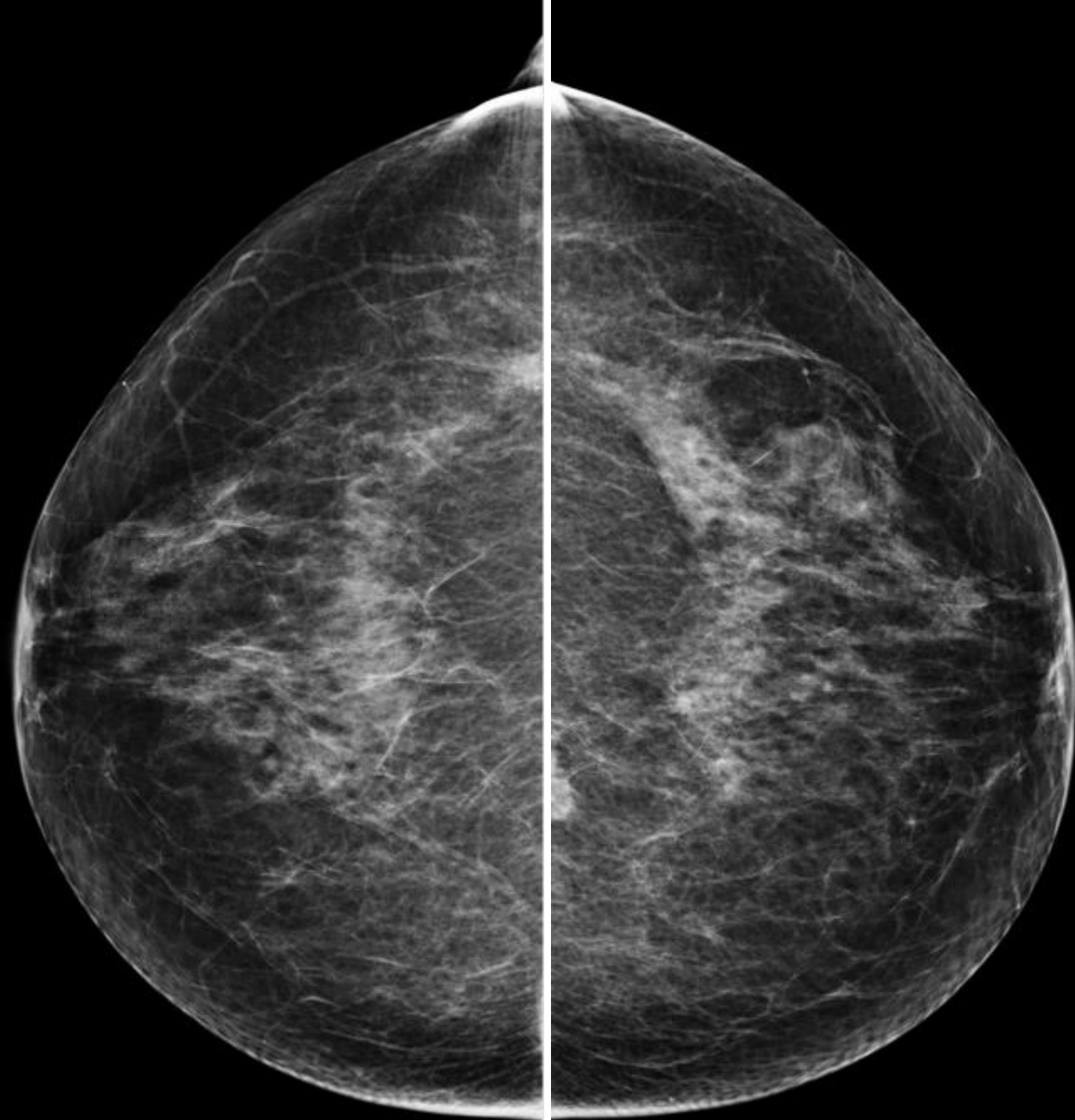
2018

# Recall?

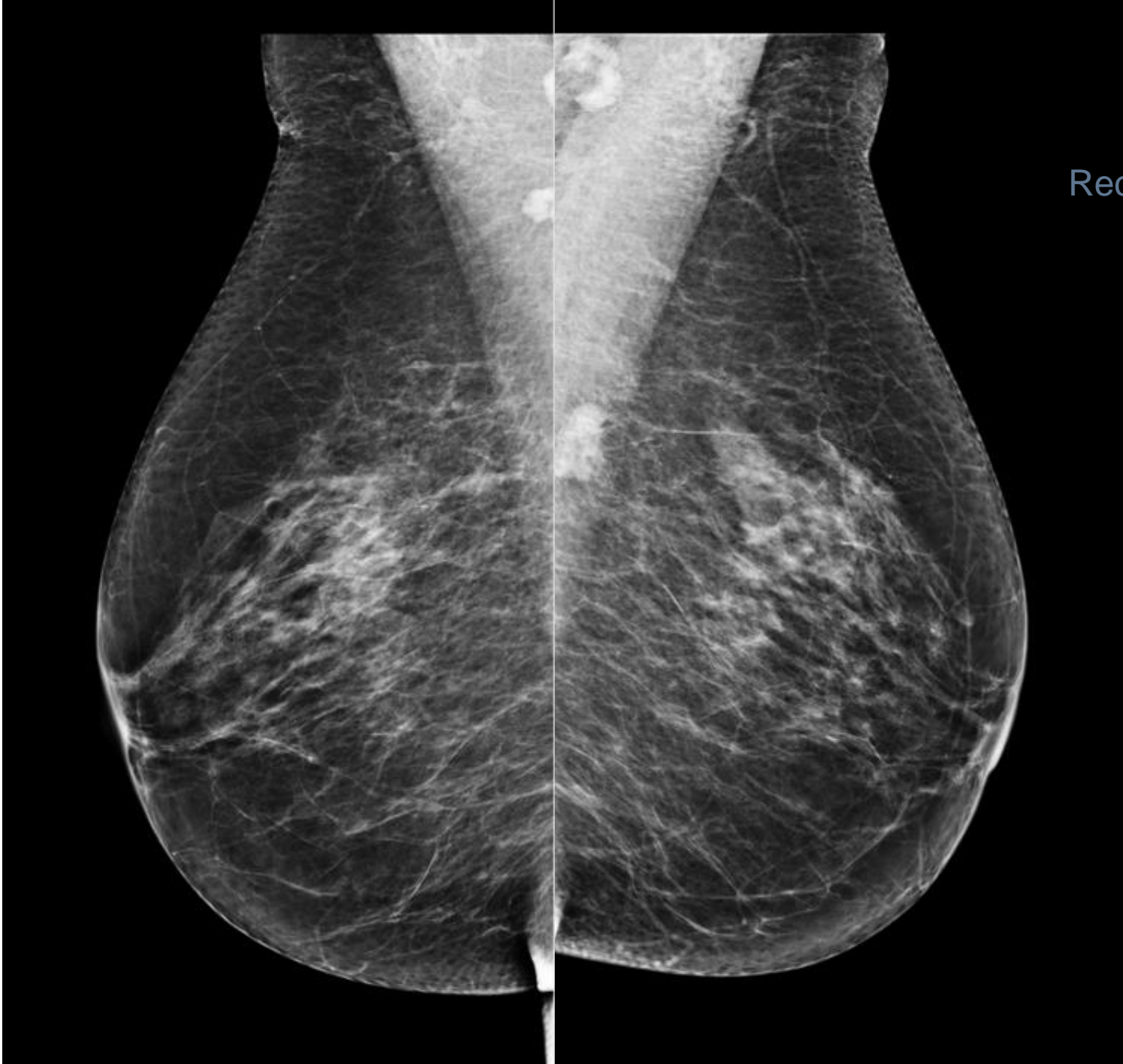- Ja
- Nee







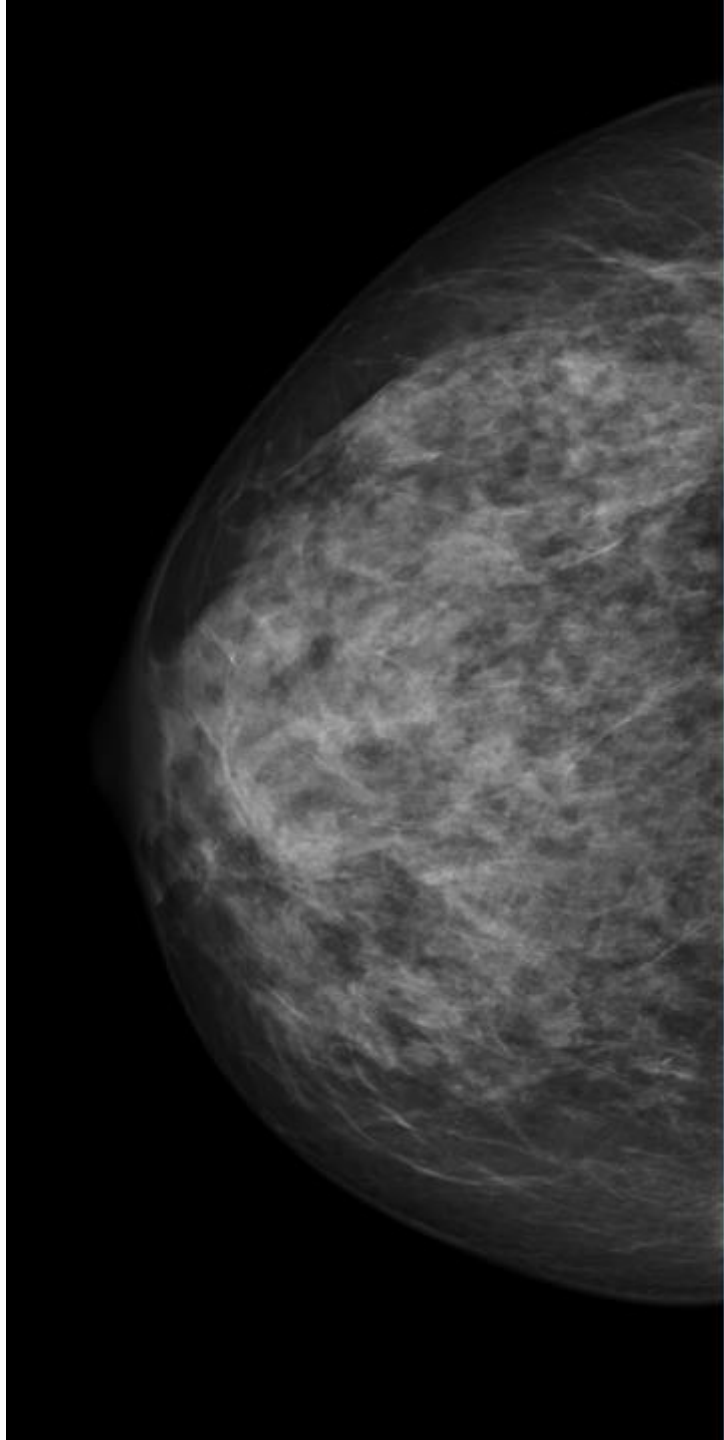
Rechts: IDA



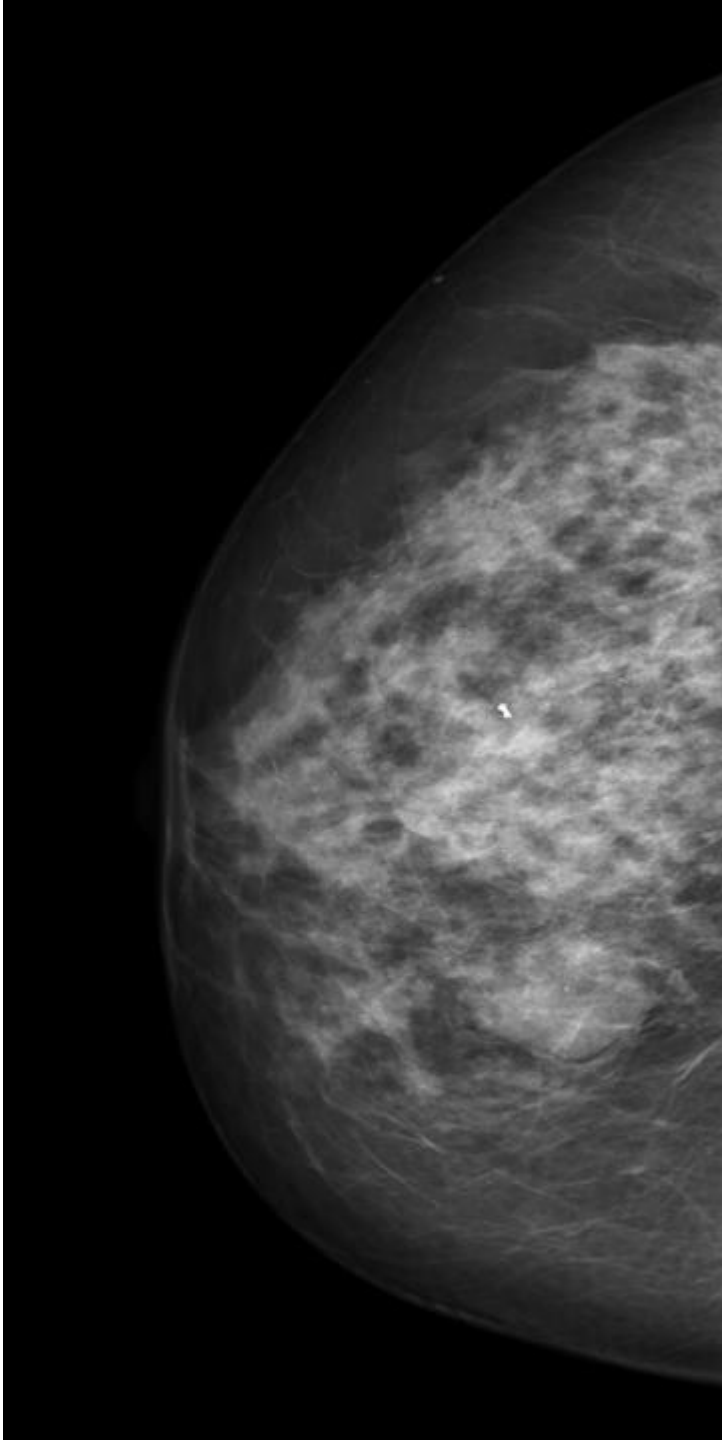
Rechts: IDA



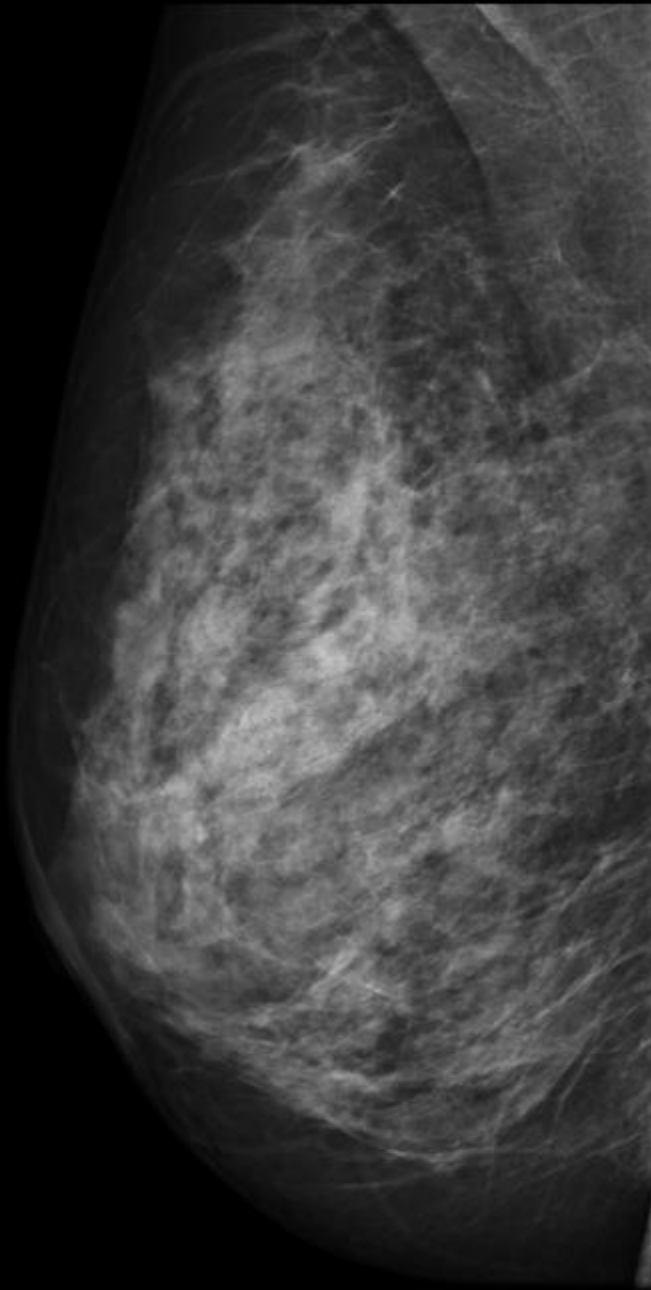
2009



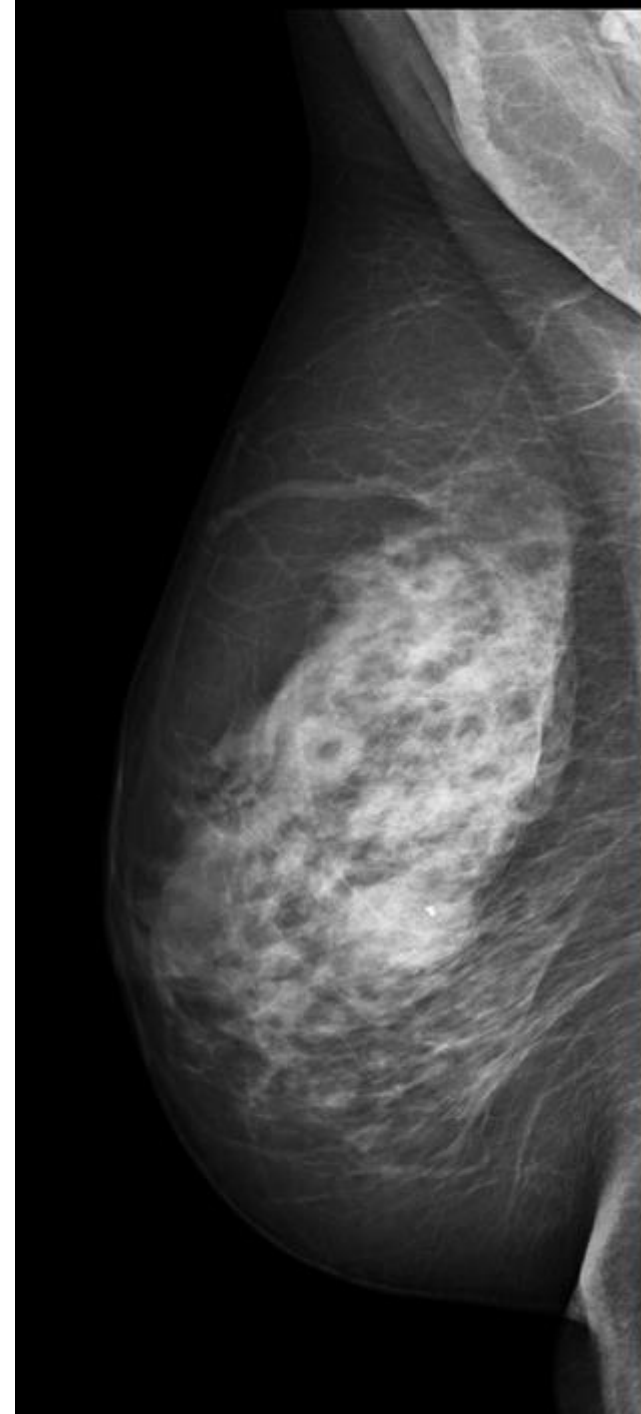
2018



2009



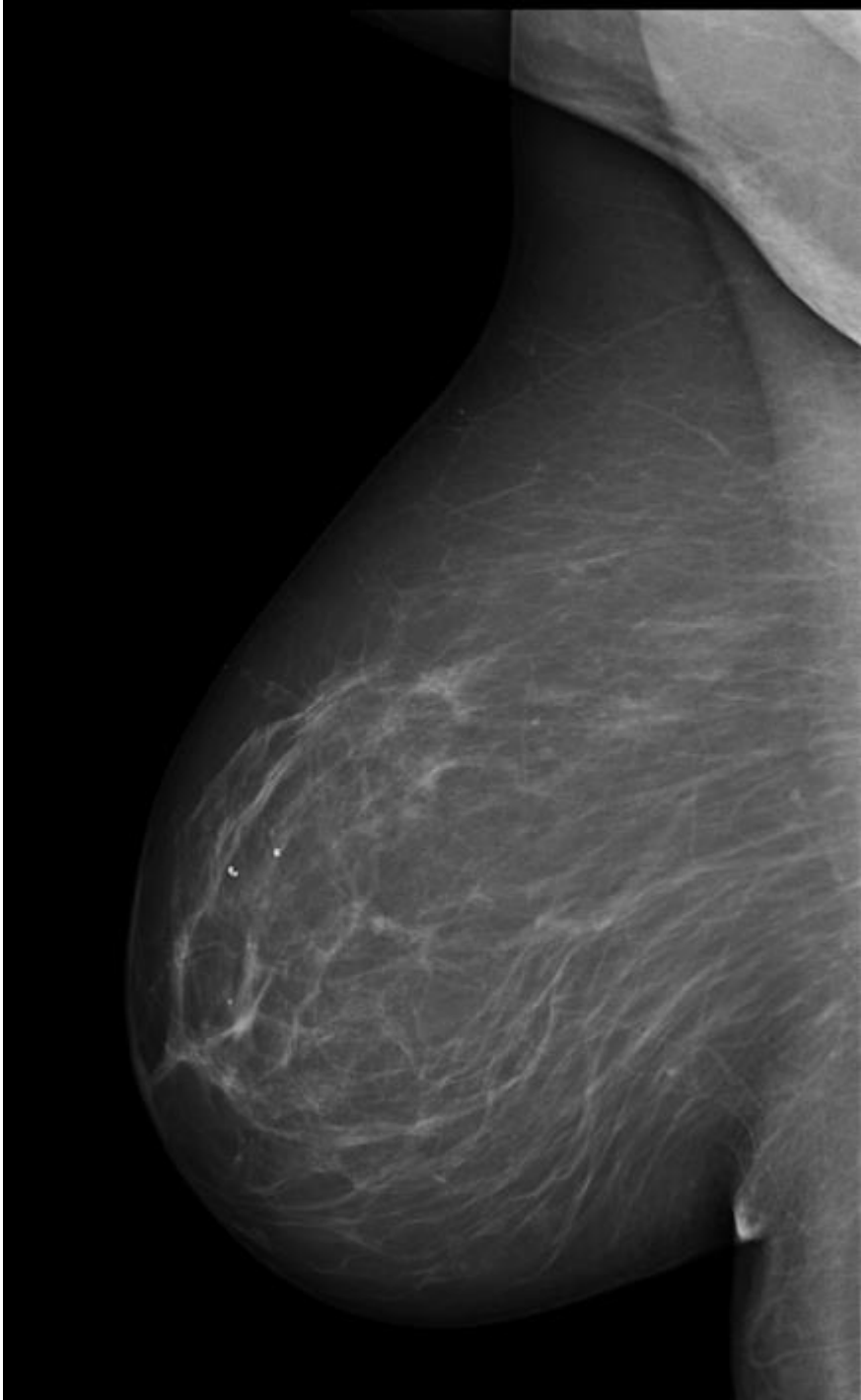
2018



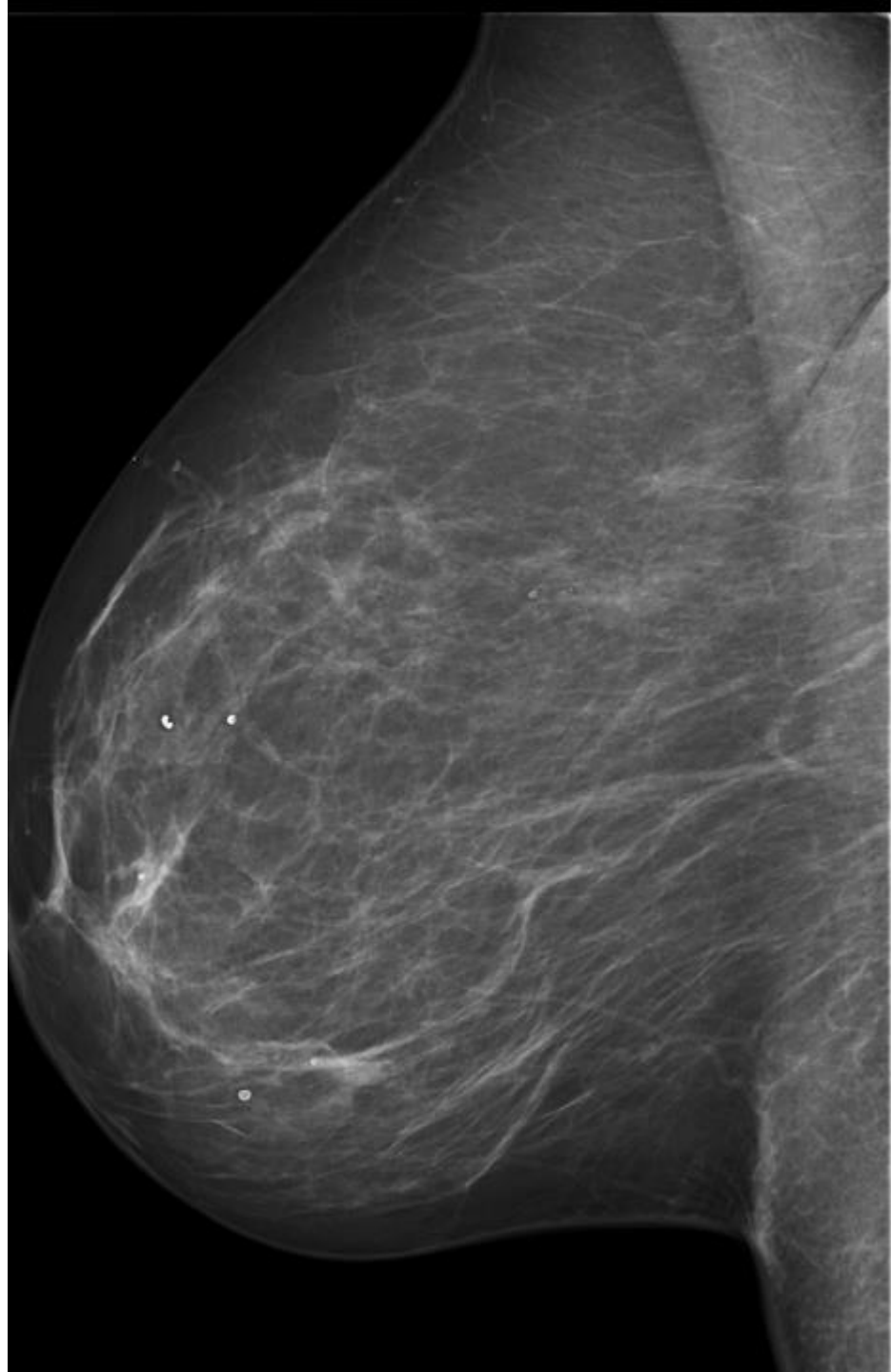
# Recall?

- Ja
- Nee



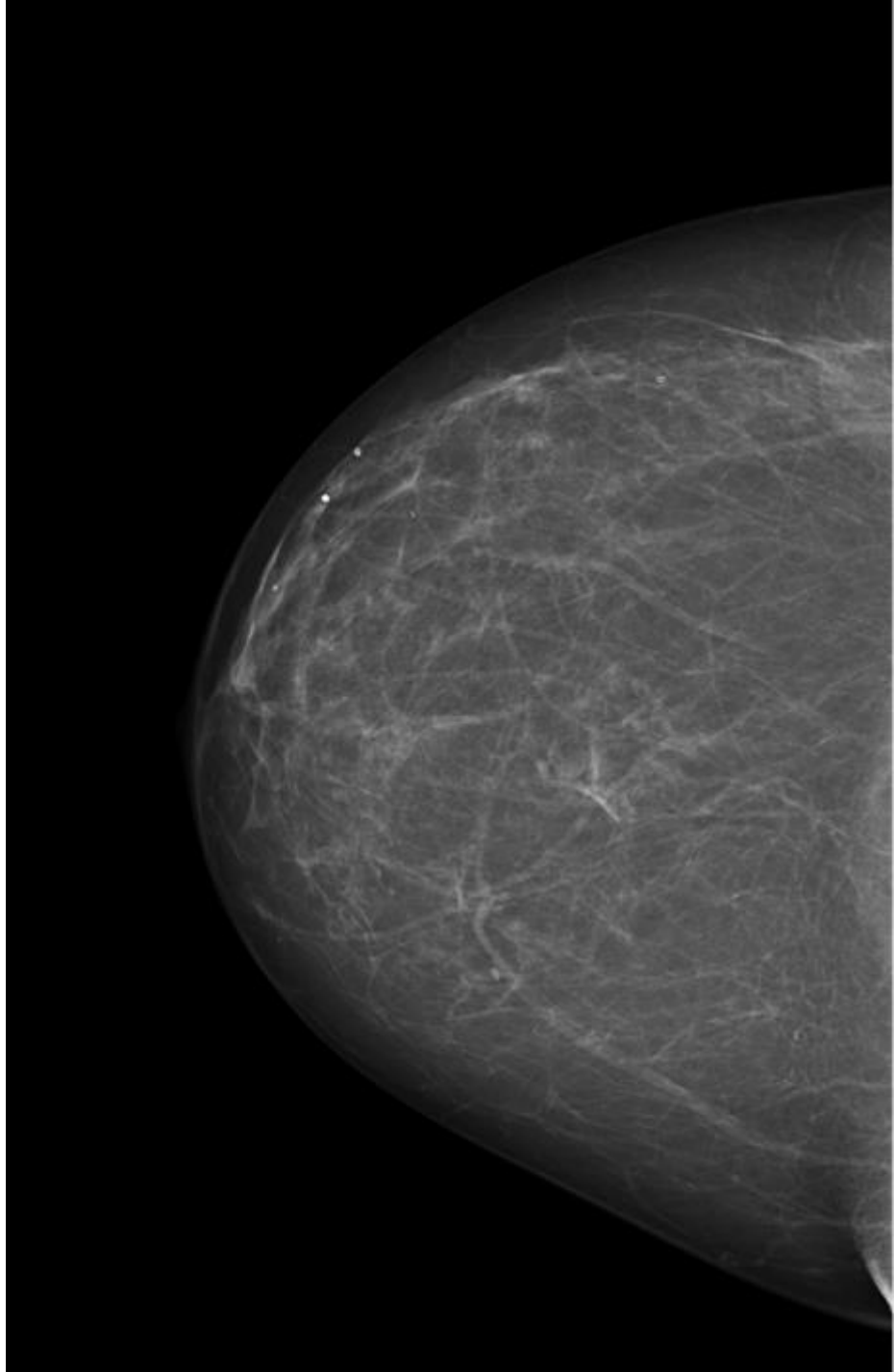


2009

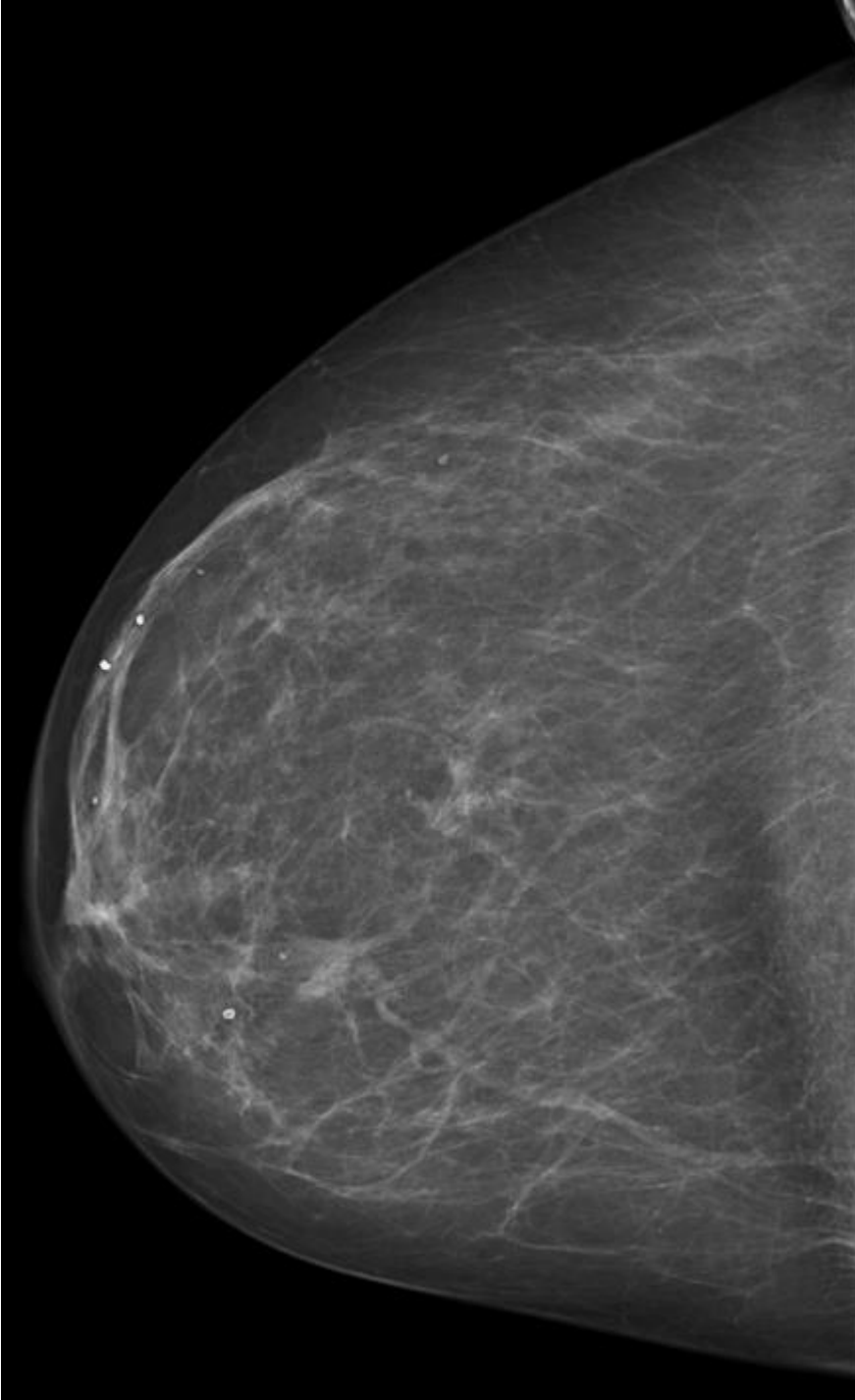


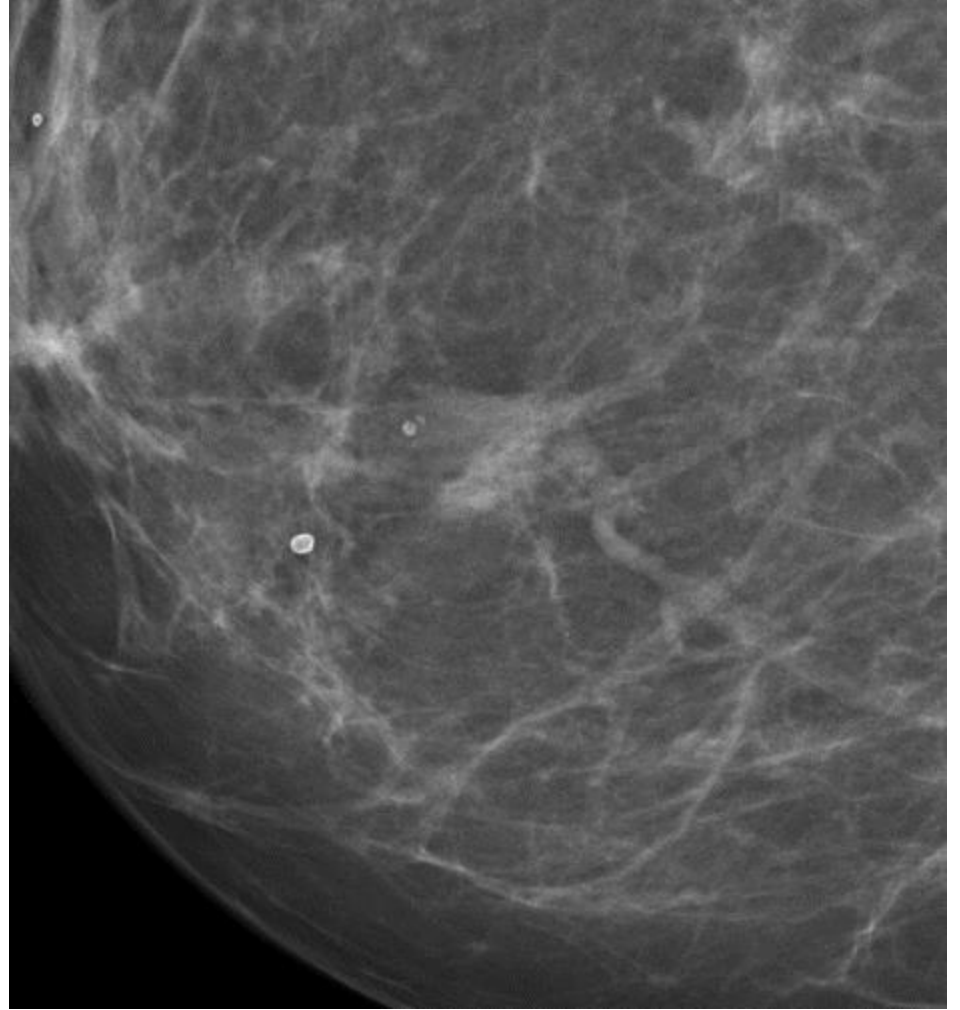
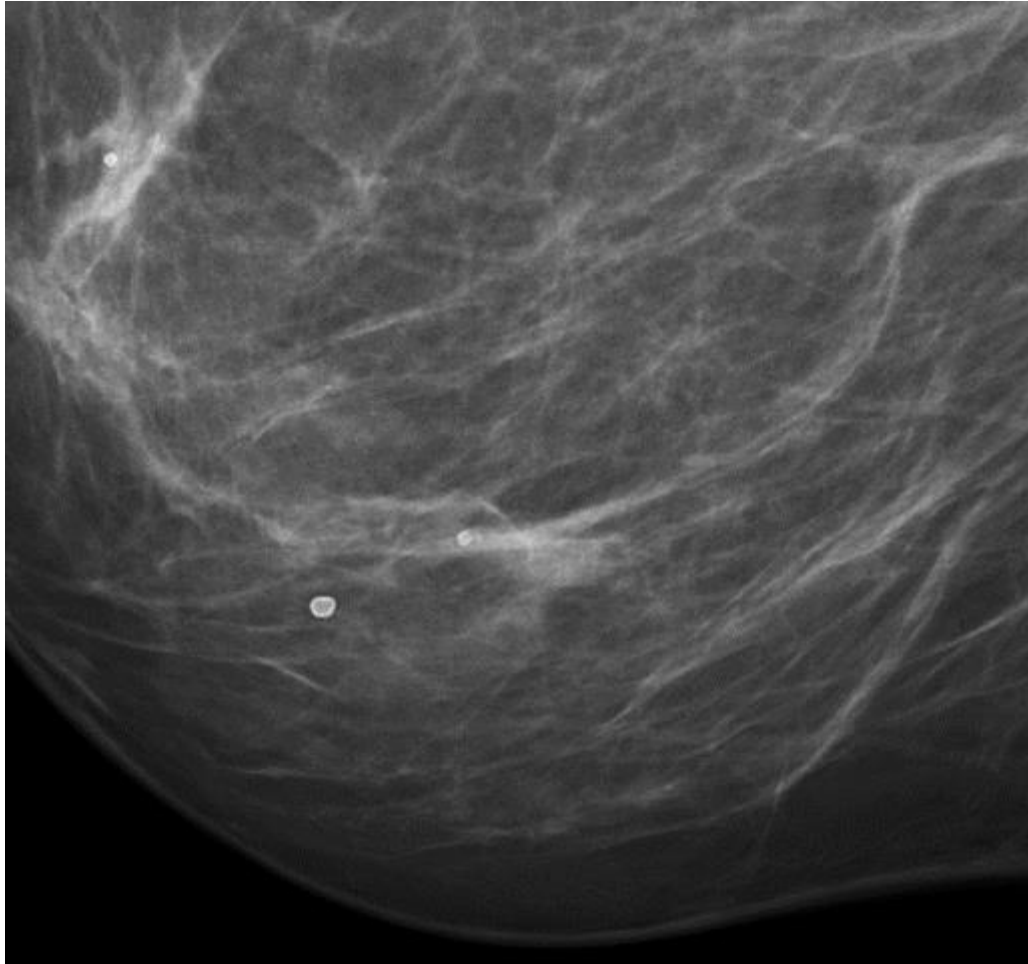
2015

2009



2015





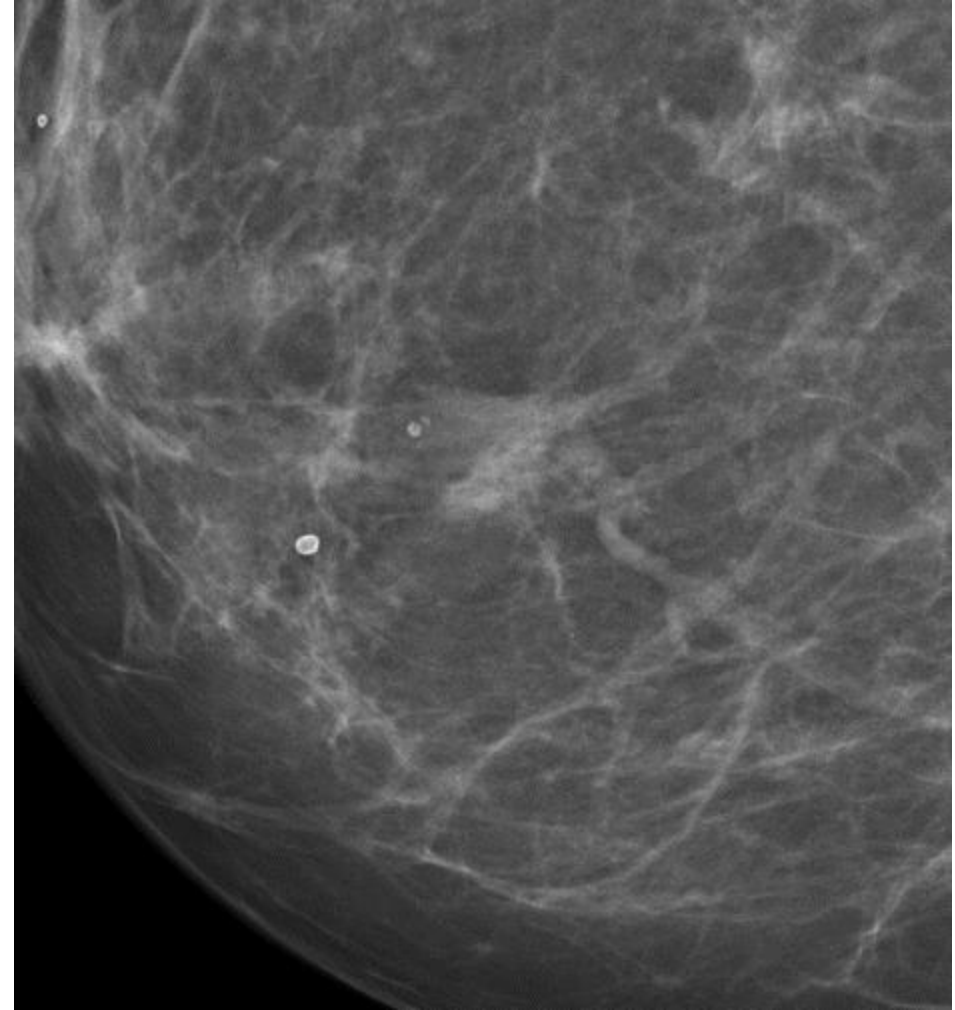
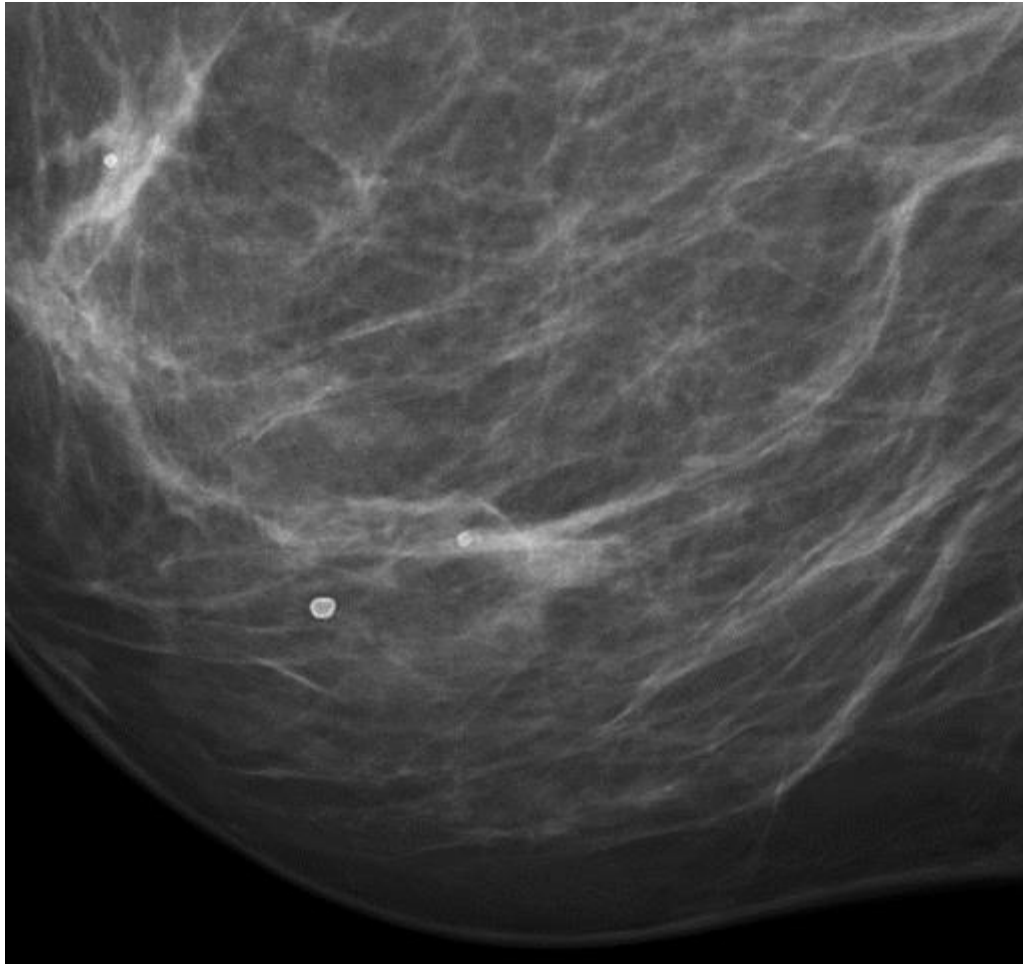


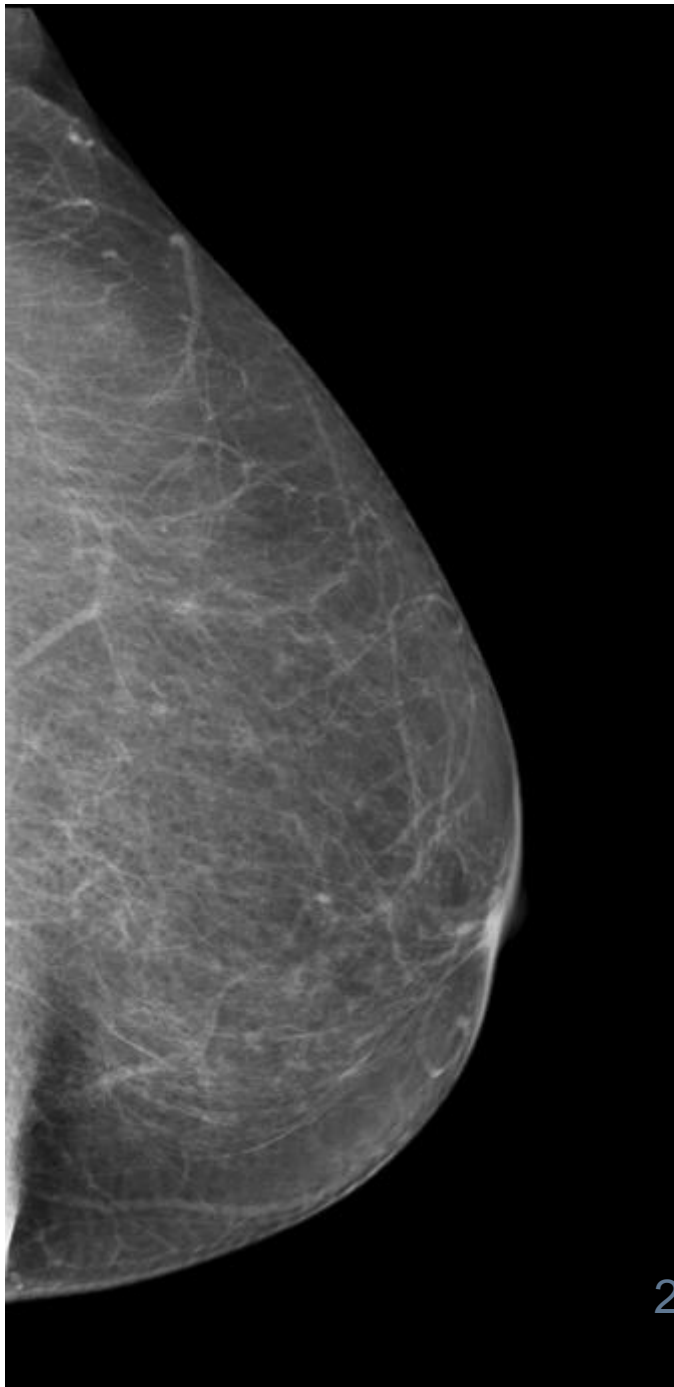
# Recall?

- Ja
- Nee

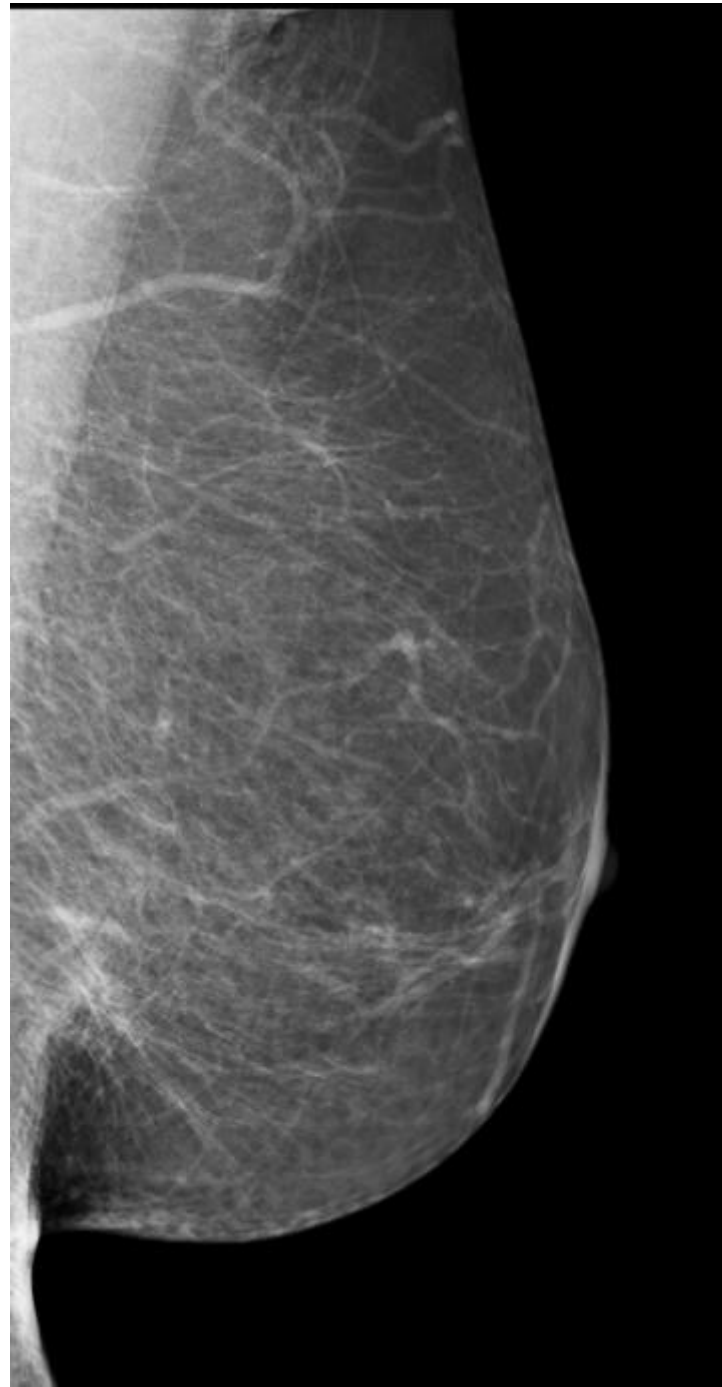


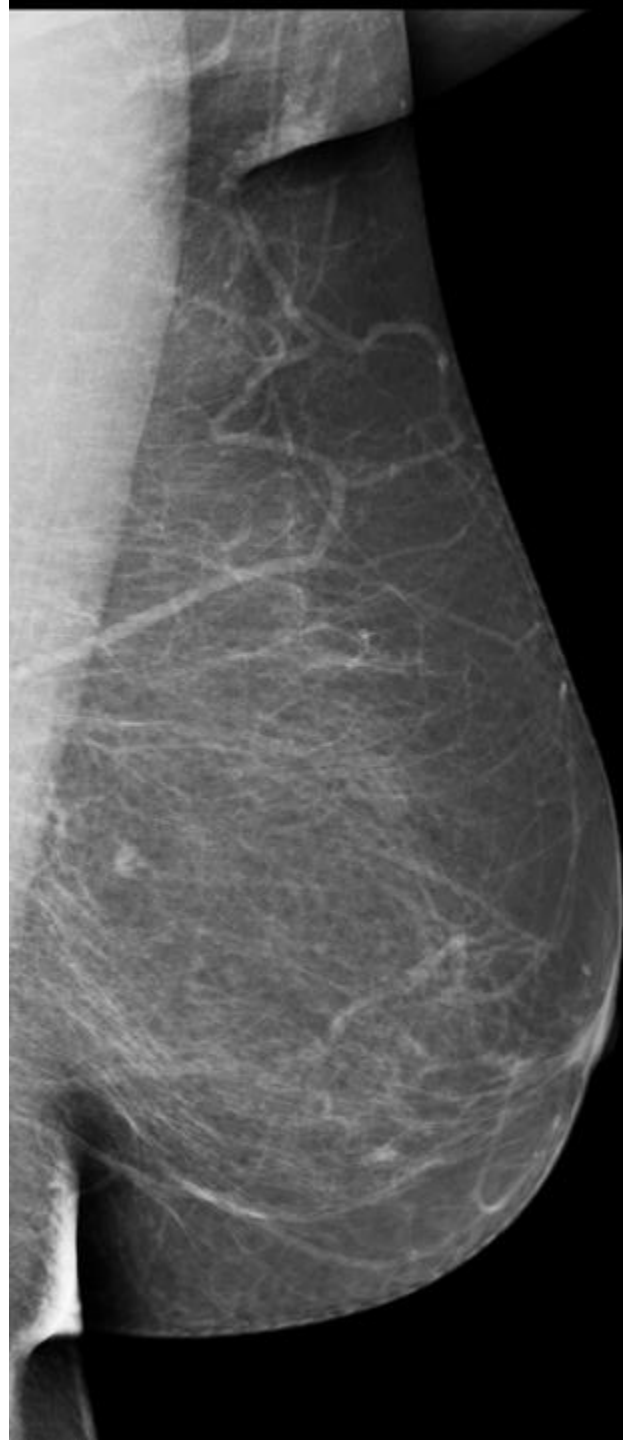
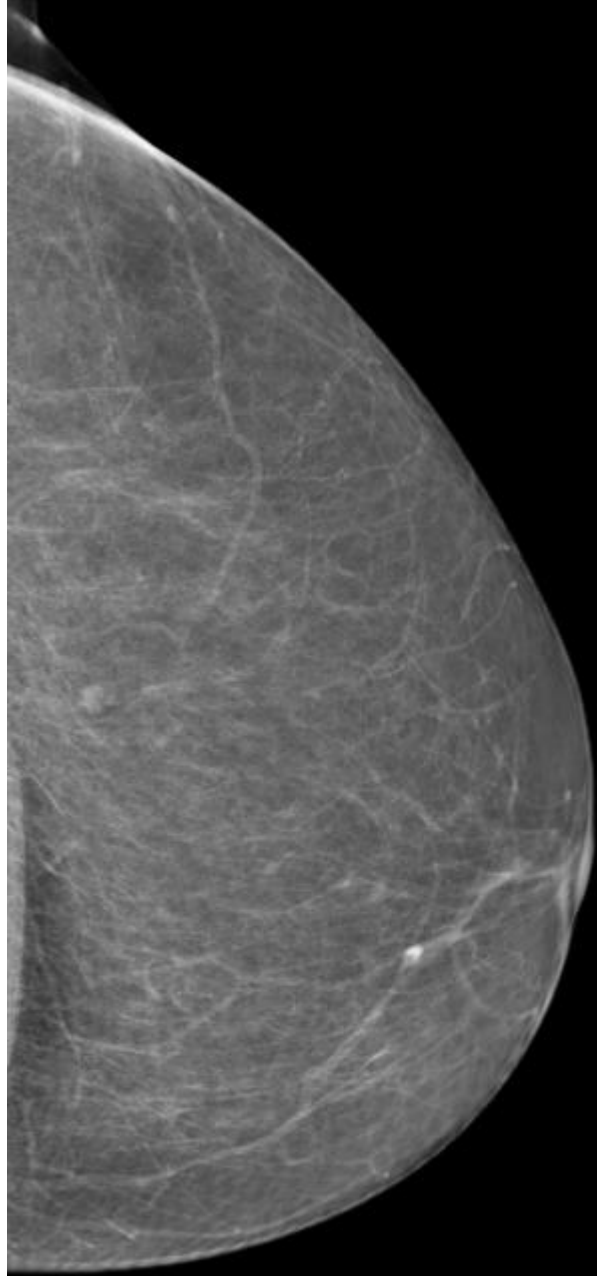
## Groepje cysten en ductectasie

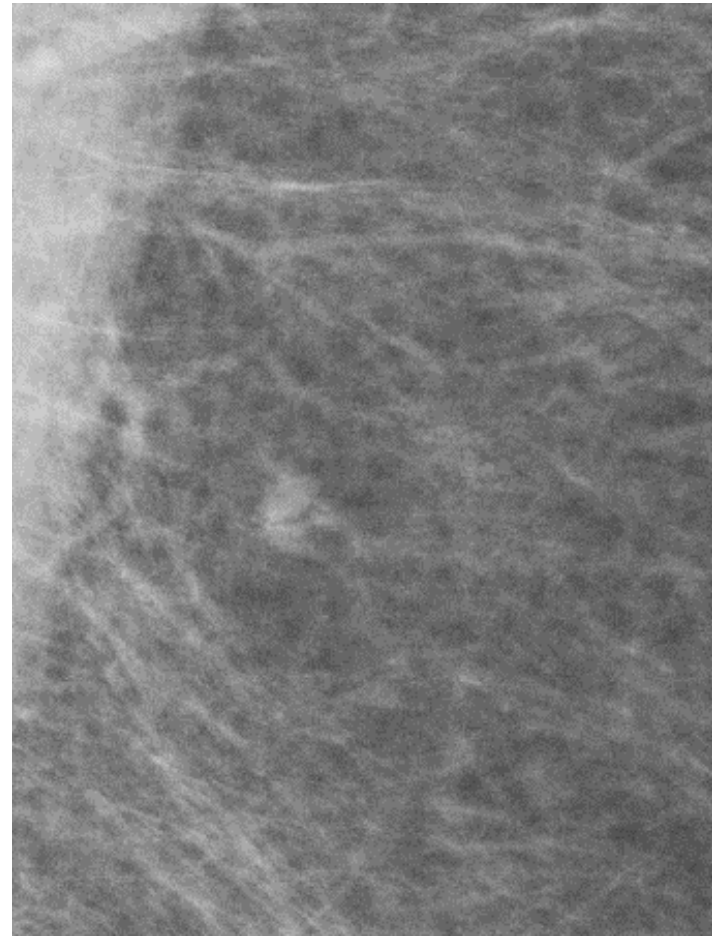
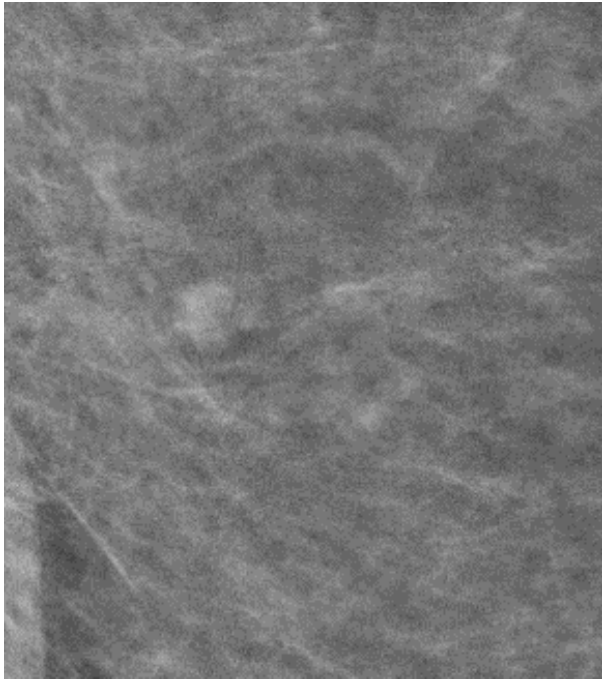




2009







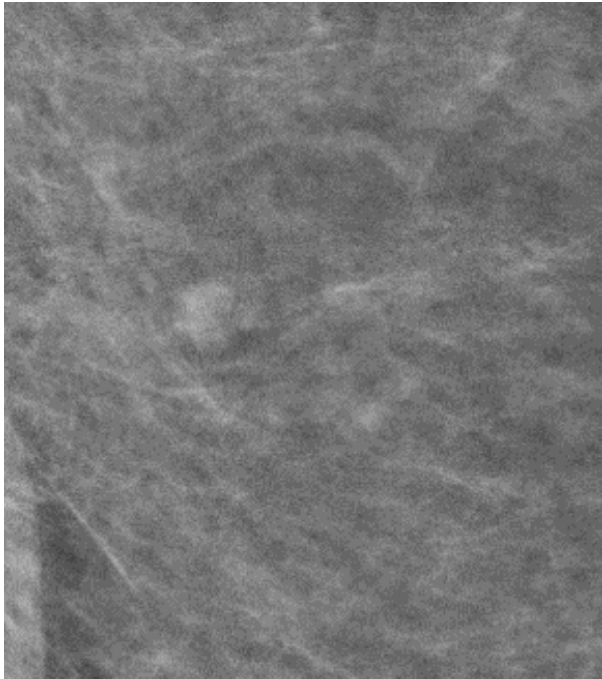
2011

# Recall?

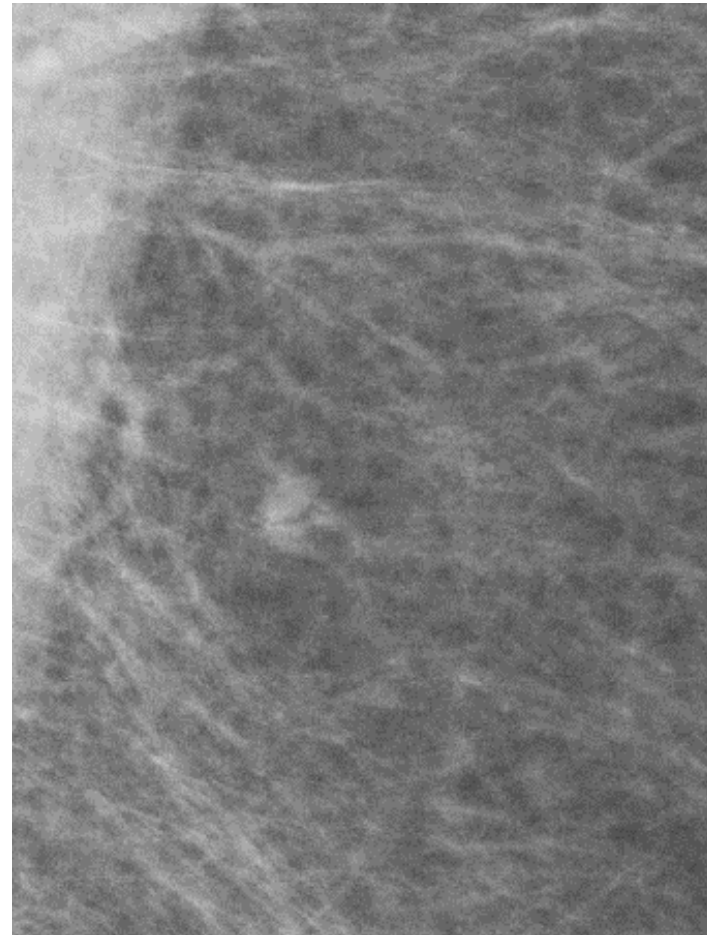
- Ja
- Nee

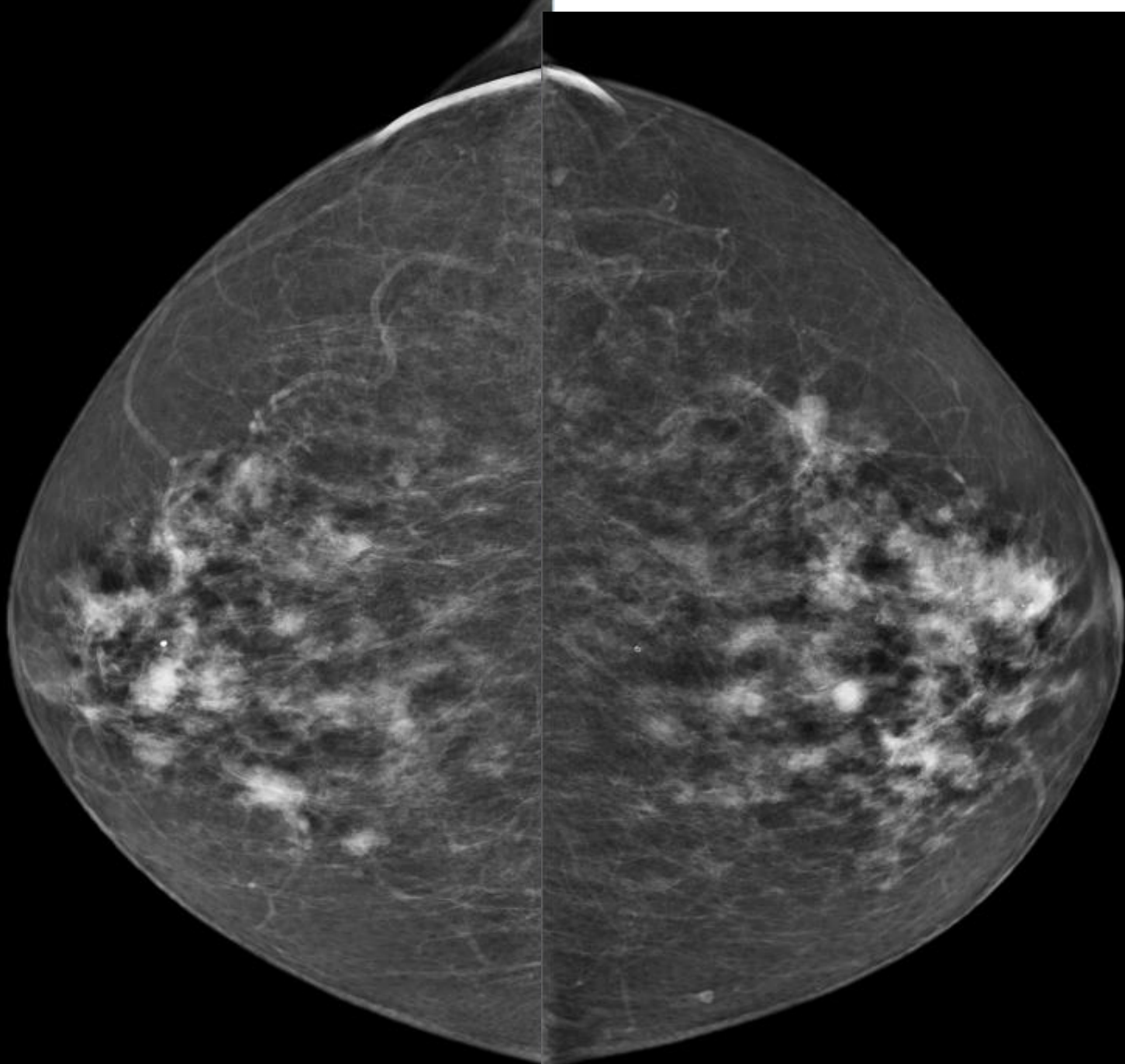




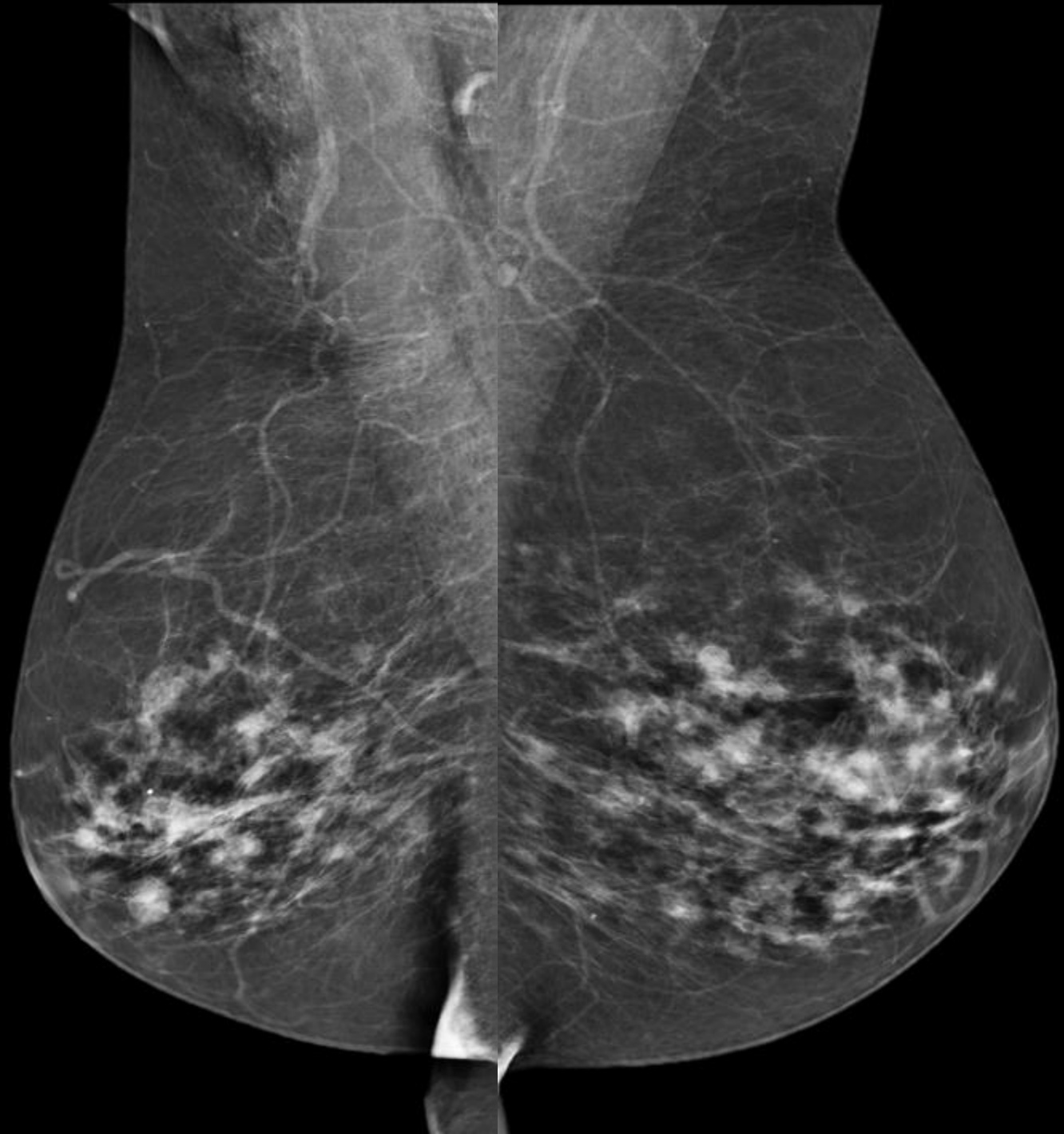

US benigne  
Controle MX na 14 maand status  
quo

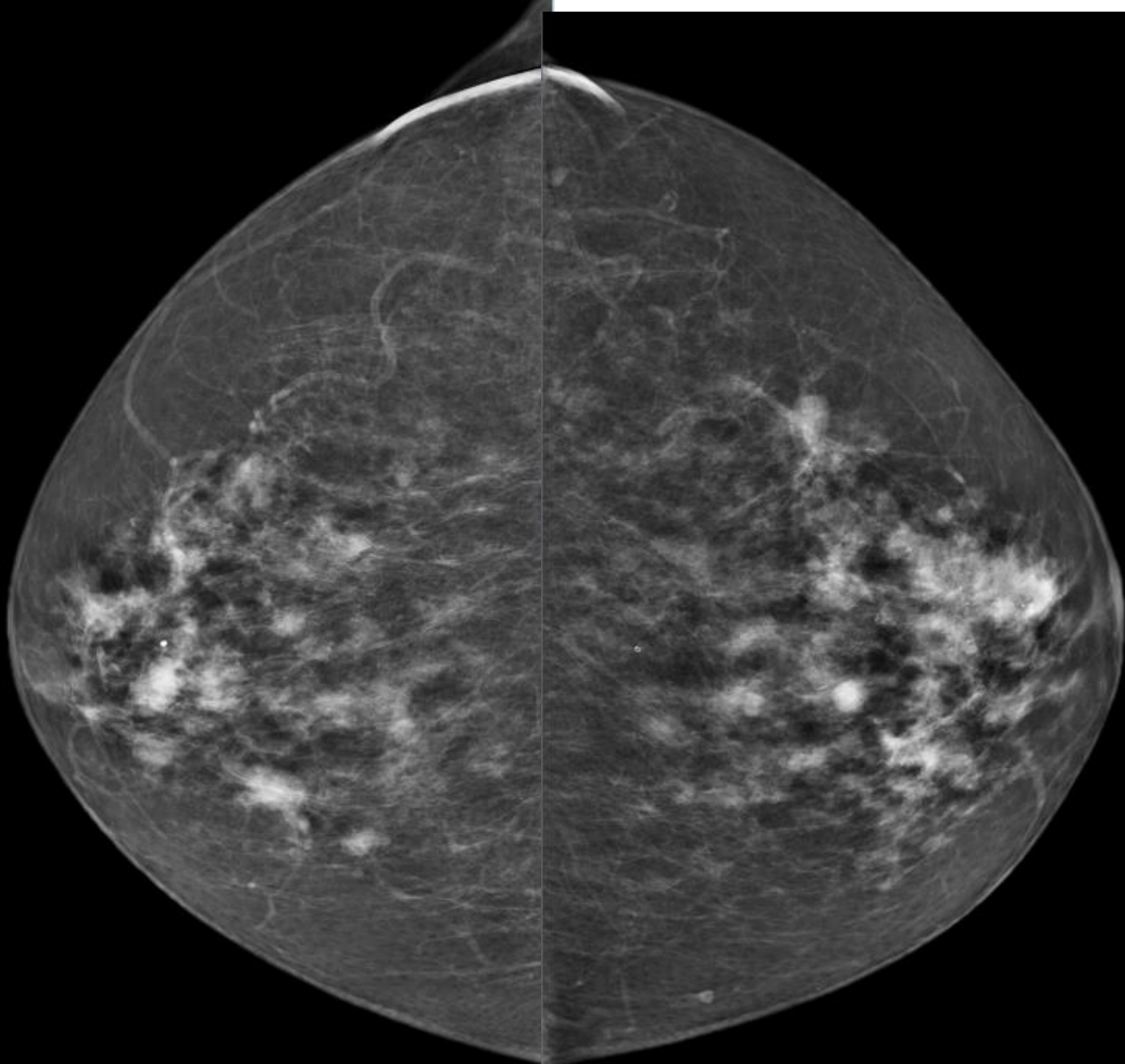




2018



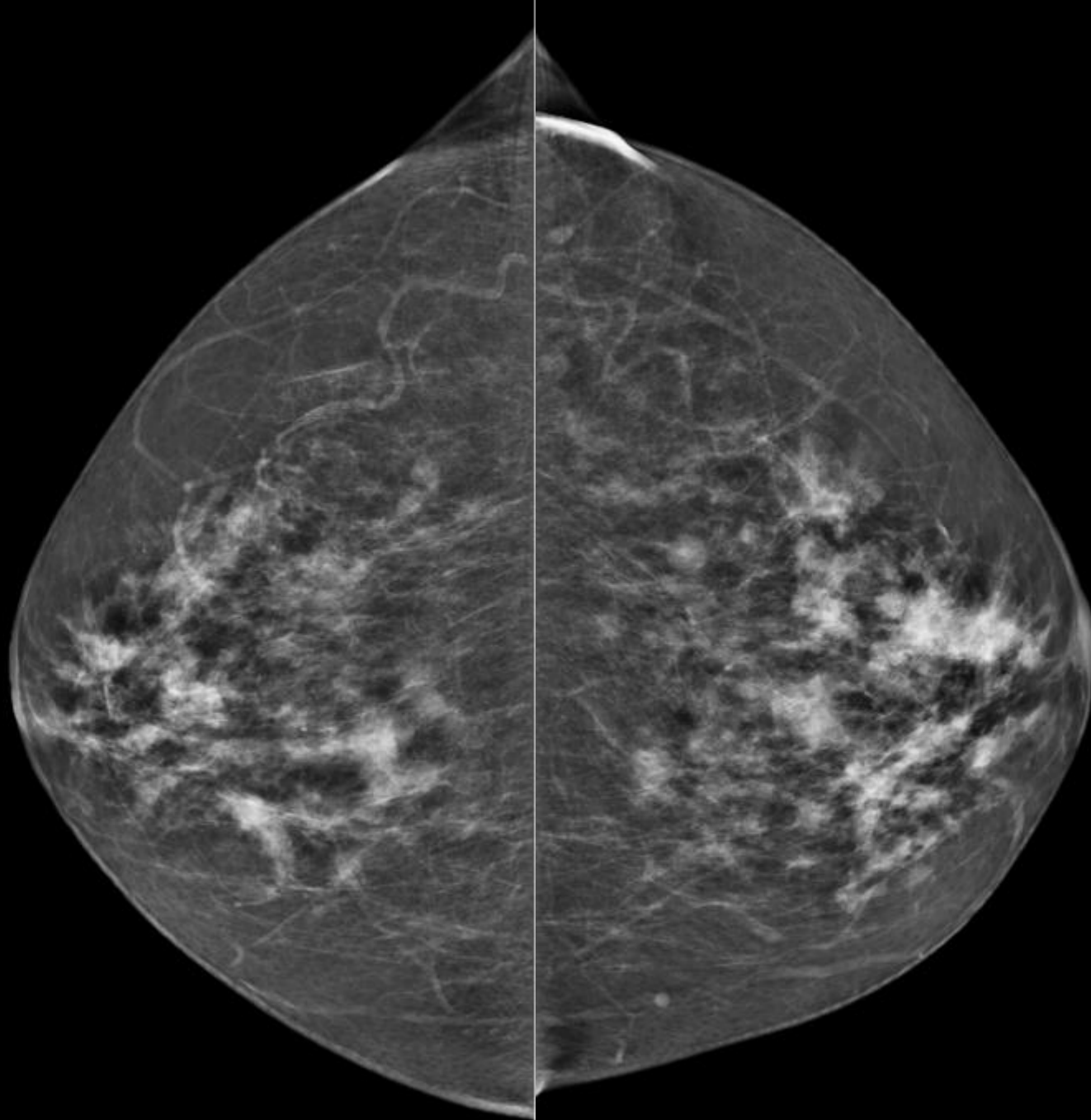
2018



2018



2016

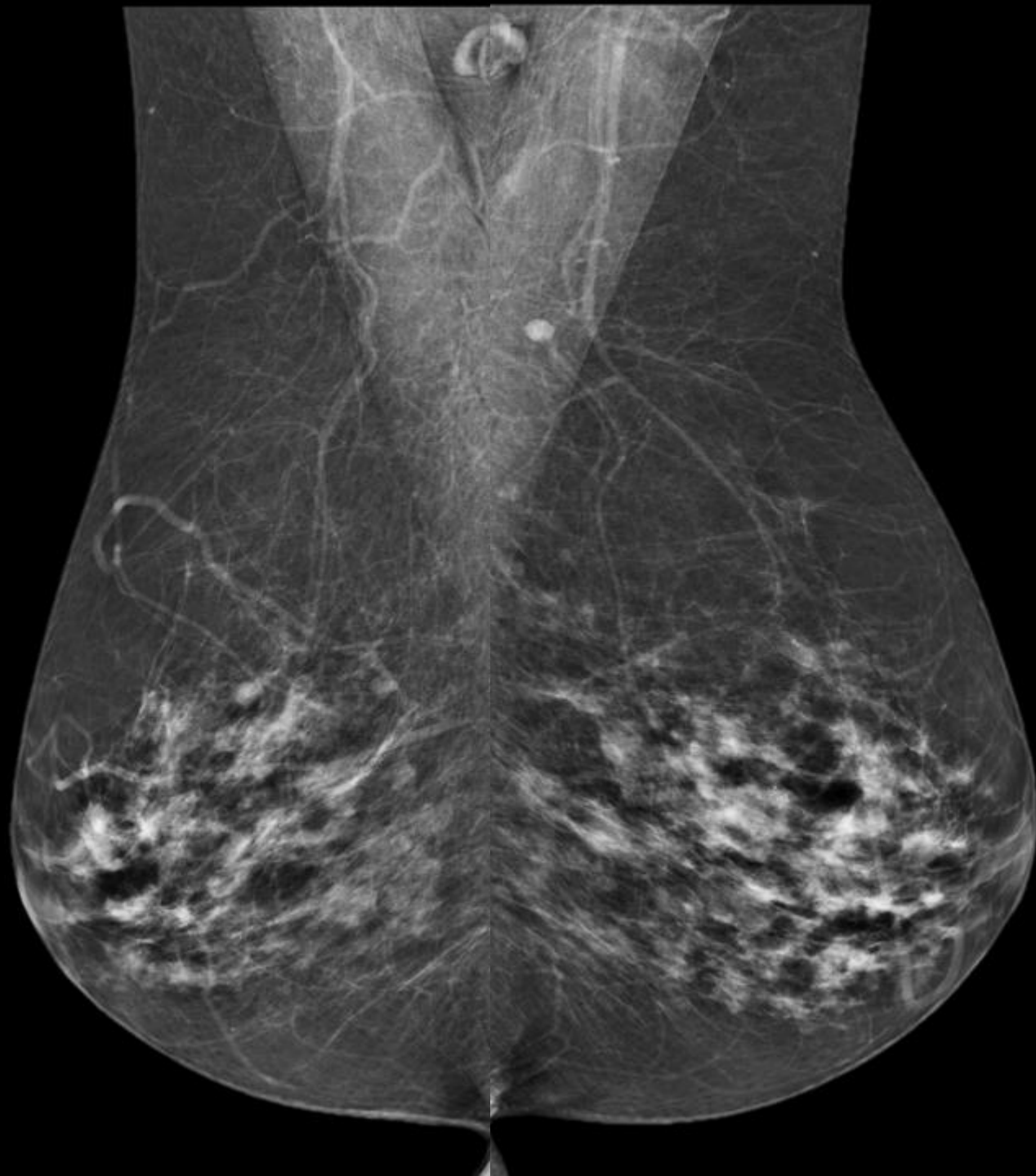



2018



2016



# Recall?

- Ja
- Nee



# Recall glad afgelijnde massa's

Als:

- Niet zeker (75%) goed aflijnbaar
- Nieuwe massa (1)
- Goed afgelijnd maar volumetoename
- Gelokaliseerd buiten het glandulaire weefsel

